



# Survival rate and clinical evaluation of the implants in implant assisted removable partial dentures: surveyed crown and overdenture

Soo-Hyun Kang<sup>1</sup>, Seong-Kyun Kim<sup>2\*</sup>, Seong-Joo Heo<sup>2</sup>, Jai-Young Koak<sup>2</sup>

<sup>1</sup>Department of Prosthodontics & Dental Research Institute, School of Dentistry, Seoul National University, Seoul, Republic of Korea

<sup>2</sup>Department of Prosthodontics & Dental Research Institute, Seoul National University Dental Hospital, School of Dentistry, Seoul National University, Seoul, Republic of Korea

**PURPOSE.** The purpose of this study was to investigate survival rates of the implants used in implant assisted removable partial dentures (IARPDs). **MATERIALS AND METHODS.** The study was conducted on 21 patients who were treated with IARPDs. The mean follow-up period for IARPD patients ranged from 12 to 185 months (mean 47.9 months). A total of 58 implants were used for IARPDs in two different modalities: 41 for surveyed crowns and 17 for overdentures. The survival of implants was determined by clinical and radiographic evaluations considering relevant factors: location, RPD classification, opposing dentition, splinting, and implant diameter. **RESULTS.** The survival rate of total 58 implants was 93.1%: 95.1% for implants supporting surveyed crowns and 88.2% for implants used in overdentures. Considering only the implants supporting surveyed crown, regular diameter implants showed a higher survival rate than narrow or wide diameter implants. **CONCLUSION.** The survival rate of the implants used in IARPDs was 93.1% (surveyed crown: 95.1%, overdenture: 88.2%). [*J Adv Prosthodont 2020;12:239-49*]

**KEYWORDS:** Dental implant; Implant assisted removable partial denture; Surveyed crown; Overdenture

## INTRODUCTION

In recent decades, prosthetic treatment using dental implants for fully or partially edentulous patients had made progressive improvement in various modalities.<sup>1</sup> Fully edentulous arches could be restored with fixed prostheses supported by 6 to 9 implants or with removable overdentures retained by attachments connected to 2 to 4 implants.<sup>2,3</sup> Currently, overdenture with 2 implants suggested by McGill consensus in

2002 is considered the standard treatment option for patients with complete edentulous mandible.<sup>4,5</sup>

For partial edentulous patients, implant-supported fixed prostheses or conventional removable partial dentures were regarded as common treatment options. However, clinicians often encounter situations in which it is difficult to choose either option, such as when a sufficient number of implants are not available to support fixed prostheses, or when poor retention and stability of the RPDs are expected due to poor residual ridges and compromised remaining teeth. In this regard, implant-assisted removable partial denture (IARPD) has been noted as an alternative treatment option, which allows additional support and retention with a few implants.<sup>6-14</sup> By inhibiting prostheses movements, implants provide RPDs with comfort, esthetics, improved phonetics, and improved masticatory function.<sup>11</sup>

IARPD has been replaced by a variety of terminologies in clinical reports depending on how it is retained and supported.<sup>14,15</sup> Implant-supported removable partial denture (ISRPD) was termed when implants provided only support, while implant-retained removable partial denture (IRRPD) was named when implants provided retention. Recently, the term IARPD is commonly used as a meaning encompassing both ISRPD and IRRPD.<sup>16</sup>

Corresponding author:  
Seong-Kyun Kim  
Department of Prosthodontics & Dental Research Institute, Seoul National University Dental Hospital, School of Dentistry, Seoul National University, 101, Daehak-ro, Jongno-gu, Seoul 03080, Republic of Korea  
Tel. +82220722661; e-mail, ksy0617@snu.ac.kr  
Received March 23, 2020 / Last Revision May 25, 2020 / Accepted June 1, 2020

© 2020 The Korean Academy of Prosthodontics  
This is an Open Access article distributed under the terms of the Creative Commons Attribution Non-Commercial License (<http://creativecommons.org/licenses/by-nc/4.0>) which permits unrestricted non-commercial use, distribution, and reproduction in any medium, provided the original work is properly cited.

This research was supported by Basic Science Research Program through the National Research Foundation of Korea (NRF) funded by the Ministry of Education (NRF-2018R1D1A1B07042333) and by a grant (no. 04-2018-0094) from the SNUDH Research Fund.

There are two modalities for restorations with IARPDs. The first modality is to use surveyed crowns supported by implants.<sup>17</sup> The second modality is the overdenture which the implants and abutments placed below the RPD base. Both modalities allow additional support and retention compared to unfavorable conventional removable partial dentures. These allow the patients to feel more comfortable while chewing or pronouncing.<sup>11,18,19</sup> Depending on the circumstances, removal of clasps can also provide advancements in aesthetics.<sup>20,21</sup>

Several studies on IARPD have been presented, but most of them cover only overdentures. Clinical researches on IARPD with surveyed crown supported by implants have not been performed much compared to overdenture.<sup>22</sup> Clinical studies on IARPD with various follow-up periods have been presented: Grossmann *et al.*<sup>11</sup> for average of 35 months, Mijiritsky<sup>13</sup> for 2 to 7 years, Mitrani *et al.*<sup>18</sup> for maximum 4 years, Bortolini *et al.*<sup>19</sup> for maximum 8 years, Ohkubo *et al.*<sup>14</sup> for under 3 weeks, Payne *et al.*<sup>23</sup> for a year, and Kaufmann *et al.*<sup>8</sup> for maximum 8 years. These previous studies reported the survival rate of the implants used only for overdentures, and also did not perform analysis according to implant factors or related conditions. Surveyed implant crown also has not been studied so far, and only a few case reports and short-term results were introduced.<sup>24-28</sup> These previous studies did not provide clinical guidelines. Recently, Bae *et al.*<sup>29</sup> reported clinical analyses (survival rate, marginal bone resorption, and periodontal indices) between implant surveyed bridge and stud type attachment.

The aim of this present study was to investigate the survival rate and marginal bone loss around the implants used in IARPDs, and also to examine the effects of various factors such as treatment modality, implant location, Kennedy classification, opposing dentition, conjunction of implants, and implants' diameter. All biological and technical complications occurred during the entire observation period were examined and analyzed.

## MATERIALS AND METHODS

This study was approved by the Institutional Review Board Seoul National University Dental Hospital (CRI16005). This retrospective study was conducted on the patients who received IARPD from 2000 to 2015 at Seoul National University Dental Hospital in South Korea. All patients included in this study were treated by surgical or prosthodontic specialists and visited for periodical recall checks. Patients with systemic diseases affecting implant prognosis were excluded from the study.

A total of 22 IARPDs in 21 patients (9 males and 12 females) were evaluated clinically and radiographically (one patient was treated with 2 IARPDs in both the maxilla and mandible) (Table 1).

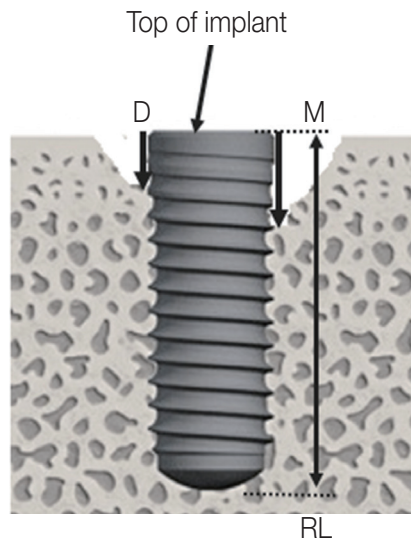
Of the total 22 IARPDs, 12 were assisted by implant-supported surveyed crowns (Upper: 8, Lower: 4) and 10 were overdentures (Upper: 3, Lower: 7). 41 implants for surveyed crowns and 17 implants for overdentures were observed. The mean follow-up period for IARPD patients ranged from 12 to 185 months (mean 47.9 months). Clinical and radiographical assessments were performed on a total of 58 implants. Information such as treatment modality, location, the Kennedy classification, implant connection type, implant diameter, and opposing dentition type were recorded.

The implant survival criteria were following the Pisa consensus statement of the ICOI Conference 2007.<sup>30</sup> The implant was considered survival if the implant and its superstructure remained functioning normally at the point of the final observation. The implant was defined as a failure if any of the following conditions were present:

- a) Pain on palpation, percussion or function
- b) Horizontal and/or vertical mobility
- c) Uncontrolled progressive bone loss
- d) Uncontrolled exudate
- e) Radiographic bone loss > 1/2 length of implant
- f) No longer in mouth

**Table 1.** Number of the IARPDs, and related implant informations

Modalities	Surveyed crown	Overdenture	Total
IARPDs	12 (Upper: 8, Lower: 4)	10 (Upper: 3, Lower: 7)	22
Implants	41 (Maxilla: 22, Mandible: 19)	17 (Maxilla: 6, Mandible: 11)	58
Implant connection type (External or Internal)	External: 26 Internal: 15	External: 14 Internal: 3	58
Implant manufacturer	Osstem: 18 3i: 9 Brånemark: 4 Straumann: 3 Dentium: 2 Ankylos: 1	Brånemark: 10 Osstem: 3 Straumann: 1 Dentium: 1 Shinhung: 1 Etc: 1	58



M: Measure distance from top to marginal bone contact level on radiograph (mesial)

D: Measure distance from top to marginal bone contact level on radiograph (distal)

$$\text{Average bone level (ABL)} = \frac{M + D}{2} \times \frac{AL}{RL}$$

AL: Actual length of place implant

RL: Length of implants on radiograph

Bone loss = [ABL at final visit] - [ABL at IARPD delivery]

**Fig. 1.** The definition of 'marginal bone loss around implant'.

Digitized panoramic and periapical radiographs were taken for all patients after the delivery of IARPD and at the time of recall visits. The amount of bone resorption was measured as the difference in bone level between two radiographs (at the time of delivery of IARPD and the final recall visit). The bone level was determined as the distance between the top of the implant and the level of the adjacent osseous crest, on the mesial and distal aspect respectively. Based on the actual length of the implants, the actual bone level was calculated by the proportional equation.<sup>31</sup> The average value of bone resorption in the mesial and distal aspects was defined as marginal bone loss (Fig. 1).

Data of biological and technical complications were collected from the clinical chart of all patients included. All records on the chart were reviewed to identify complications associated with IARPDs. Complications were classified into 5 categories:

- Denture: fractures or deformations of the RPD components followed by repair of the denture or fabrication of new denture.
- Implant: screw loosening or fractures.
- Crown: veneer porcelain fracture, dislodgement of prostheses.
- Tissue: sore spots, peri-implantitis, bleeding on probe, marginal bone resorption, caries crown fracture, loss of tooth, need of restoration,
- Others: opposing tooth fracture or mobility, occlusal adjustment, discomfort.

The following factors possibly associated with the prognosis of the implants in IARPDs, were recorded from 58 implants:

- Treatment modality (surveyed crown vs. overdenture)
- Restored arch (maxilla vs. mandible)
- Implant location (anterior vs. posterior)
- Kennedy classification (I - IV)

- Implant connection type (internal vs. external)
- Diameter: narrow (< 3.75 mm) vs. regular ( $\geq 3.75$  mm, < 5.0 mm) vs. wide ( $\geq 5.0$  mm)

All data were entered into the database system and evaluated using the statistical package SPSS version 23 (SPSS Inc., Chicago, IL, USA). Kaplan & Meier method was used for implant survival analysis with log rank (Mantel-Cox) test to compare variables. The time interval criterion for implant failure was defined as the time difference between each delivery date of IARPD and the occurrence date or the end date of observation.

## RESULTS

During the observation period, 4 implants failed. Table 2 depicted the information of the 4 failed implants. The total survival rate of implants was 93.1%. Table 3 showed survival rates by factors. In comparison of survival rates according to treatment modalities, 2 surveyed crown implants and 2 implants in overdenture failed, resulting in survival rates of 95.1% and 88.2%, respectively. The difference in survival rate according to treatment modalities was not significant.

As shown in Table 2, the 2 failed implants (A and B) at the lower left second molar (#37) previously supported fixed prostheses but were no longer available for fixed prostheses after other teeth or implants were removed. They were then used as abutments for IARPDs and assisted the embrasure clasps to retain. Implant A had been placed at the augmented site with iliac bone graft and removed 37 months after IARPD delivery. Considering the period of supporting fixed prosthesis, it functioned for a total of 171 months. Implant B functioned for 22 months after IARPD delivery and for a total of 80 months, including 58 months supporting fixed prosthesis. Considering the period of sup-

**Table 2.** The information of four failed implants

Condition	Failed implants			
	A	B	C	D
Patients age/Gender	45/Female	91/Male	54/Female	60/Female
Treatment modality	Surveyed crown		Overdenture	
RPD retention type	Embrasure clasp	Embrasure clasp	Hader bar	Hader bar
Location of implant placed	#37	#37	#14	#22
Diameter/length of implant (mm)	3.3/18	6.0/11.5	4.0/11.5	4.0/11.5
Connection type	External	External	External	External
Survival periods (months)	134	22	17	85
Opposing dentition	Natural tooth	Implant FPD	Natural tooth	Natural tooth
Reason of failure	Pain, exudate	Bone loss, exudate	Pain, exudate	Bone loss, exudate

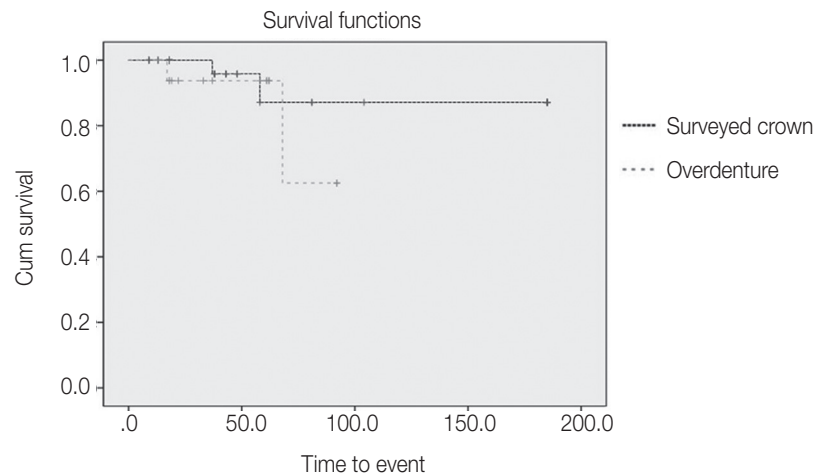
**Table 3.** Implants survival rates in the IARPDs

Condition		No. of implants	Failed implants	Survival rate (%)	P value
Treatment modalities	Surveyed crown	41	2	95.1	.415
	Overdenture	17	2	88.2	
Restored arch	Maxilla	28	2	92.9	.761
	Mandible	30	2	93.3	
Kennedy classification	I	21	2	90.5	.184
	II	19	1	94.7	
	III	8	1	87.5	
	IV	10	0	100	
Type of opposing teeth	Natural teeth + FPD	44	4	90.9	.402
	RPD + CD	14	0	100	

porting fixed prostheses, it could be considered that both implants have sufficient functional periods before removed. When estimating the cause of failures in relation to the location, mandibular second molar, it could be focused on the fact that this is the least accessible area for oral hygiene. Implant C and D were placed in a same patient for overdenture. With a remaining natural tooth in her maxilla, a Hader bar, supported by 4 implants placed in anterior region, was fabricated to support overdenture. Implants C and D were removed after 17 and 85 months respectively. The opposing dentitions were natural teeth. One of the artificial resin teeth of IARPD was fractured twice before implant failure. Wear of the Hader clip was also observed twice, which may have been due to parafunctional activity or imbalanced occlusion. After the 2 implants were removed, the patient has been using the IARPD supported by healing abutments connected to the remaining 2 implants without any problem (follow-up period of 92 months).

Kaplan-Meier survival curve according to the treatment modality is illustrated in Fig. 2. Two implants failed in maxilla and mandible each, resulting in survival rates of 92.9% and 93.3% respectively. There was no significant difference of the survival rates between maxilla and mandible. The survival rates according to the implant-corrected Kennedy classifications were 90.5%, 94.7%, 87.5%, and 100% in Classes I, II, III and IV, respectively. There was no significant difference according to the Kennedy classifications. There were 44 implant abutments with opposing natural teeth or fixed prostheses, of which 4 implants failed resulting in 90.9% survival rate. When the opposing dentition was RPD or complete denture (CD), there was no implant failure among the 14 implants, which resulted in a 100% survival rate. There was no significant difference according to the opposing dentition.

The survival analysis results of the 41 surveyed implant crowns were shown in Table 4. One narrow (< 3.75 mm)



**Fig. 2.** Kaplan-Meier survival curves depending on treatment modality.

**Table 4.** The implant survival rates of the surveyed crown

	Condition	No. of implants	Failed implants	Survival rate (%)	<i>P</i> value
Implant diameter	Narrow	9	1	88.9	.027
	Regular	24	0	100	
	Wide	8	1	87.5	
Location of implant placed	Anterior	13	0	100	.058
	Posterior	28	2	92.9	
Restored arch	Maxilla	22	0	100	.761
	Mandible	19	2	89.5	
Splinting	Splinting	38	2	94.7	.576
	Non-splinting	3	0	100	
Kennedy classification	I	10	0	100	.057
	II	18	1	94.4	
	III	3	1	66.7	
	IV	10	0	100	
Implant connection type	Internal	15	0	100	.451
	External	26	2	92.3	

and one wide ( $\geq 5.0$  mm) implants failed, and there was no failed regular implant ( $\geq 3.75$  mm,  $< 5.0$  mm). The survival rates of narrow, regular, and wide implants were 88.9%, 100%, and 87.5%, respectively. Significant differences ( $P = .027$ ) in survival rates were observed, with the survival rate of regular implants higher than that of narrow or wide implants. The survival rates of the implant located in anterior and posterior region were 100% and 92.9%, respectively. The survival rates of the maxillary and mandibular implants were 100% and 89.5%, respectively. There was no significant difference in the survival rate according to the implant loca-

tion. 38 implants supported splinted prostheses, two of which were failed (survival rate 94.7%). There was no failed implant in non-splinted group (survival rate 100%). No significant difference of survival rates was found. According to the Kennedy classifications, the survival rates were 100%, 94.4%, 66.7%, 100% for each classes I, II, III, and IV, respectively. No significant difference of survival rates was with or without splinting. The survival rate of internal connection type implants was 100%, and the survival rate of external connection type implants was 92.3%. No significant difference was observed between them.

Table 5 showed the survival analysis for overdenture implants. Of the total 17 overdenture implants, two implants failed in the same patient with no particular disease. The survival rates of narrow, regular, and wide implants were 100%, 84.6%, 100%, respectively. No significant difference of survival rates was found. The survival rates of the implants located in anterior and posterior region were 66.7% and 100%, respectively. The survival rates of the maxillary and mandibular implants were also 66.7% and 100%, respectively. No significant difference was observed according to the location. The survival rate of internal connection type implants was 100%, and it was 85.7% in external connection type implants. No significant difference was found between them.

Table 6 shows the analysis of marginal bone loss around the implants, excluding 4 failed implants. The mean marginal bone loss was  $1.3 \pm 1.6$  mm. The distribution of marginal bone loss around implants is shown in the Fig. 3. Seventy percent of the total implants showed marginal bone loss less than 1.5 mm. The marginal bone loss was higher in

Kennedy class I than in Kennedy class III.

Table 7 shows the complications in IARPDs using surveyed crown. The most common complication was dislodgement of surveyed implant crown due to washout of temporary cement. In case of overdenture, wear of attachment was the most frequent complication. Their incidences and remarks are shown in Table 8. All complications were resolved by repairing or changing the components.

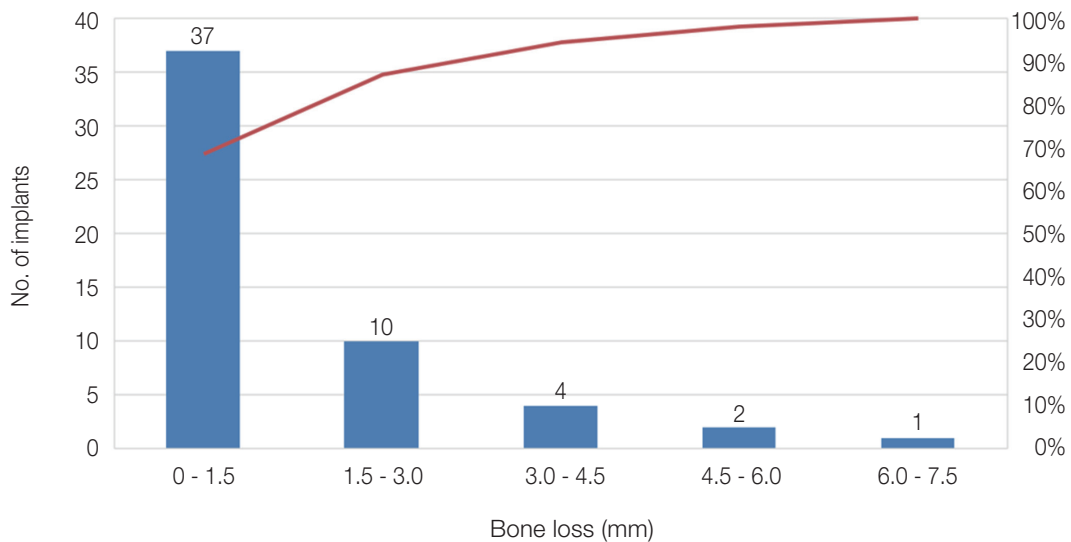
The complications in the both treatment modalities were divided into five categories (Table 9). The incidence of complications in overdenture IARPDs were 1.8-folds higher than that of surveyed crown IARPDs. In surveyed crown IARPDs, 31.2% of the complications were related to crowns. In overdenture IARPDs, 45.8% were related to tissue, and 37.5% to denture. Mechanical complications related to implant were not observed in overdenture IARPDs, while the problems related to remaining natural teeth or abutments occurred more frequently in overdenture IARPDs.

**Table 5.** The implant survival rates of the overdenture

Condition		No. of implants	Failed implants	Survival rate (%)	P value
Implant diameter	Narrow	2	0	100	.846
	Regular	13	2	84.6	
	Wide	2	0	100	
Location of implant placed	Anterior	6	2	66.7	.197
	Posterior	11	0	100	
Restored arch	Maxilla	6	2	66.7	.138
	Mandible	11	0	100	
Implant connection type	Internal	3	0	100	.705
	External	14	2	85.7	

**Table 6.** Results of the marginal bone loss around implants

Condition		No. of implants	Bone loss(mm)	P value
Treatment modalities	Surveyed crown	39	1.2	.79
	Overdenture	15	1.4	
Restored arch	Maxilla	26	1.4	.584
	Mandible	28	1.2	
Kennedy class	I	19	1.5	.015
	II	18	1.2	
	III	7	0.2	
	IV	9	1.8	
Type of opposing teeth	Natural teeth + FPD	40	1.2	.22
	RPD + CD	14	1.6	



**Fig. 3.** The distribution of marginal bone loss around implants.

**Table 7.** Complications in IARPDs using surveyed crown

Complication	Incidences/patients	Remarks
Dislodgement of surveyed implant crown	4/2	Temporary cement loss
Loss of osseointegration	2/2	Implant removal
Opposing tooth loss	2/1	One natural tooth fracture One implant removal
Fracture of screw	2/1	External, single implant, wrought wire clasp retained
Screw loosening	1/1	Anterior region
Clasp loosening	1/1	Embrasure clasp
Porcelain veneer fracture	1/1	Anterior region
Marginal bone resorption	1/1	2 thread exposed
Fracture of RPD artificial tooth	1/1	Anterior region
Fracture of RPD rest	1/1	Akers clasp

**Table 8.** Complications in overdenture IARPDs

Complication	Incidences/patients	Remarks
Need of changing attachment	6/4	Attachment change and/or denture relining
Loss of natural tooth abutment of IARPD	3/3	Crown fracture and extraction, RPD repair
Natural tooth loss	2/2	Fistula, abscess
Natural tooth needs restoration	3/3	Caries, chipping
Fracture of IARPD component	2/2	Re-fabrication
Clasp loosening	1/1	Clasp tightening
Marginal bone resorption	1/1	Relining
Loss of osseointegration	2/1	Maxilla, anterior region, bar-type attachment
Loss of opposing tooth	2/2	Extraction, denture repair
Fracture of opposing denture	2/2	Repair, re-fab

**Table 9.** Comparison of complications in IARPDs

	Surveyed crown (12 IARPDs)			Overdenture (10 IARPDs)		
	Complications	Incidences	Sum (Proportion)	Complications	Incidences	Sum (Proportion)
Denture	Clasp loosening	1	3 (18.8%)	Clasp loosening	1	9 (37.5%)
	Fracture of RPD artificial tooth	1		Need of changing attachments	6	
	Fracture of RPD rest	1		Fracture of RPD framework	2	
Implant	Fracture of screw	2	3 (18.8%)			0 (0%)
	Screw loosening	1				
Crown	Dislodgement of surveyed crown	4	5 (31.2%)			0 (0%)
	Porcelain veneer fracture	1				
Tissue	Loss of osseointegration	2	3 (18.8%)	Loss of osseointegration	2	11 (45.8%)
	Marginal bone resorption	1		Marginal bone resorption	1	
				Loss of natural tooth abutment of IARPD	3	
				Loss of natural tooth	2	
				Need of restoration on tooth	3	
Others	Loss of opposing tooth	2	2 (12.4%)	Loss of opposing tooth	2	4 (16.7%)
				Fracture of opposing denture	2	
Total		16	16 (100%)		24	24 (100%)

## DISCUSSION

The present study examined the survival rate of the implants used in IARPDs by clinical and radiographic approach, and evaluated the impact of the relevant factors.

Implant survival rates of the surveyed crown and overdenture were 95.1% and 88.2%, respectively, which was comparable to that of conventional implants. Either modality did not show significant difference in survival rate compared to the other. This could be explained by the results of this study in which various factors have combined effects on the survival rate, albeit no significant differences were observed due to the limitations in sample size. Bae *et al.*<sup>29</sup> reported that a total of 53 implants (25 implant surveyed crowns, 28 overdenture implants) were all functioning without clinical mobility.

In comparison among the surveyed crowns, the survival rates of the implants were affected by the implant diameter. The survival rate of regular implants (100%) was significantly higher than that of narrow (88.9%) or wide implants (87.5%). Clinicians planning IARPD often have difficulties in placing implants due to inadequate residual alveolar bone. If the regular diameter implants were to be placed, the bone width must be adequate for surgery. In the finite element analysis on the effect of the diameter and length of the implant in the distal extension removable partial denture, Verri *et al.*<sup>32</sup> reported that the diameter of the implant did

not influence the implant displacement values when the length was ensured. In other words, an implant with a wide diameter does not have more advantage over a regular diameter. In this regard, appropriately sized implants, not necessarily above 5.0 mm but at least over 3.75 mm, could ensure the survival in IARPDs. Several studies indicated that wide diameter implants have a higher failure rate than regular diameter implants. Ivanoff *et al.*<sup>33</sup> concluded that the higher failure rate of wide diameter implants may be caused as it is used as a rescue implant when the standard diameter implant did not secure stability or failed. Handelsman<sup>34</sup> said that a wide-bodied implant may be located closer, less than 1.5 mm to adjacent teeth or bones, thereby accelerating marginal bone loss around the adjacent teeth or facial bones. Anner *et al.*<sup>35</sup> said that the surrounding stress and bone implant contact influence the stability and survival of implants, and the use of wide diameter implant due to biological vulnerabilities in residual bones minimizes the remaining cancellous bone resulting in reduced blood supply. Grossmann<sup>11</sup> presented the clinical guideline for ISRPD and stated 'use short or narrow body implants if necessary'. Considering the 88.9% survival rate of narrow diameter implant obtained from this study, narrow implants are worth consideration for IARPD.

The mean marginal bone loss was  $1.3 \pm 1.6$  mm for all 54 implants. The amount of marginal bone loss varies depending on the point of observation. Implants with vari-



ous follow-up periods were examined, but marginal bone loss could not be presented in a function of the time of follow-up for each treatment modality. Bae *et al.*<sup>29</sup> showed that marginal bone resorption was  $1.44 \pm 0.57$  mm in implant surveyed crowns and  $1.99 \pm 0.7$  mm in overdenture implants.

The marginal bone loss of this study was 1.4-fold greater than in the study of Mitrani *et al.*,<sup>18</sup> which evaluated the bone loss around the overdenture implant in distal extension RPD during the mean time in function of 2.5 years. Significant differences of marginal bone loss were observed between Kennedy class I ( $1.5 \text{ mm} \pm 1.2 \text{ mm}$ ) and class III ( $0.2 \text{ mm} \pm 0.4 \text{ mm}$ ). The cause of this difference may be the existence of the most posterior molar in class III, which prevent the rotational movement of the dentures. Class I RPD have a greater rotation than class III RPD.<sup>36,37</sup> The differences in the amount of rotational movements between the class I bilateral distal extension RPD and the class III tooth supported RPD affect the marginal bone loss around the implants.<sup>38</sup> Based on the fact that Kennedy class III RPD has smaller denture rotating movements, it can be assumed that the masticatory load could be distributed to the most posterior molars in Kennedy class III RPD, which is more favorable to the prognosis of the implant compared to bilateral distal extension RPD of Kennedy class I. Jacobs *et al.*<sup>39</sup> reported that as the masticatory function was improved, the overdenture rotated further tissue-ward, and the load on the posterior alveolar bone increased, resulting in the increase of marginal bone loss around implants. Thus, clinicians should consider RPD designs that reduce the burden on the implants through functional improvements and gain support from the underlying tissues as well as minimize the rotation of the dentures.

Plotnick *et al.* and Fisher evaluated the effects of the opposing dentition on the mobility of mandibular natural teeth in patients with RPD due to partial edentulism.<sup>40,41</sup> Opposing upper dentures, compared to opposing natural teeth, reduced the stability of lower RPDs. According to the present study, the marginal bone loss was greater when the opposing dentitions were removable dentures (1.6 mm) than when the opposing dentitions were natural teeth of fixed prostheses (1.2 mm), though the difference was not statistically significant (Table 6). However, the implant survival rate was higher when the opposing dentitions were removable dentures (100%) than when they were fixed dentition (90.9%). Survival rate and marginal bone loss might be affected in a combined aspect by fixed dentition with relatively strong bite force and low mobility.<sup>42</sup> They might be influenced not only by the stability of opposing denture but also by the bite force.

There were various opinions regarding the location of implant for IARPD. Grossmann stated that the implant should be installed in the region where the strongest force is received to support IARPD as much as possible.<sup>11</sup> Cunha *et al.* presented that there was the least amount of denture displacement when the implant was placed in the first molar region, while there was the least stress when the implant was placed in the second premolar region.<sup>43</sup> In the present

study, there was no significant difference in survival rate and marginal bone loss according to the implant locations. Therefore, the implant location should be determined depending on the condition in each patient. A multidimensional perspective is required to consider numerous clinical variables, including the possibility of changing to fixed prosthesis in the future, the state and durability of keratinization of gingiva, and the location that minimizes the rotational movement of denture.

No particularly frequent mechanical complication was found. Mechanical complications, observed in either implant prosthesis or in conventional RPD, were also observed in IARPD. Bae *et al.*<sup>29</sup> reported that resin base relining was the most frequently observed in implant surveyed crown, while retention loss was most frequently observed in overdenture implant. The complication characteristics in IARPD presented in this study are similar to the study of incidence rates of implant prosthesis complications by Goodacre *et al.*<sup>44</sup> It seems difficult to conclude that the frequency of complications in IARPD is higher than that when only implant prosthesis exists.<sup>45,46</sup> Dislodgements of crown were the most frequently observed in surveyed crowns of IARPDs. The cement loss is inevitable in temporary cement retained prosthesis. It might be occurred frequently when the cementation in the crown weakened during the repeated removal process of IARPD. Attachment changes were most frequently observed in overdentures and four times more frequently in the IARPD using locator attachment. The problem of inherent wear in attachment makes it inevitable to replace it periodically.<sup>47</sup> The replacement/repair of the attachment is a relatively simple process, so it is difficult to regard the change as a critical complication. However, fracture of IARPD components, which required the re-fabrication of prostheses, is a more serious issue. There were 2 re-fabrications for the IARPDs. One of them fractured after 36 months of usage. The reason behind the fracture was concentration of occlusal force around the implant. The IARPD had been supported by the lower left second premolar implant to sustain the crossed occlusion, which opposed the upper remaining teeth. Most of the bite force concentrated in this implant site resulting in the fracture of the IARPD framework. It should be noted that the crown fractures of the upper left second premolar and the upper left first molar and subsequent fracture of the upper RPD occurred before the fracture of the lower IARPD. A large amount of marginal bone loss (5 mm) was also observed in the implant. In another case, the reason for the re-fabrication of the IARPD was not due to its fracture, but because the opposing denture had to be re-fabricated, it was re-fabricated together after 66 months of use. Both cases showed crown fractures preceded in the opposing dentition where the occlusal force was concentrated due to the opposing implants.

The limitation of the retrospective study was that several relevant variables of individual patients cannot be identified, such as oral status, bite force, follow-up period, and practitioner who made IARPD. With limited number of

patients involved, the study may result in weakness in confirming statistical significance. Further prospective studies are needed with larger number of patients and longer observation periods in the future to confirm the results of this study.

RPDs and implants seemed incompatible because of the RPD's rotational motion and the vulnerability of implants to the lateral forces. However, both can be manipulated to cooperate with each other if the treatment is carefully planned considering the points to be noted. Implant assisted removable partial denture can be considered as an adequate treatment modality.

## CONCLUSION

The survival rate of the implants included in this study was 93.1%: 95.1% for surveyed crowns and 88.2% for overdentures. Most implants supporting IARPDs functioned successfully throughout the follow-up periods. Within the limitations of the retrospective study, it was assumed that IARPD would be an appropriate treatment option when clinicians were confronted with poor oral conditions and situations. Further clinical long-term studies are needed to provide clinical evidence and ensure satisfactory prognosis of IARPD.

## ORCID

Soo-Hyun Kang <https://orcid.org/0000-0002-2645-9712>  
 Seong-Kyun Kim <https://orcid.org/0000-0001-8694-8385>  
 Seong-Joo Heo <https://orcid.org/0000-0003-0699-4141>  
 Jai-Young Koak <https://orcid.org/0000-0002-0190-0778>

## REFERENCES

1. Wennerberg A, Albrektsson T. Current challenges in successful rehabilitation with oral implants. *J Oral Rehabil* 2011;38:286-94.
2. Naert I, Gizani S, Vuylsteke M, Van Steenberghe D. A 5-year prospective randomized clinical trial on the influence of splinted and unsplinted oral implants retaining a mandibular overdenture: prosthetic aspects and patient satisfaction. *J Oral Rehabil* 1999;26:195-202.
3. Zitzmann NU, Marinello CP. Treatment plan for restoring the edentulous maxilla with implant-supported restorations: removable overdenture versus fixed partial denture design. *J Prosthet Dent* 1999;82:188-96.
4. Thomason JM. The McGill Consensus Statement on Overdentures. Mandibular 2-implant overdentures as first choice standard of care for edentulous patients. *Eur J Prosthodont Restor Dent* 2002;10:95-6.
5. Carlsson GE. Implant and root supported overdentures - a literature review and some data on bone loss in edentulous jaws. *J Adv Prosthodont* 2014;6:245-52.
6. Kordatzis K, Wright PS, Meijer HJ. Posterior mandibular residual ridge resorption in patients with conventional dentures and implant overdentures. *Int J Oral Maxillofac Implants* 2003;18:447-52.
7. Ohkubo C, Kurihara D, Shimpo H, Suzuki Y, Kokubo Y, Hosoi T. Effect of implant support on distal extension removable partial dentures: in vitro assessment. *J Oral Rehabil* 2007;34:52-6.
8. Kaufmann R, Friedli M, Hug S, Mericske-Stern R. Removable dentures with implant support in strategic positions followed for up to 8 years. *Int J Prosthodont* 2009;22:233-42.
9. Kuzmanovic DV, Payne AG, Purton DG. Distal implants to modify the Kennedy classification of a removable partial denture: a clinical report. *J Prosthet Dent* 2004;92:8-11.
10. Mijiritsky E, Ormianer Z, Klinger A, Mardinger O. Use of dental implants to improve unfavorable removable partial denture design. *Compend Contin Educ Dent* 2005;26:744-746, 748, 750.
11. Grossmann Y, Nissan J, Levin L. Clinical effectiveness of implant-supported removable partial dentures: a review of the literature and retrospective case evaluation. *J Oral Maxillofac Surg* 2009;67:1941-6.
12. Lacerda TESP, Laganà DC, González-LIMA R, Zanetti AL. Contribution to the planning of implant-supported RPD in the distal region. *RPG Rev Po's Grad* 2005;12:293-300.
13. Mijiritsky E. Implants in conjunction with removable partial dentures: a literature review. *Implant Dent* 2007;16:146-54.
14. Ohkubo C, Kobayashi M, Suzuki Y, Hosoi T. Effect of implant support on distal-extension removable partial dentures: in vivo assessment. *Int J Oral Maxillofac Implants* 2008;23:1095-101.
15. Chikunov I, Doan P, Vahidi F. Implant-retained partial overdenture with resilient attachments. *J Prosthodont* 2008;17:141-8.
16. Schneid T, Mattie P. Implant-assisted removable partial dentures. In: Phoenix RD, Cagna DR, DeFrees CF (eds). *Stewart's clinical removable partial prosthodontics*. Chicago: Quintessence, 2008. p. 259-77.
17. Park JM, Koak JY, Kim SK, Joo JH, Heo SJ. Consideration for the combination treatment of removable partial denture and implant. *Implantology* 2015;19:104-11.
18. Mitrani R, Brudvik JS, Phillips KM. Posterior implants for distal extension removable prostheses: a retrospective study. *Int J Periodont Restor Dent* 2003;23:353-9.
19. Bortolini S, Natali A, Franchi M, Coggiola A, Consolo U. Implant-retained removable partial dentures: an 8-year retrospective study. *J Prosthodont* 2011;20:168-72.
20. Ancowitz S. Esthetic removable partial dentures. *Gen Dent* 2004;52:453-60.
21. Mijiritsky E, Karas S. Removable partial denture design involving teeth and implants as an alternative to unsuccessful fixed implant therapy: a case report. *Implant Dent* 2004;13:218-22.
22. Shahmiri RA, Atieh MA. Mandibular Kennedy Class I implant-tooth-borne removable partial denture: a systematic review. *J Oral Rehabil* 2010;37:225-34.
23. Payne AG, Tawse-Smith A, Wismeijer D, De Silva RK, Ma S. Multicentre prospective evaluation of implant-assisted mandibular removable partial dentures: surgical and prosthodontic outcomes. *Clin Oral Implants Res* 2017;28:116-25.

24. Jang Y, Emtiaz S, Tarnow DP. Single implant-supported crown used as an abutment for a removable cast partial denture: a case report. *Implant Dent* 1998;7:199-204.
25. Pellecchia M, Pellecchia R, Emtiaz S. Distal extension mandibular removable partial denture connected to an anterior fixed implant-supported prosthesis: a clinical report. *J Prosthet Dent* 2000;83:607-12.
26. Starr NL. The distal extension case: an alternative restorative design for implant prosthetics. *Int J Periodontics Restorative Dent* 2001;21:61-7.
27. Chronopoulos V, Sarafianou A, Kourtis S. The use of dental implants in combination with removable partial dentures: a case report. *J Esthet Restor Dent* 2008;20:355-65.
28. Kim HY, Shin SW, Lee JY. Standardizing the evaluation criteria on treatment outcomes of mandibular implant overdentures: a systematic review. *J Adv Prosthodont* 2014;6:325-32.
29. Bae EB, Kim SJ, Choi JW, Jeon YC, Jeong CM, Yun MJ, Lee SH, Huh JB. A clinical retrospective study of distal extension removable partial denture with implant surveyed bridge or stud type attachment. *Biomed Res Int* 2017;7140870.
30. Misch CE, Perel ML, Wang HL, Sammartino G, Galindo-Moreno P, Trisi P, Steigmann M, Rebaudi A, Palti A, Pikos MA, Schwartz-Arad D, Choukroun J, Gutierrez-Perez JL, Marenzi G, Valavanis DK. Implant success, survival, and failure: the International Congress of Oral Implantologists (ICOI) Pisa Consensus Conference. *Implant Dent* 2008;17:5-15.
31. Bryant SR, Zarb GA. Crestal bone loss proximal to oral implants in older and younger adults. *J Prosthet Dent* 2003;89:589-7.
32. Verri FR, Pellizzer EP, Rocha EP, Pereira JA. Influence of length and diameter of implants associated with distal extension removable partial dentures. *Implant Dent* 2007;16:270-80.
33. Ivanoff CJ, Gröndahl K, Sennerby L, Bergström C, Lekholm U. Influence of variations in implant diameters: a 3- to 5-year retrospective clinical report. *Int J Oral Maxillofac Implants* 1999;14:173-80.
34. Handelsman M. Treatment planning and surgical considerations for placement of wide-body implants. *Compend Contin Educ Dent* 1998;19:507-16.
35. Anner R, Better H, Chaushu G. The clinical effectiveness of 6 mm diameter implants. *J Periodontol* 2005;76:1013-5.
36. Ben-Ur Z, Shifman A, Aviv I, Gorfil C. Further aspects of design for distal extension removable partial dentures based on the Kennedy classification. *J Oral Rehabil* 1999;26:165-9.
37. Carr AB, Brown DT. Biomechanics of Removable Partial Dentures. In: Carr AB, Brown DT (eds). *McCrakens's Removable Partial Prosthodontics*. St. Louis: Mosby, 2010. p. 24-8.
38. Shahmiri R, Aarts JM, Bennani V, Das R, Swain MV. Strain distribution in a Kennedy class I implant assisted removable partial denture under various loading conditions. *Int J Dent* 2013;2013:351279.
39. Jacobs R, Schotte A, van Steenberghe D, Quirynen M, Naert I. Posterior jaw bone resorption in osseointegrated implant-supported overdentures. *Clin Oral Implants Res* 1992;3:63-70.
40. Plotnick IJ, Beresin VE, Simkins AB. The effects of variations in the opposing dentition on changes in the partially edentulous mandible. Part I. Bone changes observed in serial radiographs. *J Prosthet Dent* 1975;33:278-86.
41. Fisher RL. Factors that influence the base stability of mandibular distal-extension removable partial dentures: a longitudinal study. *J Prosthet Dent* 1983;50:167-71.
42. Miyaura K, Morita M, Matsuka Y, Yamashita A, Watanabe T. Rehabilitation of biting abilities in patients with different types of dental prostheses. *J Oral Rehabil* 2000;27:1073-6.
43. Cunha LD, Pellizzer EP, Verri FR, Pereira JA. Evaluation of the influence of location of osseointegrated implants associated with mandibular removable partial dentures. *Implant Dent* 2008;17:278-87.
44. Goodacre CJ, Bernal G, Runghcharassaeng K, Kan JY. Clinical complications with implants and implant prostheses. *J Prosthet Dent* 2003;90:121-32.
45. Saito M, Notani K, Miura Y, Kawasaki T. Complications and failures in removable partial dentures: a clinical evaluation. *J Oral Rehabil* 2002;29:627-33.
46. Bilhan H, Erdogan O, Ergin S, Celik M, Ates G, Geckili O. Complication rates and patient satisfaction with removable dentures. *J Adv Prosthodont* 2012;4:109-15.
47. Seo YH, Bae EB, Kim JW, Lee SH, Yun MJ, Jeong CM, Jeon YC, Huh JB. Clinical evaluation of mandibular implant overdentures via Locator implant attachment and Locator bar attachment. *J Adv Prosthodont* 2016;8:313-20.