



Correlations between the Clinical and Ultrasonographic Parameters of Congenital Muscular Torticollis without a Sternocleidomastoid Mass

Jisun Hwang, MD¹, Eun Kyung Khil, MD¹, Soo Jin Jung, MD, PhD², Jung-Ah Choi, MD, PhD¹

Departments of ¹Radiology and ²Rehabilitation Medicine, Hallym University Dongtan Sacred Heart Hospital, Hwaseong, Korea

Objective: To determine whether ultrasonography at initial presentation can help assess the clinical severity of congenital muscular torticollis (CMT) in infants without a sternocleidomastoid muscle (SCM) mass.

Materials and Methods: This retrospective study included 71 infants aged less than 12 months (4.1 ± 2.3 months) with non-mass CMT. The clinical severity was divided into three grades (groups 1–3) based on the degree of lateral head bending or cervical rotation. The difference (SCM-D) and ratio (SCM-R) between the maximal thickness of the affected and non-affected SCMs were obtained using transverse and longitudinal ultrasonography. The sonographic echotexture and echogenicity of the involved SCM were reviewed.

Results: A significant difference was observed in the SCM-D (0.42 ± 0.30 mm in group 1; 0.74 ± 0.50 mm in group 2; 1.14 ± 0.85 mm in group 3; $p = 0.002$) and SCM-R (1.069 ± 0.067 in group 1; 1.129 ± 0.087 in group 2; 1.204 ± 0.150 in group 3; $p = 0.001$) among the groups when measured along the longitudinal but not along the transverse ultrasonography plane. The areas under the curves of the SCM-R and SCM-D measured by longitudinal ultrasonography were 0.731 ($p < 0.001$) and 0.731 ($p < 0.001$) for group 1 versus groups 2–3. The proportions of heterogeneous echotexture or hyperechogenicity in the involved SCM did not differ significantly among the three clinical groups (all $p > 0.05$).

Conclusion: Ultrasonography can aid in assessing the clinical severity of CMT in infants without an SCM mass at the time of initial diagnosis. The SCM-R and SCM-D helped grade the clinical severity when obtained by longitudinal scan.

Keywords: Ultrasonography; Congenital torticollis; Sternocleidomastoid muscle; Pediatric

INTRODUCTION

Congenital muscular torticollis (CMT), the third most common orthopedic diagnosis in children, is caused by unilateral shortening of the sternocleidomastoid muscle (SCM), resulting in the characteristic typical ipsilateral head tilt and rotation of the face and chin toward the opposite side (1, 2). The underlying pathogenesis of CMT is unclear.

The various proposed etiologies include fibrosis due to peripartum hemorrhage, intrauterine crowding, and primary myopathy (3, 4).

CMT is divided into three types—postural, muscular, and SCM mass-type (2)—that reportedly occur in 22.1%, 30.6%, and 42.7% of cases, respectively (5). Postural CMT is the mildest form resulting from the postural preference of the infant, without limitation in the passive range of motion (PROM). Muscular CMT is caused by muscle tightness and restriction in the PROM but no clinical tumor. SCM mass-type CMT is also known as fibromatosis colli. It is the most severe form, with restriction in PROM, and is associated with a longer treatment duration (2). In most cases, observation and physical therapy usually lead to favorable outcomes, particularly when treatment is started within the first year of life (1). The SCM mass increases in size for several weeks, stop changing over 2–3 months, and then slowly regress for 4 to 8 months in approximately 50–70%

Received: November 29, 2019 **Revised:** March 10, 2020

Accepted: April 16, 2020

Corresponding author: Eun Kyung Khil, MD, Department of Radiology, Hallym University Dongtan Sacred Heart Hospital, 7 Keunjaebong-gil, Hwaseong 18450, Korea.

• E-mail: nizzinim@gmail.com

This is an Open Access article distributed under the terms of the Creative Commons Attribution Non-Commercial License (<https://creativecommons.org/licenses/by-nc/4.0>) which permits unrestricted non-commercial use, distribution, and reproduction in any medium, provided the original work is properly cited.

of patients within the first year of life (1, 6). When physical therapy is ineffective, surgical lengthening or botulinum A toxin injection may be performed (7-9).

Ultrasonography (US) is the first-choice imaging modality for infants with CMT (10). US has many benefits over other imaging modalities, particularly in the pediatric population, since it does not require sedation, is widely available, and lacks radiation exposure. Several common US findings have been noted in CMT without an SCM mass, including diffuse hyperechogenicity along the entire muscle and hyperechoic band (11, 12). However, to our knowledge, no studies have focused only on infants without a palpable mass or without a recognizable mass on US to correlate the US findings with the clinical severity at initial presentation. Thus, our study aimed to determine whether US at initial presentation could help to assess the clinical severity of CMT in infants without an SCM mass on both physical and US examinations.

MATERIALS AND METHODS

Our Institutional Review Board approved this retrospective study and waived the requirement for informed consent.

Participants

We retrospectively identified 140 infants under 12 months of age who visited the outpatient clinic of the Department of Rehabilitation Medicine due to head tilting or rotation and were suspected of having CMT, regardless of a palpable mass along the SCM, between March 2017 and December 2018. All participants underwent neck US for evaluation

of CMT on the day of the outpatient clinic visit, as well as cervical spine radiography with anteroposterior and lateral views to rule out congenital bony abnormalities.

The exclusion criteria were as follows: 1) inaccurate measurement due to excessive crying and movement ($n = 8$, 5.7%); 2) SCM mass on US ($n = 61$, 43.5%); and 3) secondary causes of torticollis (congenital anomaly of the cervical spine, ocular torticollis, and neurogenic or spasmodic torticollis) ($n = 0$). Finally, our study included 71 infants (33 males/38 females) (Supplementary Fig. 1). Their mean age was 4.1 ± 2.3 months (range, 1–12 months).

US Examination

US examination of the bilateral SCM was performed by a radiologist (with 7 years of experience in musculoskeletal US) using a Philips iU22 scanner (Philips Healthcare) with a 12.5-MHz linear array transducer. In our institution, while a hockey-stick transducer could be used for US examination of patients with small and short necks, none of the patients included in our study required this transducer. During the examination, the infants were placed in the supine position with their head slightly rotated to the opposite side and their neck gently extended by placing a small rolled towel below the shoulder (13, 14). A large quantity of transmission gel was applied to reduce the effect of compression of the SCM. The thickness of the bilateral SCM was measured on both longitudinal and transverse US when the muscle was relaxed and stretched as much as possible, while avoiding exaggerated contraction of the muscle during the infants' crying (Fig. 1). The maximal anteroposterior diameter of the

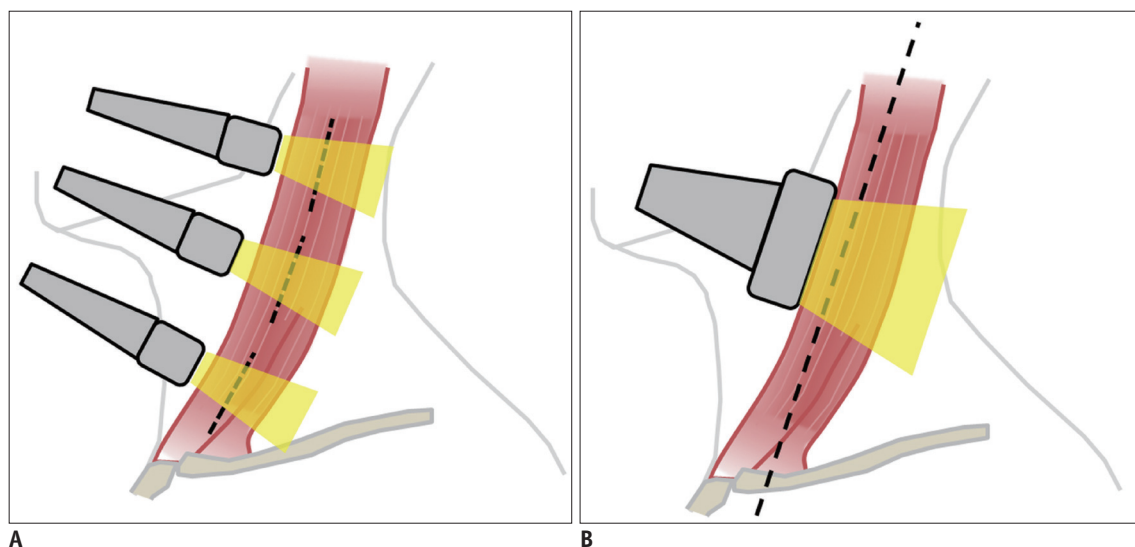


Fig. 1. Scheme for measurement of SCM thickness on transverse (A) and longitudinal (B) US. Dotted lines represent main long axis of SCM. SCM = sternocleidomastoid muscle, US = ultrasonography

SCM was measured three times in the upper, middle, and lower thirds of the entire length on the transverse scan, perpendicular to the long axis of the muscle. The largest of the three values was selected as the representative transverse US value. The maximal thickness was measured two or three times on the longitudinal scan to cover the entire length in the plane parallel to the muscle fibers, with the thickness of the muscle belly maintained as uniform as possible from one side to the opposite side. The largest of the two or three values was selected as the representative value of the longitudinal scan.

Image Analysis

The ratio (SCM-R; affected/non-affected muscle thicknesses) and difference (SCM-D; affected–non-affected muscle thicknesses) between the maximal thickness of the affected and non-affected SCMs were calculated on the US images (Fig. 2), as described previously (13, 15). Both SCM-R and SCM-D were assessed considering inter-individual variation in baseline SCM thickness. Two radiologists (with 5 years of experience in pediatric US, respectively) reviewed the US images and classified the echotexture and

echogenicity of the affected SCM in a consensual manner. The echogenicity characteristics of the affected SCM were compared to those of the uninvolved side and classified as 1) homogenous or heterogeneous; and 2) hyperechoic, isoechoic, or hypoechoic (16, 17) (Fig. 3).

Clinical Evaluation

A board-certified rehabilitation medicine specialist (with 10 years of experience) performed the physical examinations for all infants and recorded the cervical PROM limitation and degree of head tilt and rotation. Two reviewers classified the patients using a three-point scoring system, according to the degree of lateral head bending or cervical rotation based on the electronic medical records as follows: group 1, no suspicious finding on physical examination; group 2, lateral head tilt or rotation $\leq 10^\circ$; and group 3, angulation $> 10^\circ$ (18). The presence of plagiocephaly was also assessed in the participants of each group.

Statistical Analysis

Continuous variables were expressed as means \pm standard deviation or medians with ranges. Categorical data from

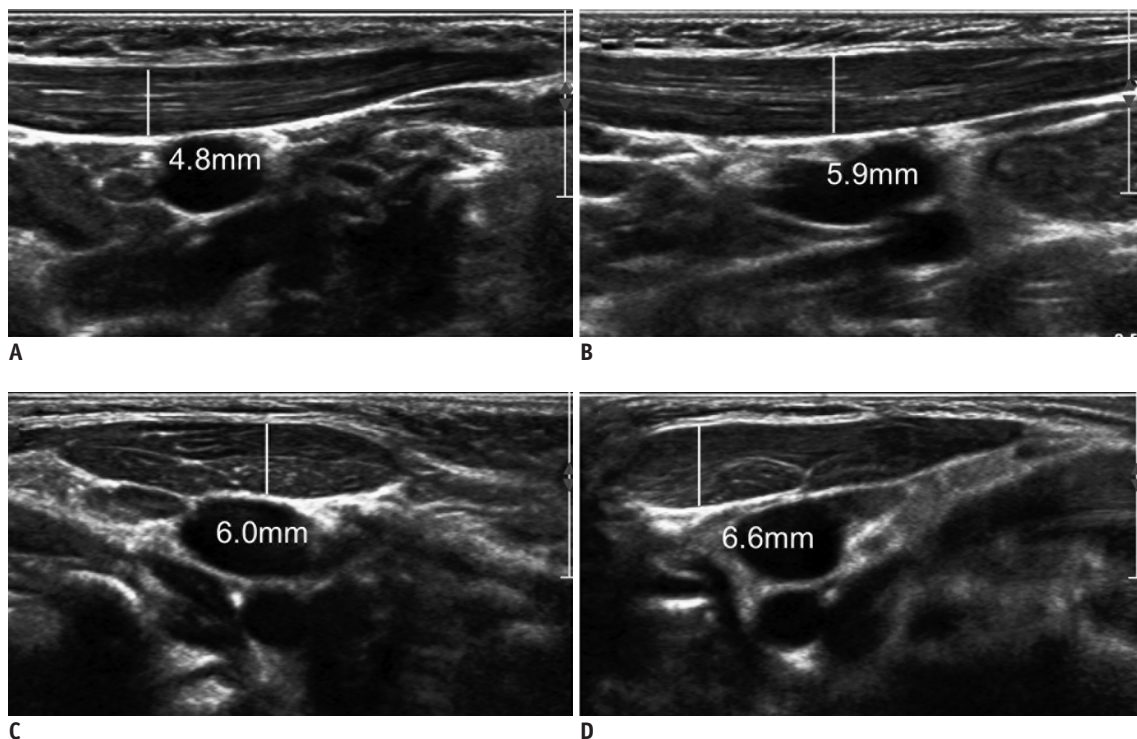


Fig. 2. 6-month-old girl presented with left-sided torticollis (clinical group 1).

Measurement of maximal thicknesses of non-affected (A, C) and affected (B, D) SCMs by longitudinal (A, B) and transverse (C, D) US. SCM-Ds obtained by longitudinal and transverse scans were 1.1 cm and 0.6 cm, respectively. SCM-Rs obtained by longitudinal and transverse US scans were 1.22 and 1.10, respectively. SCM-D = difference between maximal thickness of affected and non-affected SCMs, SCM-R = ratio between maximal thickness of affected and non-affected SCMs

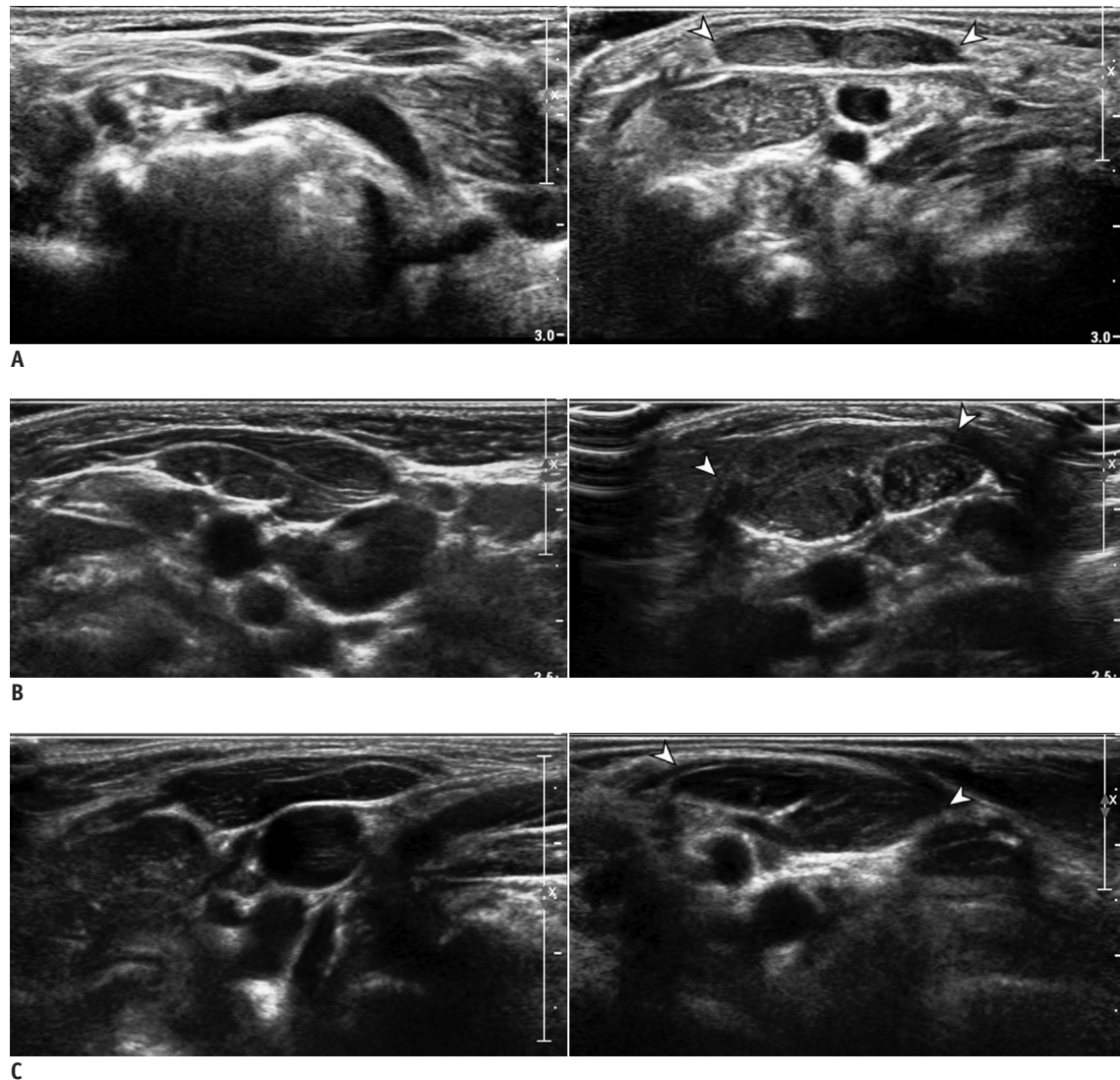


Fig. 3. Transverse sonograms of non-affected (left panel) and affected (right panel) SCMs in three patients.
A. Homogeneous hyperechoic (arrowheads in right panel). **B.** Heterogeneous hyperechoic (arrowheads in right panel). **C.** Homogeneous isoechoic (arrowheads in right panel).

the three clinical groups were compared using chi-squared or Fisher's exact tests. SCM-R and SCM-D were shown as error bars according to the three clinical grades. The differences in the US parameters among the three groups were evaluated by analysis of variance (ANOVA) tests. Multiple pairwise comparisons were conducted using Tukey's multiple comparison tests, in cases of statistical significance. Receiver operating characteristic (ROC) analysis was performed to determine the diagnostic performance of the SCM-R and SCM-D. The areas under the ROC curve (AUC) with their corresponding 95% confidence intervals were calculated. DeLong's tests were used to compare the statistical difference between AUCs. The optimal cutoff value was determined using Youden's Index. All statistical analyses

were performed using SPSS Statistics for Windows, version 20.0 (IBM Corp.) and MedCalc Statistical Software, version 18.5 (MedCalc Software). The significance level was set to 5%.

RESULTS

Patients' Characteristics

The patients' baseline characteristics are summarized in Table 1. The average thickness of the non-affected SCM was 5.9 ± 1.1 mm on transverse US and 5.9 ± 1.1 mm on longitudinal US. Based on the clinical evaluations, we classified 18, 35, and 18 infants into groups 1, 2, and 3, respectively. We observed significant differences in ages between groups 1 and 2 ($p = 0.001$) and groups 1 and 3 ($p =$

0.004). The patients in group 1 were significantly younger than those were in the other groups. However, we observed no significant intergroup differences in sex, weight, and gestational age at birth. Forty-four patients (61.9%) had plagiocephaly and the proportions of patients with plagiocephaly did not differ significantly between patients with and without abnormalities on physical examinations (group 1 vs. groups 2–3) ($p = 0.931$).

SCM-R

We observed a significant difference in the SCM-R among the subgroups when measured on longitudinal ($p = 0.001$) but not transverse US ($p = 0.180$) (Table 2). Figure 4A and B shows the error bars for SCM-R according to the three groups. We observed a significant increase in the SCM-R on longitudinal US between the infants in groups 1 and 3 ($p < 0.001$) and groups 2 and 3 ($p = 0.036$), respectively (Table 2, Fig. 4). We observed no significant difference in the SCM-R between the infants in groups 1 and 2 ($p = 0.120$) on longitudinal US.

SCM-D

We observed significant differences in SCM-D among the groups when measured on longitudinal ($p = 0.002$) but not

transverse US ($p = 0.250$) (Table 2). Figure 4C and D shows the error bars of SCM-D according to the three groups. The SCM-D on longitudinal US was different for groups 1 and 3 ($p = 0.001$) (Table 2, Fig. 4). We observed no significant difference in SCM-D between the infants in groups 1 and 2 ($p = 0.135$) and groups 2 and 3 ($p = 0.050$), respectively, on longitudinal US.

Diagnostic Performance of SCM-R and SCM-D on Longitudinal US Scan

We assessed the diagnostic performance of SCM-R and SCM-D for the longitudinal scan only and not for the transverse scan due to the lack of intergroup difference in the ANOVA tests. The SCM-R (cutoff, 1.07; sensitivity, 73.6%; specificity, 61.1%; AUC, 0.731) and SCM-D (cutoff, 0.9 mm; sensitivity, 45.3%; specificity, 94.4%; AUC, 0.731) showed moderate accuracy for the detection of clinical groups 2–3 (Table 3). DeLong's tests revealed no significant differences between the AUCs of SCM-R and SCM-D ($p > 0.999$). The SCM-R and SCM-D did not detect clinical group 3 with significant accuracy ($p > 0.05$) (Table 3).

Echogenicity Characteristics of the Affected SCM on US

Forty-eight (67.6%) patients showed no alteration in

Table 1. Demographic Data according to Clinical Groups

Characteristics	Total	Group 1	Group 2	Group 3
Sex (n, male/female)	33/38	7/11	17/18	9/9
Age (months)	4.1 ± 2.3	2.8 ± 2.6*	4.3 ± 1.9	4.8 ± 2.2
Weight (kg)	3.08 ± 0.51	3.03 ± 0.33	3.13 ± 0.53	3.03 ± 0.65
Gestational age at birth (weeks)	38.6 ± 1.5	38.4 ± 1.1	38.7 ± 1.6	38.5 ± 1.5
Direction of head tilting (n, right/left)	28/43	8/10	11/24	9/9
Plagiocephaly (%)	61.9	61.1 [†]	68.5	50.0

Unless otherwise indicated, data are means ± standard deviations. *Patients in group 1 were significantly younger than those in group 2 ($p = 0.001$) and group 3 ($p = 0.004$), [†]Proportion of plagiocephaly were not significantly different between patients in group 1 versus group 2–3 ($p = 0.931$).

Table 2. Results of SCM-R and SCM-D by Longitudinal and Transverse US Scan

Parameters	Group 1 (n = 18)	Group 2 (n = 35)	Group 3 (n = 18)	P
Longitudinal scan				
SCM-R	1.069 ± 0.067 [†]	1.129 ± 0.087 [†]	1.204 ± 0.150 ^{††}	0.001*
SCM-D (mm)	0.42 ± 0.30 [§]	0.74 ± 0.50	1.14 ± 0.85 [§]	0.002*
Transverse scan				
SCM-R	1.039 ± 0.144	1.137 ± 0.259	1.087 ± 0.162	0.180
SCM-D (mm)	0.62 ± 0.46	0.99 ± 0.91	0.91 ± 0.62	0.250

Data are means ± standard deviations. *Significant difference among subgroups by analysis of variance. In post-hoc analyses of measurements on longitudinal scan, mean SCM-R of group 3 were significantly higher than those for [†]group 1 ($p < 0.001$) and ^{††}group 2 ($p = 0.036$), respectively. Mean SCM-D of group 3 was significantly higher than those for [§]group 1 ($p = 0.001$). SCM = sternocleidomastoid muscle, SCM-D = difference between maximal thickness of affected and non-affected SCMs, SCM-R = ratio between maximal thickness of affected and non-affected SCMs, US = ultrasonography

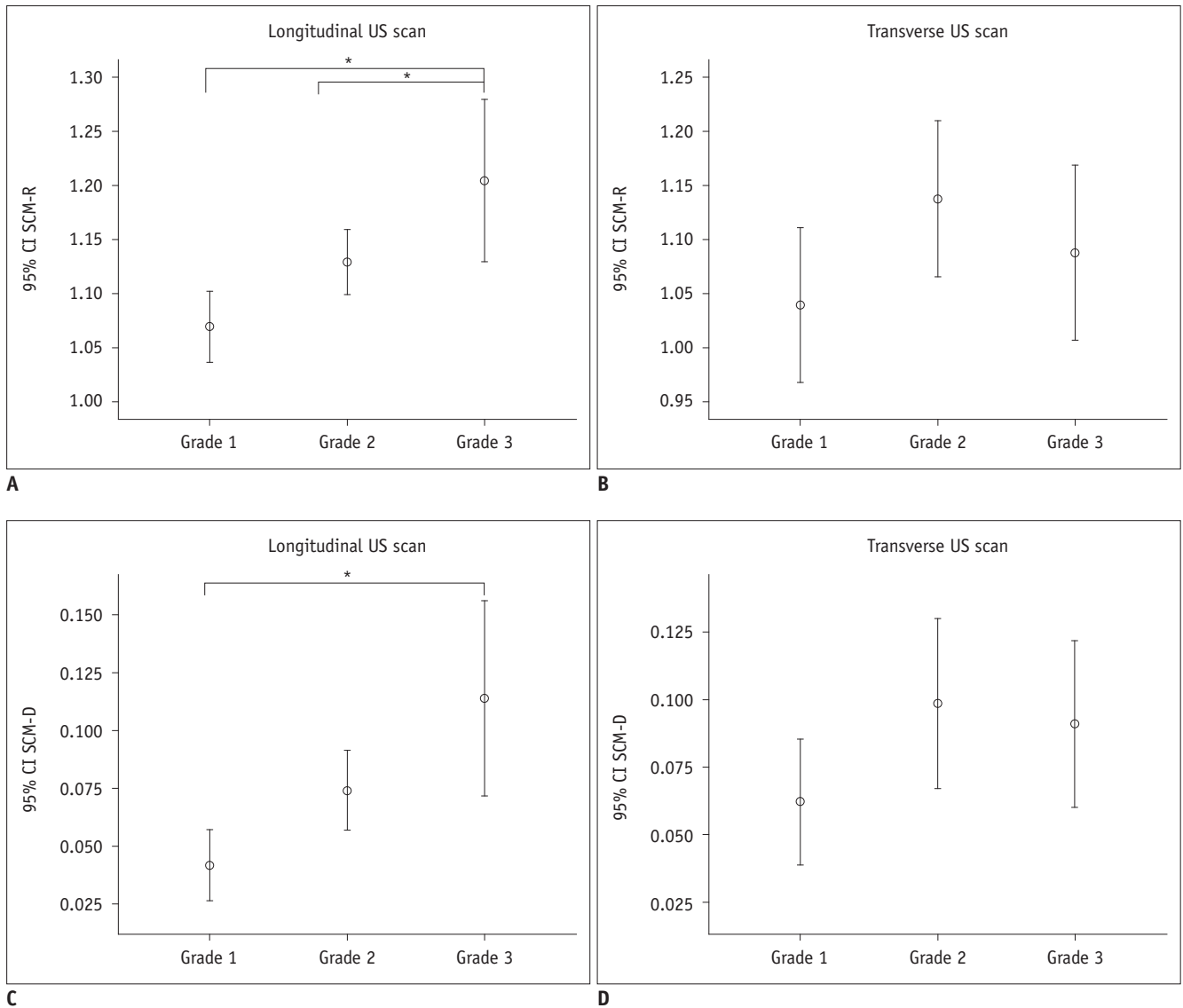


Fig. 4. Error bar chart (CI of mean) of SCM-R on longitudinal (A) and transverse US scans (B) and SCM-D on longitudinal (C) and transverse US scans (D). Charts indicate means (circles) and 95% CIs (error bars). Asterisks represent significant intergroup differences obtained using Tukey's multiple comparisons. CI = confidence interval

echogenicity (homogenous and isoechoic), 18 (25.3%) showed a heterogeneous echotexture, and 23 (32.3%) showed hyperechogenicity in the affected SCM. None of the involved SCMs showed hypoechoic changes. The proportions of infants with heterogeneous echotexture or hyperechogenicity in the affected SCM did not differ significantly among the three groups ($p > 0.999$ and $p = 0.357$, respectively) (Table 4).

DISCUSSION

The SCM-R and SCM-D differentiated between the three groups classified based on the clinical severity only on

longitudinal US, with moderate accuracy for differentiating groups 2–3 from group 1. In other words, the US parameters substantially differed between patients with and without abnormality on physical examination. Of the two parameters, the SCM-D is simpler and easier for the operator to calculate while simultaneously performing US. Although the ROCs of SCM-R and SCM-D for the longitudinal scan showed comparable diagnostic performance for detecting groups 2–3, the higher specificity of the SCM-D indicates its usefulness for confirmation in infants not suspected of having CMT. The cutoff values for detecting groups 2–3 may seem small (SCM-D: 0.9 mm); however, considering that the average thickness of the non-affected SCM was only 5.9

Table 3. Diagnostic Performance of SCM-R and SCM-D on Longitudinal US Scan for Differentiating Subgroups

Parameters	Cutoff	Sensitivity (%)	Specificity (%)	AUC	95% CI	P
Group 1 (n = 18) vs. group 2–3 (n = 53)						
SCM-R	1.07	73.6	61.1	0.731*	0.613–0.830	< 0.001
SCM-D (mm)	0.9	45.3	94.4	0.731*	0.613–0.830	< 0.001
Group 1–2 (n = 53) vs. group 3 (n = 18)						
SCM-R	1.21	50	90.6	0.660	0.538–0.768	0.078
SCM-D (mm)	1	50	84.9	0.665	0.543–0.773	0.059

*No significant difference was observed between data by DeLong's test ($p > 0.999$). AUC = area under receiver operating characteristic curve, CI = confidence interval

Table 4. Results of Echotexture and Echogenicity of Affected SCM according to Clinical Groups

Parameters	Total (n = 71)	Group 1 (n = 18)	Group 2 (n = 35)	Group 3 (n = 18)	P
Echotexture					> 0.999
Heterogeneous	18 (25.3)	5 (27.7)	9 (25.7)	4 (22.2)	
Homogeneous	53 (74.6)	13 (72.2)	26 (74.2)	14 (77.7)	
Echogenicity					0.357
Hyperechoic	23 (32.3)	8 (44.4)	11 (31.4)	4 (22.2)	
Isoechoic	48 (67.6)	10 (55.5)	24 (68.5)	14 (77.7)	
Hypoechoic	0	0	0	0	

Data are numbers of cases, with percentages in parentheses.

± 1.1 mm, this can be a substantial value. The SCM-R and SCM-D measured on longitudinal US showed an increasing tendency according to the clinical severity and significant differences in the mean comparisons among the three clinical groups. After intergroup comparison, both values differed significantly between clinical groups 1 and 3.

We analyzed the SCM-D and SCM-R measured on both transverse and longitudinal US and found that the SCM-D and SCM-R assessed by transverse US were not related to the clinical severity. Most studies on CMT have used longitudinal US to measure SCM thickness (15, 19) and transverse US to measure SCM cross-sectional area (19, 20). One study used transverse or longitudinal US by choosing images showing the largest cross-section of the lesion (21). During longitudinal US, operators can use secondary signs such as a parallel hyperechoic perimysium and hypoechoic muscle fibers to maintain the correct axis of the SCM. In contrast, there is a greater potential for an oblique scanning axis during transverse US. Moreover, the point of maximal thickness can be chosen from nearly the entire length of the muscle on the monitor during longitudinal US. Conversely, the muscle segment with the maximum thickness can be easily missed during transverse scanning from the upper to the lower part. These technical factors might contribute to the difference in accuracy between longitudinal and transverse scans.

Several studies have correlated SCM mass abnormalities

on US with prognosis or treatment course (11, 13, 15, 18, 21, 22). They reported that length measurements—SCM mass thickness and thickness ratio or difference between the affected and normal side—were correlated with clinical improvement and treatment duration (15, 21). The type of echogenicity of the SCM mass has also been reported to have a prognostic role; patients with diffuse hyperechogenicity along the entire SCM or a longitudinal hyperechoic band within the normal SCM required a longer treatment duration and showed a higher rate of surgical treatment (11, 22, 23). An alteration in the SCM mass echogenicity reflects various stages of muscle fiber degeneration (23, 24). A heterogeneous echotexture of a mass indicates fibrous tissue mixed with normal SCM fibers. Diffuse hyperechogenicity represents a severe degree of fibrosis with nearly absent normal SCM fibers. However, in our study, hyperechogenicity or heterogeneous echotexture were not correlated with the clinical severity and the prevalence was lower (32.3%) than that reported by Kim and Kim (63%) (16).

Two studies compared US-normal and abnormal groups in patients with CMT (18, 25). Both studies confirmed that the US-normal group showed a smaller cervical PROM deficit and better prognosis with a shorter treatment duration than those in the US-abnormal group. The histologic findings of fibromatosis colli include edema, muscle degeneration, and subsequent fibrosis (10, 26). Meanwhile, a different

underlying pathophysiology has been postulated for the US-normal group with CMT (25, 27) and SCM imbalance has been suggested as a cause of postural torticollis (27). In our study, the patients could be clinically diagnosed with either muscular or postural CMT. Although we could not confirm the pathological finding of thickened SCM in the higher-level clinical group due to a generally favorable outcome of CMT, fibrosis being too mild to be clearly recognized as focal SCM-mass type on US, idiopathic thickening and tightness, or SCM imbalance might explain our findings. However, our results should be confirmed by further studies.

Non-mass CMT comprises more than half of the total CMT cases (5) and is a significant subgroup requiring US in clinical practice. Our result suggests that if the bilateral SCMs are asymmetrical and the symptomatic side is substantially thicker than the opposite side, the US findings may support the diagnosis of CMT and aid clinicians in the decision to initiate physiotherapy. Moreover, our study revealed a relatively low incidence of alteration in echogenicity. Therefore, quantitative measurement of thickness may be more helpful than the echogenic features for the evaluation of non-mass CMT.

In our study, the patients in group 1 were significantly younger than those were in the other groups. In a previous study, older age at presentation was significantly associated with a longer treatment duration and a greater requirement for surgical treatment (28). While the younger patients in group 1 might be expected to have a better prognosis, we could not evaluate the prognosis of each subgroup due to the retrospective study design and the benign clinical course of CMT, which did not require follow-up examination in most patients.

We also evaluated the prevalence of plagiocephaly. The persistent twisted position of the neck can induce deformational plagiocephaly (1). Rogers et al. (29) reported that more than 90% of infants with deformational plagiocephaly were associated with torticollis. The incidence of plagiocephaly in our study (61.9%) was similar to that of the non-SCM lesion group in a previous study (56.5%) (25). The proportions of plagiocephaly did not differ significantly between patients with and without abnormalities on physical examination and were not influenced by the clinical severity.

Our study had several limitations. First, the data were retrospectively obtained and we could not classify infants into muscular and postural torticollis groups. Second,

we could not confirm the pathological findings of SCM thickening because CMT is a benign entity. Third, the interobserver agreement could not be evaluated due to the agitation of the infants.

In conclusion, the SCM-R and SCM-D obtained by US could be a useful tool in CMT even in infants without an SCM mass. In particular, SCM-D is a straightforward parameter that could be used to help grade the clinical severity when obtained on longitudinal US. Alterations in the echogenicity and echotexture of the involved SCM were not common findings in non-mass CMT and were not associated with clinical severity.

Supplementary Materials

The Data Supplement is available with this article at <https://doi.org/10.3348/kjr.2019.0893>.

Conflicts of Interest

The authors have no potential conflicts of interest to disclose.

ORCID iDs

Jisun Hwang

<https://orcid.org/0000-0002-7593-2246>

Eun Kyung Khil

<https://orcid.org/0000-0002-7764-4344>

Soo Jin Jung

<https://orcid.org/0000-0002-3621-3759>

Jung-Ah Choi

<https://orcid.org/0000-0002-0896-4766>

REFERENCES

1. Do TT. Congenital muscular torticollis: current concepts and review of treatment. *Curr Opin Pediatr* 2006;18:26-29
2. Kaplan SL, Coulter C, Sargent B. Physical therapy management of congenital muscular torticollis: a 2018 evidence-based clinical practice guideline from the APTA academy of pediatric physical therapy. *Pediatr Phys Ther* 2018;30:240-290
3. Tang S, Liu Z, Quan X, Qin J, Zhang D. Sternocleidomastoid pseudotumor of infants and congenital muscular torticollis: fine-structure research. *J Pediatr Orthop* 1998;18:214-218
4. Davids JR, Wenger DR, Mubarak SJ. Congenital muscular torticollis: sequela of intrauterine or perinatal compartment syndrome. *J Pediatr Orthop* 1993;13:141-147
5. Cheng JC, Tang SP, Chen TM, Wong MW, Wong EM. The clinical presentation and outcome of treatment of congenital muscular torticollis in infants—a study of 1,086 cases. *J*

- Pediatr Surg* 2000;35:1091-1096
6. Morrison DL, MacEwen GD. Congenital muscular torticollis: observations regarding clinical findings, associated conditions, and results of treatment. *J Pediatr Orthop* 1982;2:500-505
 7. Oleszek JL, Chang N, Apkon SD, Wilson PE. Botulinum toxin type a in the treatment of children with congenital muscular torticollis. *Am J Phys Med Rehabil* 2005;84:813-816
 8. Burstein FD. Long-term experience with endoscopic surgical treatment for congenital muscular torticollis in infants and children: a review of 85 cases. *Plast Reconstr Surg* 2004;114:491-493
 9. Kaplan SL, Coulter C, Fetters L. Physical therapy management of congenital muscular torticollis: an evidence-based clinical practice guideline: from the Section on Pediatrics of the American Physical Therapy Association. *Pediatr Phys Ther* 2013;25:348-394
 10. Haque S, Bilal Shafi BB, Kaleem M. Imaging of torticollis in children. *Radiographics* 2012;32:557-571
 11. Tang SF, Hsu KH, Wong AM, Hsu CC, Chang CH. Longitudinal followup study of ultrasonography in congenital muscular torticollis. *Clin Orthop Relat Res* 2002;(403):179-185
 12. Robbin MR, Murphey MD, Temple HT, Kransdorf MJ, Choi JJ. Imaging of musculoskeletal fibromatosis. *Radiographics* 2001;21:585-600
 13. Lee K, Chung E, Koh S, Lee BH. Outcomes of asymmetry in infants with congenital muscular torticollis. *J Phys Ther Sci* 2015;27:461-464
 14. Lee JY, Koh SE, Lee IS, Jung H, Lee J, Kang JI, et al. The cervical range of motion as a factor affecting outcome in patients with congenital muscular torticollis. *Ann Rehabil Med* 2013;37:183-190
 15. Han JD, Kim SH, Lee SJ, Park MC, Yim SY. The thickness of the sternocleidomastoid muscle as a prognostic factor for congenital muscular torticollis. *Ann Rehabil Med* 2011;35:361-368
 16. Kim SJ, Kim DW. Correlation between the volume of a lesion or physical training, and regression time, in congenital torticollis patients. *J Korean Soc Radiol* 2013;68:385-390
 17. Kim SN, Shin YB, Kim W, Suh H, Son HK, Cha YS, et al. Screening for the coexistence of congenital muscular torticollis and developmental dysplasia of hip. *Ann Rehabil Med* 2011;35:485-490
 18. Lee YT, Park JW, Lim M, Yoon KJ, Kim YB, Chung PW, et al. A clinical comparative study of ultrasound-normal versus ultrasound-abnormal congenital muscular torticollis. *PM R* 2016;8:214-220
 19. Lim D, Kwon W, Cha SW, Yoo H, Lim S, Park JM, et al. The sonographic correlation between the sternocleidomastoid muscle thickness and the prognosis of congenital muscular torticollis. *J Korean Soc Radiol* 2009;60:133-138
 20. Chan YL, Cheng JC, Metreweli C. Ultrasonography of congenital muscular torticollis. *Pediatr Radiol* 1992;22:356-360
 21. Park HJ, Kim SS, Lee SY, Lee YT, Yoon K, Chung EC, et al. Assessment of follow-up sonography and clinical improvement among infants with congenital muscular torticollis. *AJNR Am J Neuroradiol* 2013;34:890-894
 22. Lee YT, Yoon K, Kim YB, Chung PW, Hwang JH, Park YS, et al. Clinical features and outcome of physiotherapy in early presenting congenital muscular torticollis with severe fibrosis on ultrasonography: a prospective study. *J Pediatr Surg* 2011;46:1526-1531
 23. Hsu TC, Wang CL, Wong MK, Hsu KH, Tang FT, Chen HT. Correlation of clinical and ultrasonographic features in congenital muscular torticollis. *Arch Phys Med Rehabil* 1999;80:637-641
 24. Lin JN, Chou ML. Ultrasonographic study of the sternocleidomastoid muscle in the management of congenital muscular torticollis. *J Pediatr Surg* 1997;32:1648-1651
 25. Han MH, Kang JY, Do HJ, Park HS, Noh HJ, Cho YH, et al. Comparison of clinical findings of congenital muscular torticollis between patients with and without sternocleidomastoid lesions as determined by ultrasonography. *J Pediatr Orthop* 2019;39:226-231
 26. Apple SK, Nieberg RK, Hirschowitz SL. Fine needle aspiration diagnosis of fibromatosis colli. A report of three cases. *Acta Cytol* 1997;41:1373-1376
 27. Golden KA, Beals SP, Littlefield TR, Pomatto JK. Sternocleidomastoid imbalance versus congenital muscular torticollis: their relationship to positional plagiocephaly. *Cleft Palate Craniofac J* 1999;36:256-261
 28. Cheng JC, Wong MW, Tang SP, Chen TM, Shum SL, Wong EM. Clinical determinants of the outcome of manual stretching in the treatment of congenital muscular torticollis in infants. A prospective study of eight hundred and twenty-one cases. *J Bone Joint Surg Am* 2001;83:679-687
 29. Rogers GF, Oh AK, Mulliken JB. The role of congenital muscular torticollis in the development of deformational plagiocephaly. *Plast Reconstr Surg* 2009;123:643-652