



Comparison of Urologist Satisfaction for Different Types of Prostate MRI Reports: A Large Sample Investigation

Jinman Zhong, MD^{1, 2}, Weijun Qin, MD³, Yu Li, MS³, Yang Wang, MS¹,
Yi Huan, MD, PhD¹, Jing Ren, MD, PhD¹

¹Departments of Radiology and ³Urology, Xijing Hospital, Fourth Military Medical University, Xi'an, China; ²Department of Radiology, The Second Affiliated Hospital, Xi'an Jiaotong University, Xi'an, China

Objective: To evaluate urologist satisfaction on structured prostate MRI reports, including report with tumor-node-metastasis (TNM) staging (report B) and with Prostate Imaging Reporting and Data System (PI-RADS) score with/without TNM staging (report C, report with PI-RADS score only [report C-a] and report with PI-RADS score and TNM staging [C-b]) compared with conventional free-text report (report A).

Materials and Methods: This was a prospective comparative study. Altogether, 3015 prostate MRI reports including reports A, B, C-a, and C-b were rated by 13 urologists using a 5-point Likert Scale. A questionnaire was used to assess urologist satisfaction based on the following parameters: correctness, practicality, and urologist subjectivity. Kruskal-Wallis H-test followed by Nemenyi test was used to compare urologists' satisfaction parameters for each report type. The rate of urologist-radiologist recalls for each report type was calculated.

Results: Reports B and C including its subtypes had higher ratings of satisfaction than report A for overall satisfaction degree, and parameters of correctness, practicality, and subjectivity ($p < 0.05$). There was a significant difference between report B and C ($p < 0.05$) in practicality score, but no statistical difference was found in overall satisfaction degree, and correctness and subjectivity scores ($p > 0.05$). Compared with report C-b ($p > 0.05$), report B and C-a ($p < 0.05$) showed a significant difference in overall satisfaction degree and parameters of practicality and subjectivity. In terms of correctness score, neither report C-a nor C-b had a significant difference with report B ($p > 0.05$). No statistical difference was found between report C-a and C-b in overall satisfaction degree and all three parameters ($p > 0.05$). The rate of urologist-radiologist recalls for reports A, B, C-a and C-b were 29.1%, 10.8%, 18.1% and 11.2%, respectively.

Conclusion: Structured reports, either using TNM or PI-RADS are highly preferred over conventional free-text reports and lead to fewer report-related post-hoc inquiries from urologists.

Keywords: *Magnetic resonance imaging; Prostate cancer; Radiology report; Prostate imaging reporting and data system; TNM staging system*

INTRODUCTION

MRI has been used for noninvasive evaluation of prostate lesions and invasion of surrounding structures since the 1980s (1). As technology advances, MRI can provide much valuable information on prostate lesions and invaded surrounding structures, and has been considered the

optimal imaging technique in the diagnosis of prostate cancer (PCa) (2, 3). However, compared with dramatic evolution of imaging technologies, prostate MRI reporting has progressed slowly (4, 5).

Radiology report is the most significant vehicle of communication between radiologists and clinicians. Qualified prostate MRI reports, providing comprehensive

Received: November 3, 2019 **Revised:** April 18, 2020 **Accepted:** May 6, 2020

This work was supported by the National Natural Science Foundation of China (grant numbers 81370039, 81220108011).

Corresponding author: Jing Ren, MD, PhD, Department of Radiology, Xijing Hospital, Fourth Military Medical University, Changle West Road 127, Xi'an 710032, China.

• E-mail: jrenmm@126.com

This is an Open Access article distributed under the terms of the Creative Commons Attribution Non-Commercial License (<https://creativecommons.org/licenses/by-nc/4.0>) which permits unrestricted non-commercial use, distribution, and reproduction in any medium, provided the original work is properly cited.

information on the relevant imaging features in a clear and concise format, are adopted by urologists for further therapeutic decision-making. Nowadays, the standardized MRI report templates of PCa diagnosis have not been comprehensively constructed worldwide. Despite the establishment of Prostate Imaging Reporting and Data System (PI-RADS) (6, 7), there is still no consensus on developing a standardized reporting scheme that can be widely adopted and validated to ensure comparability of research outputs and optimal clinical practice to date. In the absence of standard performance measures for prostate MRI reporting worldwide, a recent white paper from the American College of Radiology recommends that institutions continuously assess and improve their practice using their own performance measures (8); thus, it is necessary to carry out relevant research.

In the department of radiology at our hospital, prostate MRI reports take 1 of 3 basic forms: the conventional free-text report, structured report with tumor-node-metastasis (TNM) staging, and structured report with PI-RADS version 2 (PI-RADS v2) score with/without TNM staging. The former two types of reports have been the main deliverable for radiologists in our department over the years. The latter type of report is a relatively new form of prostate MRI reporting as PI-RADS v2 was first introduced in 2014 (7). Currently, it is not clear which type of prostate MRI report urologists find more satisfactory. The aim of our study is to evaluate the satisfaction degree of urologists for different types of prostate MRI reports, and to compare the structured prostate MRI reports, including reports with TNM staging and reports with PI-RADS v2 score with/without TNM staging, to the conventional free-text report in terms of satisfaction in correctness, practicality, and urologist subjectivity.

MATERIALS AND METHODS

Study Design and Setting

From October 2007 to November 2018, altogether 13 urologists who majored in diagnosing male urinary system disease and performing urologic surgical procedures in our hospital participated in this study.

The study was designed to evaluate the satisfaction degree of urologists for different types of prostate MRI reports, which included conventional free-text report, report with TNM staging, and report with PI-RADS v2 score with/without TNM staging. The latter type of report was

classified into two subtypes: report with PI-RADS v2 score only, and report with PI-RADS v2 score and TNM staging. Urologists were asked to read prostate MRI reports focusing on prostate diseases of the patients each urologist himself/herself was in charge of, and to rate three parameters for each MRI report on a scale of 1 to 5 (1 = low; 2 = below average; 3 = average; 4 = good; and 5 = excellent). The parameters were: 1) consistency between initial conclusion of the prostate MRI report and the final clinical diagnosis (confirmed by clinic and pathology, or long-term follow-up) of the patient (summarized as “correctness”); 2) the capability of the report to provide enough and useful information that helps urologists to diagnose prostate problems, reduce unnecessary prostate needle biopsies, determine treatment options and further monitor response to therapy in clinical practice (summarized as “practicality”); and 3) urologists’ subjective feelings of prostate MRI reports (summarized as “subjectivity”). The reports of the patients who had been lost to follow-up and whose final diagnoses had not been confirmed were excluded.

Prostate MR Images and Reports

Prostate MRI examinations in our hospital were performed on clinical 3T MRI scanners by using a standard protocol: pelvic phased-array coil, axial T1, axial T2-weighted, coronal fat-suppressed T2-weighted, sagittal T2-weighted, axial diffusion-weighted imaging (DWI) ($b = 50, 800, 1000, 1500 \text{ s/mm}^2$), and gadolinium-enhanced T1-weighted imaging. Radiologists read and interpreted prostate MR images, and produced reports by using picture archiving and communication system. Preliminary prostate MRI reports were initially written by the junior and attending radiologists, and subsequently reviewed by abdominal radiology specialists. Then the final reports were generated. There were in total four types of prostate MRI reports in the department of radiology at our hospital: report A, conventional free-text report; report B, structured report with TNM staging; report C-a, structured report with PI-RADS v2 score only; report C-b, structured report with PI-RADS v2 score and TNM staging. Radiologists’ reporting structure and variation were more influenced by personal preference and previous experience. Therefore, the choice of the type of prostate MRI report patients and their urologists was random.

Data Collection and Statistical Analysis

We collected questionnaires on urologist satisfaction to

prostate MRI reports. The number of reports each urologist read and scored was calculated, and the satisfaction score of each report was recorded. The rate of urologist-radiologist recalls (namely the rate of consultations of radiologists by urologists on uncertainties in reports) for each report type was calculated. Kruskal-Wallis H-test followed by Nemenyi test were used to compare discrete variables (urologists' satisfaction parameters for each report type). The discrete variables were expressed as median and interquartile range. A *p* value of less than 0.05 was considered statistical significant. Analyses were performed with SPSS statistical software (version 20.0 for Windows; SPSS, IBM Corp.).

RESULTS

Thirteen urologists read 3362 prostate MRI reports from 1706 patients in total. The number of each type of prostate MRI reports each urologist read and scored is summarized

Table 1. Number of Four Types of Prostate MRI Reports Urologists Read and Scored

	Report A	Report B	Report C-a	Report C-b
Urologist 1	118	56	41	15
Urologist 2	104	88	45	9
Urologist 3	129	91	38	8
Urologist 4	125	47	64	15
Urologist 5	110	82	41	7
Urologist 6	157	46	44	11
Urologist 7	151	65	42	11
Urologist 8	123	70	44	26
Urologist 9	133	66	51	6
Urologist 10	123	85	61	19
Urologist 11	117	73	62	10
Urologist 12	126	70	59	11
Urologist 13	146	60	48	13

Report A: conventional free-text report, report B: structured report with TNM staging, report C-a: structured report with PI-RADS v2 score only, report C-b: structured report with PI-RADS v2 score and TNM staging. PI-RADS v2 = PI-RADS version 2, TNM = tumor-node-metastasis

in Table 1. The number of each type of prostate MRI reports with urologist satisfaction rating of 1–5 is shown in Table 2. The urologists' responses to the questionnaire are shown in Table 3.

Report B and report C, including its two subtypes, had higher rating of satisfaction than report A in overall satisfaction degree, as well as for all three parameters of correctness, practicality and subjectivity (all *p* < 0.05) (Figs. 1, 2). There was a significant difference between report B and report C (*p* < 0.05) (Fig. 1C) in practicality score, but no statistical difference was found in the overall satisfaction degree, correctness, and subjectivity scores (all *p* > 0.05) (Fig. 1A, B, D). In addition, compared with report C-b (*p* > 0.05), report B and C-a (*p* < 0.05) showed

Table 2. Number of Four Types of Prostate MRI Reports with Urologist Satisfaction Rating of 1–5

	Report A	Report B	Report C-a	Report C-b
Correctness				
1	0	0	0	0
2	80	20	10	3
3	612	47	55	9
4	736	333	268	60
5	234	499	307	89
Practicality				
1	0	0	0	0
2	52	19	18	1
3	608	55	82	3
4	872	312	232	66
5	130	513	308	91
Subjectivity				
1	0	0	0	0
2	27	27	12	1
3	849	44	26	7
4	597	294	173	57
5	189	534	429	96

Report A: conventional free-text report, report B: structured report with TNM staging, report C-a: structured report with PI-RADS v2 score only, report C-b: structured report with PI-RADS v2 score and TNM staging.

Table 3. Urologists' Responses to Questionnaire on Four Types of Prostate MRI Reports

	Report A	Report B	Report C-a	Report C-b	<i>P</i>
Satisfaction	4 (3–4) (3.639–3.713)	5 (4–5) (4.443–4.497)	4 (4–5) (4.331–4.394)	5 (4–5) (4.398–4.521)	< 0.001
Correctness	4 (3–4) (3.639–3.713)	5 (4–5) (4.413–4.504)	4 (4–5) (4.308–4.471)	5 (4–5) (4.352–4.567)	< 0.001
Practicality	4 (3–4) (3.618–3.682)	5 (4–5) (4.421–4.513)	4 (4–5) (4.319–4.421)	5 (4–5) (4.361–4.577)	< 0.001
Subjectivity	3 (3–4) (3.536–3.605)	5 (4–5) (4.437–4.533)	4 (4–5) (4.302–4.412)	5 (4–5) (4.330–4.425)	< 0.001

Data are mean (interquartile range) (confidence interval), respectively. Report A: conventional free-text report, report B: structured report with TNM staging, report C-a: structured report with PI-RADS v2 score only, report C-b: structured report with PI-RADS v2 score and TNM staging.

significant differences in overall satisfaction degree and parameters of practicality and subjectivity (Fig. 2A, C, D). In terms of correctness score, neither report C-a nor C-b had statistically significant difference with report B ($p > 0.05$) (Fig. 2B). No statistical difference was found between reports C-a and C-b in overall satisfaction degree and all three parameters (all $p > 0.05$) (Fig. 2).

In addition, the number of urologist-radiologist recalls for each report type was recorded: 483 for report A, 97 for

report B, 116 for report C-a and 18 for report C-b. The rate of urologist-radiologist recalls for each report type were 29.16%, 10.8%, 18.1% and 11.2%, respectively.

Representative cases of prostate MR images and their corresponding report types are shown in Figures 3–5.

DISCUSSION

The radiology report is the most important communication

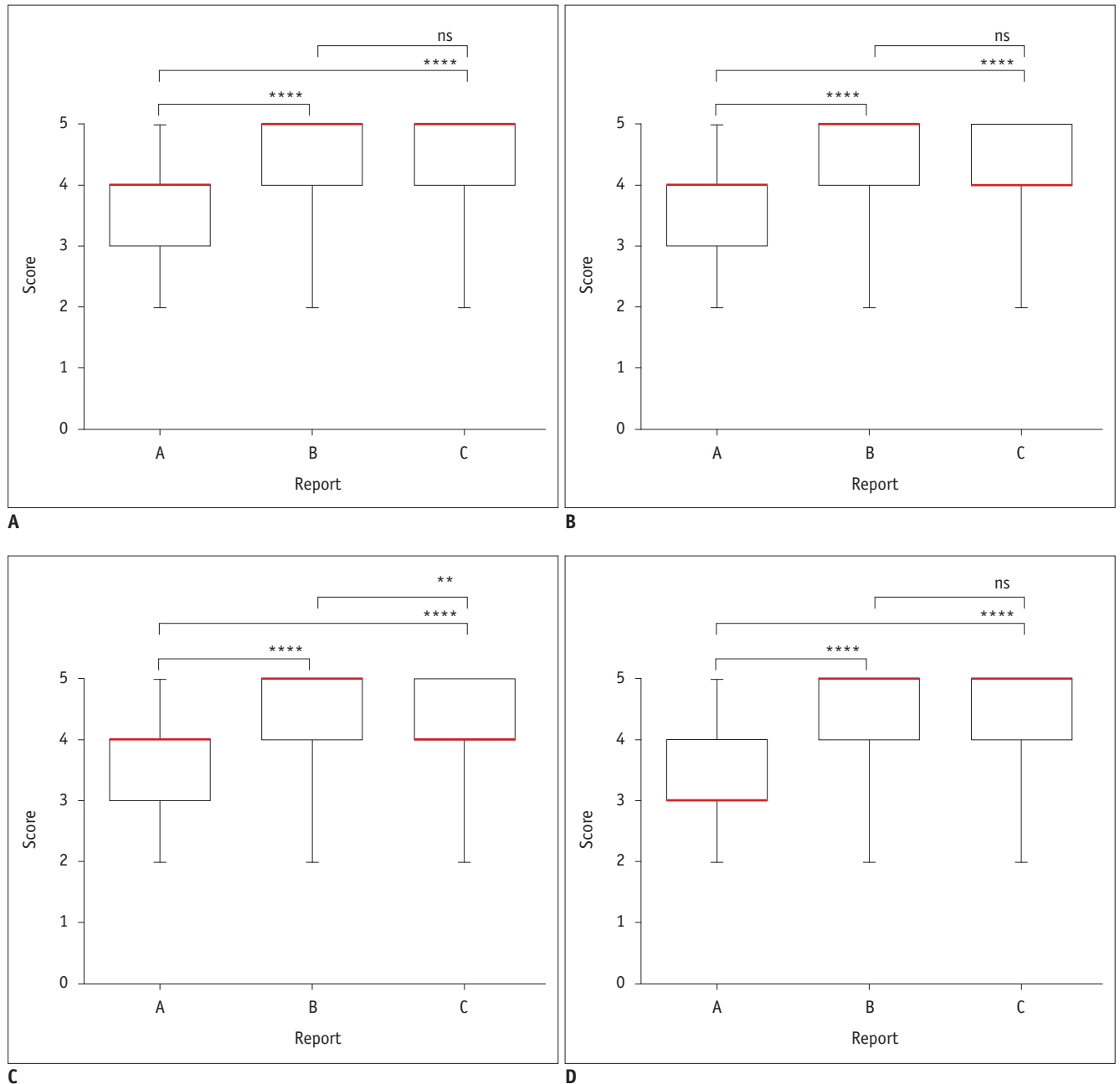


Fig. 1. Vertical column bar graphs comparing urologist satisfaction on prostate MRI reports A, B, and C based on following parameters.

A. Overall satisfaction degree. **B.** Correctness. **C.** Practicality. **D.** Subjectivity. Red line represents median. ** $p < 0.01$, **** $p < 0.0001$.

tool by which radiologists transmit the results of their observations to clinicians. However, wordings with various qualifiers, descriptors, and tongue-in-check language that lack consistency and consensus within reports are often unclear to the clinicians. Clinicians require not only diagnostic accuracy but also language clarity in radiology reports (9, 10), which is needed for standardization of the radiology report. Previous study (11) revealed

interdisciplinary communication and help urologists evaluate the exact location of PCa lesions more accurately, which could provide more accurate assessment of PCa and facilitate treatment planning.

The TNM staging system for PCa, initially introduced in 1992 (12), plays an essential role in accurately reflecting the total cancer burden, evaluating the extent of spread at the time of diagnosis, and stratifying patients into

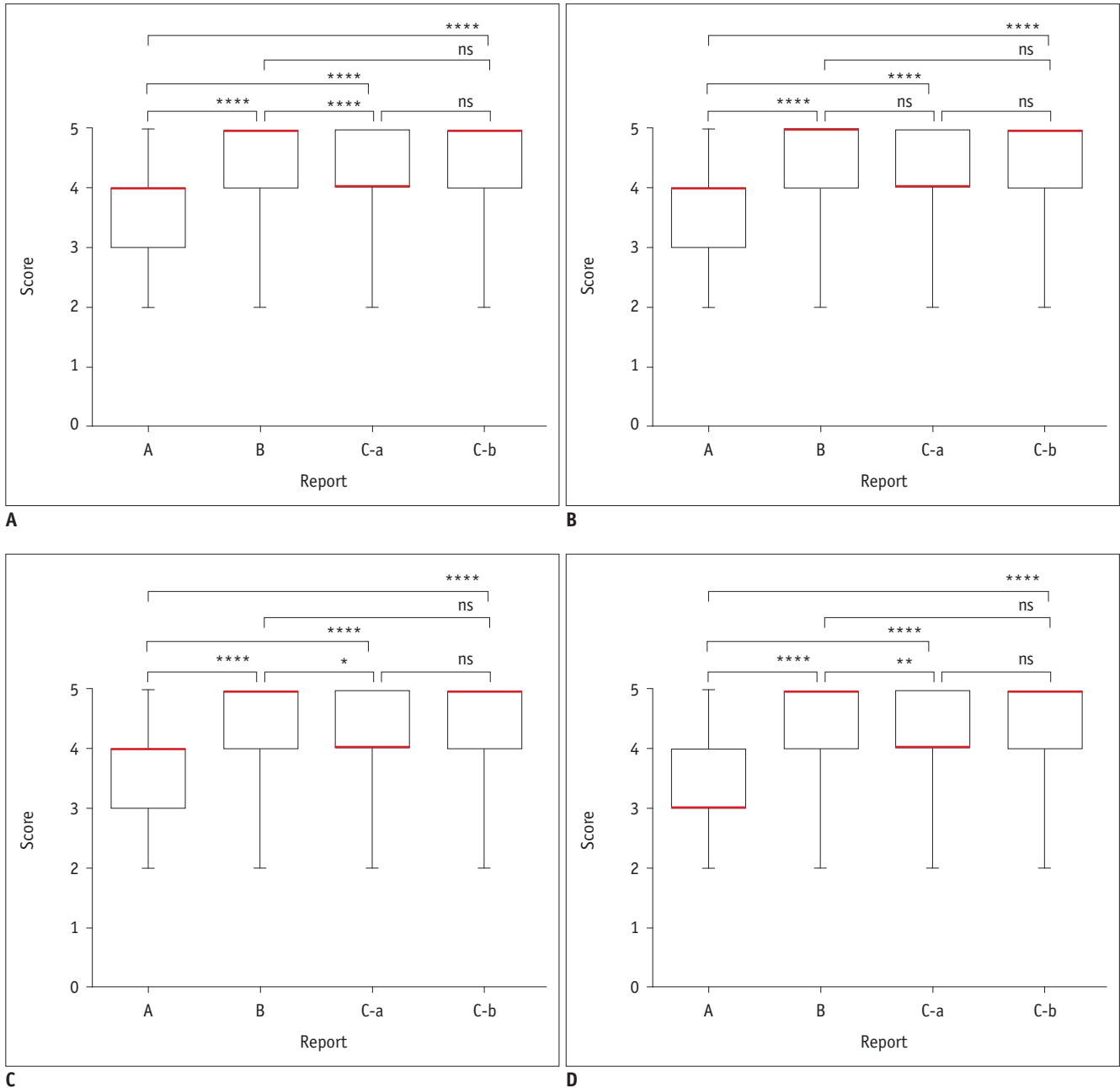


Fig. 2. Vertical column bar graphs comparing urologist satisfaction on prostate MRI reports A and B, and two subtypes of report C (report C-a, report C-b) based on following parameters. A. Overall satisfaction degree. B. Correctness. C. Practicality. D. Subjectivity. Red line represents median. * $p < 0.5$, ** $p < 0.01$, * $p < 0.0001$.**

Moreover, the TNM staging system standardizes terminology and diagnostic criteria, which serve to increase radiology reports completeness and effectiveness, and further allow communication of diagnostic results between different departments and institutions. It has been the most widely used staging system at present (13). In our study, besides

report C, urologists were generally more satisfied with report B, the structured report with TNM staging, compared with report A, which demonstrated that prostate MRI report added to TNM staging could provide useful staging information for clinical decision-making and improve communication of diagnostic results between radiologists

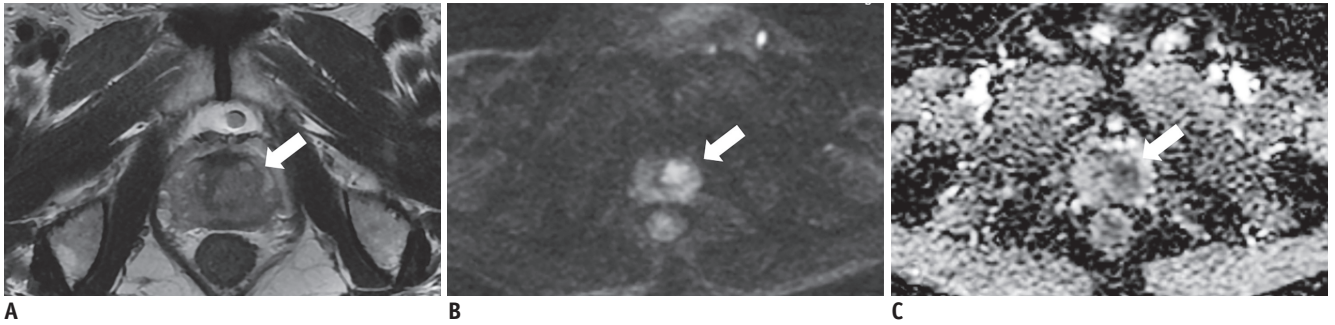


Fig. 3. MRI report of this case was generated on free text basis of report A.

Findings: T2WI (A) shows focal lesion of intermediate signal intensity measuring 0.9 x 0.8 x 1.0 cm in left central zone (white arrow). DWI (B) and ADC map (C) show focal area with restricted diffusion at same site (white arrows). Seminal vesicle was normal. Urinary bladder and adjacent rectum were normal. There was no swollen lymph node in pelvic cavity. Impression: probably PCa and recommended for biopsy. ADC = apparent diffusion coefficient, DWI = diffusion-weighted imaging, PCa = prostate cancer

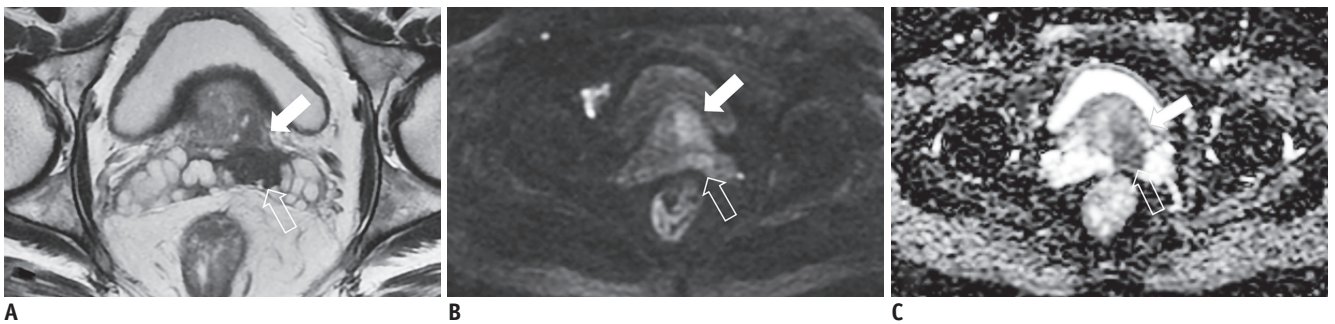


Fig. 4. MRI report of this case was generated in structured format of report B.

Findings: T2WI (A) shows multifocal lesions of intermediate signal intensity measuring 3.2 x 4.0 x 3.7 cm in left central zone and left peripheral zone (white arrow) with seminal vesicles invasion (open arrow). DWI (B) and ADC map (C) show lesions with restricted diffusion at same site (white arrows). Infiltration of neurovascular bundle and seminal vesicles: seminal vesicles invasion (open arrows). Lymph node metastasis: no. Bone metastasis: acetabulum of right hip bone (not shown). Impression: PCa. TNM Staging: T3bN0M1b.

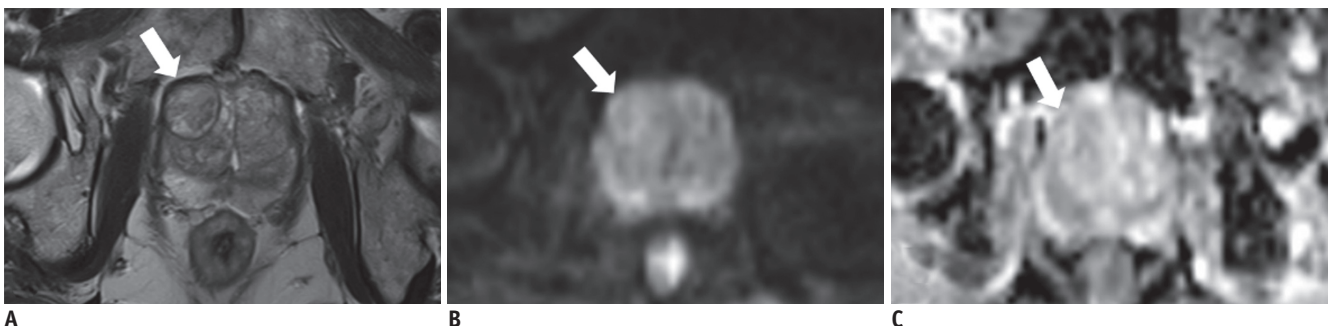


Fig. 5. MRI report of this case was generated in structured format of report C-a.

Findings: prostate gland is enlarged. Size of prostate gland is 6.1 x 5.3 x 5.1 cm. T2WI (A) shows well-defined, round, encapsulated nodule in right central zone with heterogeneous signal intensity (white arrow). Size of nodule is 2.2 x 2.0 x 2.2 cm. DWI (B) and ADC map (C) shows no restricted diffusion at same site (white arrows). Infiltration of neurovascular bundle and seminal vesicles: no. Lymph node metastasis: no. Bone metastasis: no. Impression: benign prostatic hyperplasia (PI-RADS version 2 category: 2).

and urologists.

PI-RADS v2 is designed to promote global standardization and diminish variation in the acquisition, interpretation and reporting of prostate multi-parametric MRI examination (7). It promotes the use of standard terminology for both radiologists and urologists, and improves the detection of clinically significant PCas, which helps urologists to make an accurate diagnosis and determine an appropriate treatment plan, reducing unnecessary needle biopsy (14, 15).

In this study, we evaluated urologists' feedback on different types of MRI reports. Report A has a higher rate of urologist-radiologist recalls than report B, and report C, including its two subtypes. On satisfaction assessment, report B, and report C including its two subtypes have significant advantages over report A for the overall satisfaction and satisfaction degree in all parameters, which allows urologists to diagnose prostate problems and further to determine the effective treatment plan in an explicit way. Furthermore, the results of the present study show that report B provides similar performance with report C in terms of the overall satisfaction as well as satisfaction degree in the correctness and subjective feeling of urologists, and has advantages in terms of the practicality. Moreover, when compared with the subtypes of report C, report B has advantages in the overall satisfaction and satisfaction degree in practicality and subjective feeling of urologists compared with report C-a, and shows a similar performance with report C-b, regarding the overall satisfaction and satisfaction degree of all parameters. This may be due to the fact that prostate MRI reports with TNM staging are from re-visiting patients with clinically confirmed PCa or first-visit patients with increased prostate specific antigen level and typical features of PCa in MR images that can be diagnosed with confidence; these prostate MRI reports provide relatively accurate diagnosis including not only the size and invasion range of the primary tumor but metastasis of lymph nodes and other organs, thus increasing urologists' confidence and satisfaction in determining treatment options. Therefore, the addition of PI-RADS score, based on the likelihood of the presence of a clinically significant cancer, may not add further significant information.

Consensus has been reached that standardization of reporting of prostate MRI is essential to ensure high diagnostic quality, reproducible MRI results, and applicability of prostate MRI across institutions (16). TNM staging system, aiming to keep the highest level of

accuracy and confidence for clinical practice, allows MRI data to be translated into a detailed description of local lesions, regional lymph nodes and distant metastasis, and will help in the selection of appropriate initial therapies. In addition, PI-RADS v2 uses a 5-point Likert Scale based on the probability that a combination of multiparametric MRI findings on T2WI, DWI, and dynamic contrast enhancement correlates with the presence of a clinically significant cancer for each lesion in the prostate gland. PI-RADS v2 aims to improve detection of clinically significant cancer, and increase confidence in differentiating malignancies from benign diseases, which is of significance for reducing unnecessary biopsy and treatment. All three types of structured prostate MRI reports can add urologist satisfaction allowing some advantages over the conventional free-text prostate MRI report by improving and standardizing communication between radiologists and urologists, and optimize patient management.

The conventional free-text reports are easy to cause radiologist-urologist drift for lack of standardization, although it may customize the format and content of a specific case and provide more descriptive information helping urologists understand the case better. There are unavoidably common subjective words or phrases in the conventional free-text report, which are used without formal consensus even among radiologists. The fundamental importance of a radiology report is to convey the interpretation of the medical images and overall impression or opinion of the radiologist given the clinical context. Avoiding confusion and obscurity should remain a priority over stylistic preference (17, 18). Both the radiologist and urologist must understand the meaning behind specific words and phrases in order for information to be accurately passed along. Recently, a survey among radiologists and urologists showed that urologists preferred PI-RADS v2 for prostate MRI reporting and more strongly preferred a structured report (19). Data from our survey also support this view.

The present study has several limitations. Firstly, this is a single-center study. Secondly, the number of urologists participating in the study is limited. Therefore, further multi-centric and comparative studies with a larger number of urologists are needed to confirm our preliminary results. Finally, our study included prostate MRI reports ranging from 2007 to 2018. During this period, prostate MRI reports and its related technicalities, training and expertise have been improved dramatically. In such a long span of time, any changes in evaluation standard will lead to a significant

bias. However, this is not taken into account making our study inadequate, raising the need of improvement.

In conclusion, both structured prostate MRI reports including reports with TNM staging and reports with PI-RADS v2 score with/without TNM staging show a good performance and add urologist satisfaction, having some advantages over the conventional free-text report. In addition, PI-RADS score may not be necessary when TNM staging already appears in report. We believe the present study is significant because it provides essential data for radiologists to write prostate MRI reports more effectively. Furthermore, it is beneficial for the improvement of communication between radiologists and urologists.

Conflicts of Interest

The authors have no potential conflicts of interest to disclose.

Acknowledgments

The authors thank the National Natural Science Foundation of China (Grants NSFC 81370039, NSFC 81220108011) for providing grant support. The authors are grateful for using the facilities of the Medical Imaging Research Center in the department of Radiology of our hospital.

ORCID iDs

Jing Ren

<https://orcid.org/0000-0003-1317-1696>

Jinman Zhong

<https://orcid.org/0000-0003-4089-6895>

REFERENCES

- Poon PY, McCallum RW, Henkelman MM, Bronskill MJ, Sutcliffe SB, Jewett MA, et al. Magnetic resonance imaging of the prostate. *Radiology* 1985;154:143-149
- Lee DJ, Ahmed HU, Moore CM, Emberton M, Ehdiaie B. Multiparametric magnetic resonance imaging in the management and diagnosis of prostate cancer: current applications and strategies. *Curr Urol Rep* 2014;15:390
- Hegde JV, Chen MH, Mulhern RV, Fennessy FM, D'Amico AV, Tempny CM. Preoperative 3-Tesla multiparametric endorectal magnetic resonance imaging findings and the odds of upgrading and upstaging at radical prostatectomy in men with clinically localized prostate cancer. *Int J Radiat Oncol Biol Phys* 2013;85:e101-e107
- Gupta RT, Kauffman CR, Polascik TJ, Taneja SS, Rosenkrantz AB. The state of prostate MRI in 2013. *Oncology (Williston Park)* 2013;27:262-270
- Dickinson L, Ahmed HU, Allen C, Barentsz JO, Carey B, Futterer JJ, et al. Clinical applications of multiparametric MRI within the prostate cancer diagnostic pathway. *Urol Oncol* 2013;31:281-284
- Barentsz JO, Richenberg J, Clements R, Choyke P, Verma S, Villeirs G, et al. ESUR prostate MR guidelines 2012. *Eur Radiol* 2012;22:746-757
- American College of Radiology. PI-RADSTM: Prostate Imaging-Reporting and Data System 2015 version 2. Available at: <https://www.acr.org/-/media/ACR/Files/RADS/Pi-RADS/PIRADS-V2.pdf>. Accessed 14 April, 2015
- Allen B Jr, Levin DC, Brant-Zawadzki M, Lexa FJ, Duszak R Jr. ACR white paper: strategies for radiologists in the era of health care reform and accountable care organizations: a report from the ACR Future Trends Committee. *J Am Coll Radiol* 2011;8:309-317
- McLoughlin RF, So CB, Gray RR, Brandt R. Radiology reports: how much descriptive detail is enough? *AJR Am J Roentgenol* 1995;165:803-806
- Johnson AJ, Ying J, Swan JS, Williams LS, Applegate KE, Littenberg B. Improving the quality of radiology reporting: a physician survey to define the target. *J Am Coll Radiol* 2004;1:497-505
- Wetterauer C, Winkel DJ, Federer-Gsponer JR, Halla A, Subotic S, Deckart A, et al. Structured reporting of prostate magnetic resonance imaging has the potential to improve interdisciplinary communication. *PLoS One* 2019;14:e0212444
- American Joint Committee on Cancer. *AJCC cancer staging manual*, 8th ed. Chicago, IL; American College of Surgeons, 2007
- Cheng L, Montironi R, Bostwick DG, Lopez-Beltran A, Berney DM. Staging of prostate cancer. *Histopathology* 2012;60:87-117
- Park SY, Jung DC, Oh YT, Cho NH, Choi YD, Rha KH, et al. Prostate cancer: PI-RADS version 2 helps preoperatively predict clinically significant cancers. *Radiology* 2016;280:108-116
- Seo JW, Shin SJ, Taik Oh Y, Jung DC, Cho NH, Choi YD, et al. PI-RADS version 2: detection of clinically significant cancer in patients with biopsy gleason score 6 prostate cancer. *AJR Am J Roentgenol* 2017;209:W1-W9
- Tewes S, Mokov N, Hartung D, Schick V, Peters I, Schedl P, et al. Standardized reporting of prostate MRI: comparison of the prostate imaging reporting and data system (PI-RADS) version 1 and version 2. *PLoS One* 2016;11:e0162879
- Wallis A, McCoubrie P. The radiology report--are we getting the message across? *Clin Radiol* 2011;66:1015-1022
- Lee B, Whitehead MT. Radiology reports: what you think you're saying and what they think you're saying. *Curr Probl Diagn Radiol* 2017;46:186-195
- Spilseth B, Ghai S, Patel NU, Taneja SS, Margolis DJ, Rosenkrantz AB. A comparison of radiologists' and urologists' opinions regarding prostate MRI reporting: results from a survey of specialty societies. *AJR Am J Roentgenol* 2018;210:101-107