

Intra-articular calcifications of the temporomandibular joint and associations with degenerative bone alterations

Daniela de Almeida¹, Patrícia Schmidt Araujo Passos de Souza², Luana Pereira de Mendonça¹, Francielle Silvestre Verner³, Karina Lopes Devito^{4,*}

¹Postgraduate Program in Dentistry, School of Dentistry, Federal University of Juiz de Fora, Juiz de Fora, MG, Brazil

²School of Dentistry, Federal University of Juiz de Fora, Juiz de Fora, MG, Brazil

³Department of Dentistry, Federal University of Juiz de Fora, Governador Valadares, MG, Brazil

⁴Department of Dental Clinic, School of Dentistry, Federal University of Juiz de Fora, Juiz de Fora, MG, Brazil

ABSTRACT

Purpose: The purpose of this study was to use cone-beam computed tomography (CBCT) images to determine the prevalence of calcifications in the temporomandibular joint (TMJ) and to evaluate any associations between the presence of such calcifications and degenerative bone alterations of the TMJ, sex, or age.

Materials and Methods: In this retrospective study, 1,058 CBCT exams were analyzed, and data regarding the presence and quantity of calcifications, the affected side, any degenerative alterations of the condyle, sex, and age were collected. To evaluate associations between the presence of calcifications and sex or age, the Fisher exact test or the Spearman correlation coefficient, respectively, was used. To assess the association between the presence of calcifications and joint bone alterations, the chi-square and Fisher exact tests were used. The significance level adopted was 5% ($P < 0.05$).

Results: Twenty-eight patients (2.7%) presented with TMJ calcifications, including 23 women (82.1%) and 5 men (17.9%). Significant correlations were found between the presence of calcifications and age ($P < 0.05$) and between the presence of calcifications and the presence of condylar alterations ($P < 0.05$), with 73.2% of patients with bone alterations having TMJ calcifications.

Conclusion: It may be concluded that, although rare (with a prevalence of only 2.7%), intra-articular calcifications are associated with both degenerative bone alterations and age. (*Imaging Sci Dent* 2020; 50: 99-104)

KEY WORDS: Temporomandibular Joint; Joint Diseases; Prevalence; Cone-Beam Computed Tomography

Introduction

Certain alterations of the temporomandibular joint (TMJ) can produce free bodies in the joint space which, when calcified, can be visualized using imaging techniques. The most common calcifications are those of the articular disc. This structure, composed of dense fibrous connective tissue, can undergo structural changes due to functional and age-related factors. Calcification of the disc can result from

functional joint stress, which is a progressive extension of pathological processes (degenerative changes and chronic inflammatory processes) that culminate in the inability of the articular disc to reduce the stress caused by movements along the surfaces of the condylar process of the mandible and the mandibular fossa.¹

A number of pathologies can develop in these joint bodies, including TMJ osteoarthritis, desiccant osteochondritis, synovial chondromatosis, chondrocalcinosis, rheumatoid arthritis, and intracapsular fractures. Some of these conditions can be asymptomatic, while others are associated with unspecific signs and symptoms, such as joint pain, mouth-opening limitations, swelling, crepitation and clicking, and mandibular deviation to the affected side, poten-

Received October 4, 2019; Revised January 9, 2020; Accepted January 27, 2020

*Correspondence to : Prof. Karina Lopes Devito

Department of Dental Clinic, School of Dentistry, Federal University of Juiz de Fora, Campus Universitário, s/n. CEP: 36036-900 - Juiz de Fora, MG, Brazil
Tel) 55-32-2102-3863, E-mail) karina.devito@ufjf.edu.br

Copyright © 2020 by Korean Academy of Oral and Maxillofacial Radiology

This is an Open Access article distributed under the terms of the Creative Commons Attribution Non-Commercial License (<http://creativecommons.org/licenses/by-nc/3.0>) which permits unrestricted non-commercial use, distribution, and reproduction in any medium, provided the original work is properly cited.

Imaging Science in Dentistry · pISSN 2233-7822 eISSN 2233-7830

tially leading to either misdiagnosis or a delay in making the correct diagnosis.²⁻¹² Treatment depends on the signs and symptoms present, and surgical removal of the calcified bodies is usually performed in symptomatic patients.^{5-7,9,13,14}

Imaging examinations play a fundamental role for the visualization of calcified bodies, but even when such bodies are not visible on radiography, pathology caused by calcifications cannot be ruled out, since the bodies may not have been sufficiently calcified when the image was acquired. The most commonly used imaging modalities include computed tomography, magnetic resonance imaging (MRI), and arthroscopy; these techniques both enable calcified bodies to be identified and assist in the differential diagnosis among various TMJ pathologies.^{2,5,6,8,10-12,14}

Although some evidence of an association between the presence of calcifications and degenerative joint alterations has been reported in the literature,^{4,15,16} this relationship requires further clarification. The current literature is limited to case reports or case series, and insufficient scientific evidence is available to assess the association between bone changes and TMJ calcifications. Given the need for a better understanding of this relationship in a study with a sample size large enough for statistical significance, the aim of the present study was to use cone-beam computed tomography (CBCT) images to determine the prevalence of calcifications in a Brazilian population and to evaluate any associations between the presence of these calcifications and TMJ degenerative bone alterations, sex, or age.

Materials and Methods

This cross-sectional retrospective study was approved by the Federal University of Juiz de Fora (UFJF) Research Ethics Committee (opinion number: 2.146.777, 2017). The CBCT records analyzed were obtained from the dental radiology database of the UFJF School of Dentistry in Minas Gerais, Brazil. Only patients with good-quality images that displayed the TMJ region were included in the sample. Patients with a history of traumas, facial fractures, orthognathic surgery, maxillofacial injuries, or craniofacial anomalies were excluded.

All images were acquired using the same CBCT device (i-CAT Next Generation; Imaging Sciences International, Hatfield, PA, USA) with the following acquisition protocol: a peak kilovoltage of 120 kVp, a current of 8 mA, a voxel size of 0.25 mm, and a field of view ranging from 7 cm × 13 cm to 12 cm × 13 cm. All images included were captured with the patient's teeth in maximum intercuspa-

tion.

The images were independently evaluated using i-Cat Vision software (Imaging Sciences International) by 2 calibrated examiners experienced in the use of CBCT imaging. In the calibration process, 10% of the cases were independently evaluated by the 2 examiners. To verify the reproducibility of the method, the levels of intraobserver ($\kappa=0.95$) and interobserver ($\kappa=0.90$) agreement were calculated using the kappa coefficient. As the kappa values were considered excellent, the evaluation of the sample was continued. In cases of disagreement regarding image assessments, the diagnosis was made via consensus between the examiners.

The presence or absence of calcifications was identified via the dynamic assessment of coronal, sagittal, and axial CBCT slices. The images were bilaterally evaluated, and information was additionally collected regarding the sex and age of the patient, the affected side, and the quantity of calcifications (single or multiple).

Regarding degenerative bone alterations, the bone surfaces of each TMJ condylar process of the mandible were classified as healthy (no alterations), flattened (exhibiting loss of round shape), eroded (exhibiting loss of bone continuity), osteophyte-containing (displaying exophytic formation on the surface), or sclerotic (displaying any increased thickness of the cortical bone in load-supporting areas). Each type of bone alteration could be present in isolation or in combination with 1 or more other types.¹⁷ For a given type of bone alteration to be considered present, it had to be observed in at least 2 sequential sagittal slices.

The data were statistically analyzed using SPSS version 21.0 (IBM Corp., Armonk, NY, USA). The significance level adopted was 5% ($P<0.05$). To evaluate the prevalence of intra-articular calcifications, descriptive statistics (absolute and relative frequencies) were applied. To assess the potential associations between the presence of calcifications and sex or age, the Fisher exact test and the Spearman correlation coefficient, respectively, were used. The association between the presence of calcifications and that of joint bone alterations was evaluated using the chi-square and Fisher exact tests.

Results

A total of 1,807 CBCT examination records were evaluated, 749 of which were excluded because the region under study was not displayed. Of the 1,058 patients (78.0% female; 22.0% male) included in the study, 28 (2.7%) exhibited TMJ calcifications.

Of these 28 patients, 23 (82.1%) were women, while only 5 (17.9%) were men. Their ages ranged from 23 to 76 years, with a mean of 54.7 years (standard deviation, 12.5 years). In the majority of cases, the joint was affected bilaterally (21, 75.0%). Table 1 shows the distribution of the cases of TMJ calcifications with regard to sex and affected side.

No significant correlation was observed between the presence of calcifications and sex ($P > 0.05$); however, a significant positive correlation was noted between the presence of calcifications and age ($P < 0.05$; $r_s = 0.27$).

No significant correlations were observed between any of the condylar bone changes and the presence of calcifications ($P > 0.05$; $Q^2 = 1.56$). Nevertheless, across all types of condylar alterations, a significant correlation was observed with the presence of calcifications ($P < 0.05$), with 73.2% of patients with condylar bone changes having TMJ calcifications. No significant correlation was found between the

quantity of calcifications (single or multiple) and the presence of condylar bone alterations ($P > 0.05$).

Fig. 1 includes images of TMJ calcifications identified among the sagittal reconstructions of CBCT images.

Discussion

TMJ calcifications are quite rare.¹⁸⁻²² It is much more common to find calcified bodies in other joints, such as the elbow, knee, shoulder, or hip.^{18,19,21} In the present study, fewer than 3.0% of the evaluated subjects exhibited visible TMJ calcifications on CBCT scans.

A number of joint conditions can lead to the presence of TMJ calcifications. According to Abuabara et al.,⁶ if free bodies are found in the joint, synovial chondromatosis should be the first diagnostic hypothesis. Chondromatosis is a cartilaginous metaplasia of the remaining mesenchyme of synovial joint tissues. Its main feature is the formation of

Table 1. Distribution of temporomandibular joint calcification cases by sex and affected side

	Unilateral			Bilateral	Total
	Right	Left	Total		
Female	2 (7.1%)	3 (10.7%)	5 (17.9%)	18 (64.3%)	23 (82.1%)
Male	1 (3.6%)	1 (3.6%)	2 (7.1%)	3 (10.7%)	5 (17.9%)
Total	3 (10.7%)	4 (14.3%)	7 (25.0%)	21 (75.0%)	28 (100.0%)

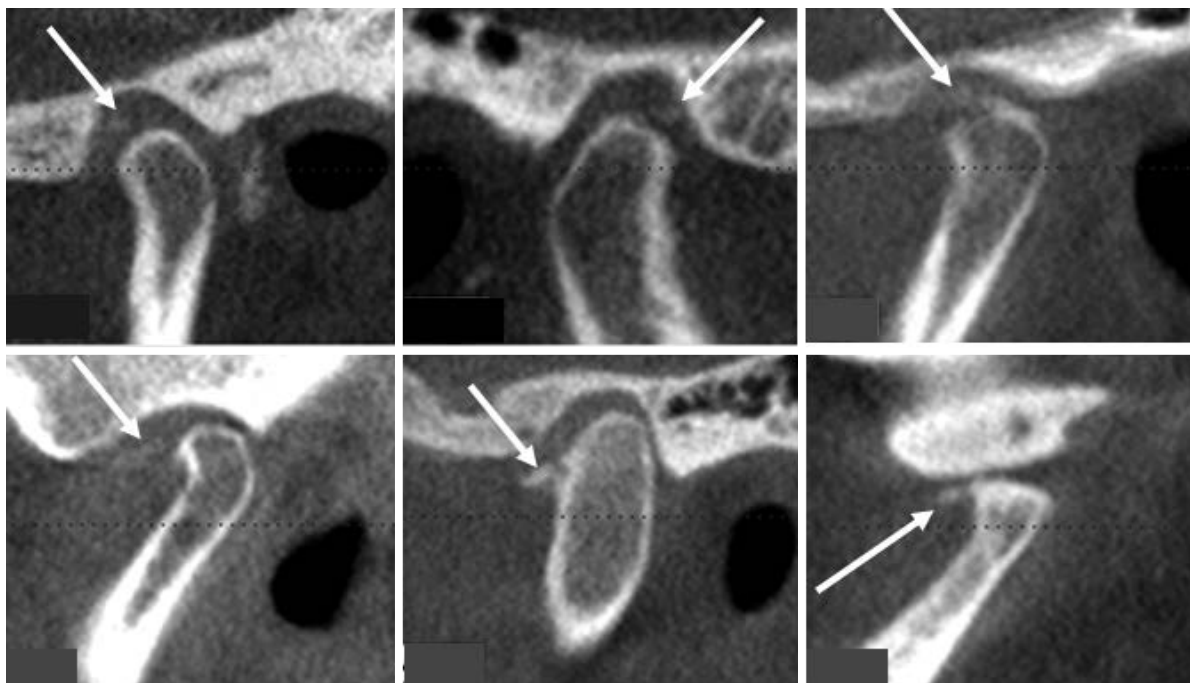


Fig. 1. Sagittal reconstructed cone-beam computed tomographic images show calcification of the temporomandibular joint (white arrows).

cartilaginous nodules in the joint space, and its etiology is still unknown.^{2,6,9,12,13,23} A second diagnostic hypothesis is desiccant osteochondritis, which is characterized by degenerated bone fragments present in the joint space, especially in the condyle, as a consequence of vascular necrosis.²⁴ In rare cases, chondrocalcinosis, also known as calcium pyrophosphate dihydrate crystal deposition disease or pseudogout, can also be present; this condition is a rheumatologic disorder characterized by the precipitation of calcium pyrophosphate in the connective tissues.²⁵ Osteoarthritis, rheumatoid arthritis, and intracapsular fractures must be considered as possible secondary causes of calcified bodies in the TMJ. Some drugs, such as corticosteroids, when administered by intra-articular injection, are also possible causes of heterotopic TMJ calcifications.^{26,27} It is worth noting that the majority of previous studies involving TMJ calcifications were limited to cases of synovial chondromatosis. It was not an aim of the present study to determine the causal factors and/or to diagnose the TMJ calcifications precisely, since the data available were limited to the CBCT images, with no access to any additional information or clinical examination data. Moreover, a definitive diagnosis can only be obtained from histopathological analysis.^{6,7,11-13}

Several studies have pointed out that TMJ calcifications are generally unilateral (affecting only 1 side of the joint) and have a predilection for women aged 40-50 years.^{7,13} In the present study, although no significant correlation was observed between the presence of calcifications and sex, 82.1% of the cases of calcifications were in women. The significant correlation between the presence of calcifications and age is also noteworthy; that is, the older the patient, the higher the chance of having TMJ calcifications. Several studies have reported cases of patients with joint calcifications, the average age of whom was over 45 years.^{19,21,28,29} In the present study, the joint was affected bilaterally in the majority of cases (75.0%); this contrasts with data presented in the literature.

Changes to the TMJ structure occur when the dynamic balance between destruction and bone repair is compromised, potentially resulting in disc displacement and degeneration of bone structures.^{30,31} The mandibular condyle is the most seriously affected structure, and its surfaces may be shown to be flattened (exhibiting loss of round shape); eroded (loss of the bone continuity), osteophyte-containing (displaying exophytic formation on the surface), sclerotic (displaying any increased thickness of the cortical bone in load-supporting areas), or containing subchondral pseudocysts (which arise from the extrusion of joint fluid through the fissures in the hyaline carti-

lage to the marrow).^{17,30,31} The progression and severity of these degenerative TMJ changes are directly related to age. In addition, women are more commonly affected than men.³¹

Few studies have established an association between articular bone changes and TMJ calcifications, and those studies were limited to cases of synovial chondromatosis. Furthermore, none of the studies referenced in the present article have statistically evaluated this association, as the data in those studies included only those presented in case reports. Ida et al.⁴ described the MRI exams of 14 patients, pointing out features of the articular disc, the condyle position, the form and signal intensity of the joint spaces, and any bone alterations in the adjacent structures. The authors observed that the calcifications of the upper joint space showed many manifestations of bone alteration (erosion, flattening, osteophytes, sclerosis, and pseudocysts) and that the severity of the alterations progressed as long as the symptoms were present. Meng et al.⁷ observed the presence of bone alterations on the joint surfaces, both in the condyle and the mandibular fossae, including sclerosis, flattening, hyperplasia, and erosion. Wang et al.¹⁶ observed a relationship between the site of the injury (the upper or lower joint space) and the localization of bone erosion of the joint (the condyle or mandibular fossae). Signs of destruction of the mandibular fossae have been noted in patients with involvement of the upper joint space, while signs of condylar erosion have been observed only in patients with involvement of the lower joint space. In the present study, 73.2% of patients with condylar bone alterations had TMJ calcifications.

Although MRI is considered the imaging modality of choice for the diagnosis of TMJ pathology,^{28,29} CBCT, which has been widely used in dentistry for various purposes, is the most suitable imaging method for evaluating joint structures and the potential presence of mineralized free bodies.⁶ However, even when such bodies are not visible on a CBCT examination, we cannot exclude the possibility of pathology caused by calcifications, as the bodies may not have been sufficiently calcified when the image was acquired.

It may be concluded that, although rare, intra-articular calcifications are associated with degenerative bone alterations and age. Although it is still not possible to draw any inference concerning possible cause-and-effect relationships between intra-joint calcifications and degenerative bone alterations, which should be researched in future longitudinal studies, recognition of this possible association could improve our understanding of joint calcifications,

with resultant favorable impacts on the diagnoses and prognoses of the impacted patients.

Conflicts of Interest: None

References

- Jibiki M, Shimoda S, Nakagawa Y, Kawasaki K, Asada K, Ishibashi K. Calcifications of the disc of the temporomandibular joint. *J Oral Pathol Med* 1999; 28: 413-9.
- Koyama J, Ito J, Hayashi T, Kobayashi F. Synovial chondromatosis in the temporomandibular joint complicated by displacement and calcification of the articular disk: report of two cases. *AJNR Am J Neuroradiol* 2001; 22: 1203-6.
- Holmlund AB, Eriksson L, Reinholt FP. Synovial chondromatosis of the temporomandibular joint: clinical, surgical and histological aspects. *Int J Oral Maxillofac Surg* 2003; 32: 143-7.
- Ida M, Yoshitake H, Okoch K, Tetsumura A, Ohbayashi N, Amagasa T, et al. An investigation of magnetic resonance imaging features in 14 patients with synovial chondromatosis of the temporomandibular joint. *Dentomaxillofac Radiol* 2008; 37: 213-9.
- Balasundaram A, Geist JR, Gordon SC, Klasser GD. Radiographic diagnosis of synovial chondromatosis of the temporomandibular joint: a case report. *J Can Dent Assoc* 2009 75: 711-4.
- Abuabara A, Miles DA, Cruz GV, Passeri LA. Radiological study of three cases of loose bodies in the temporomandibular joint. *Braz J Oral Sci* 2010; 9: 133-6.
- Meng J, Guo C, Yi B, Zhao Y, Luo H, Ma X. Clinical and radiologic findings of synovial chondromatosis affecting the temporomandibular joint. *Oral Surg Oral Med Oral Pathol Radiol Endod* 2010; 109: 441-8.
- Lim SW, Jeon SJ, Choi SS, Choi KH. Synovial chondromatosis in the temporomandibular joint: a case with typical imaging features and pathological findings. *Br J Radiol* 2011; 84: e213-6.
- Kahraman AS, Kahraman B, Dogan M, Firat C, Samdanci E, Celik T. Synovial chondromatosis of the temporomandibular joint: radiologic and histopathologic findings. *J Craniofac Surg* 2012; 23: 1211-3.
- Matsumoto K, Sato T, Iwanari S, Kameoka S, Oki H, Komiyama K, et al. The use of arthrography in the diagnosis of temporomandibular joint synovial chondromatosis. *Dentomaxillofac Radiol* 2013; 42: 15388284.
- Valentini V, Arangio P, Egidi S, Capriotti M, Vellone V, Castrechini M, et al. Diagnosis and treatment of synovial chondromatosis of the TMJ: a clinical case. *Ann Stomatol (Roma)* 2014; 4: 269-72.
- Ivask O, Leibur E, Voog-Oras Ü. Synovial chondromatosis in the temporomandibular joint: case report with review of the literature. *Stomatologija* 2015; 17: 97-101.
- Pinto AA Jr, Ferreira e Costa R, de Sousa SF, Chagas MR, do Carmo MA, de Lacerda JC. Synovial chondromatosis of the temporomandibular joint successfully treated by surgery. *Head Neck Pathol* 2015; 9: 525-9.
- Brabyn PJ, Capote A, Muñoz-Guerra MF, Zylberberg I, Rodríguez-Campo FJ, Naval-Gías L. Arthroscopic management of synovial chondromatosis of the temporomandibular joint. Case series and systematic review. *J Maxillofac Oral Surg* 2018; 17: 401-9.
- Chen MJ, Yang C, Cai XY, Jiang B, Qiu YT, Zhang XH. Synovial chondromatosis in the inferior compartment of the temporomandibular joint: different stages with different treatments. *J Oral Maxillofac Surg* 2012; 70: e32-8.
- Wang P, Tian Z, Yang J, Yu Q. Synovial chondromatosis of the temporomandibular joint: MRI findings with pathological comparison. *Dentomaxillofac Radiol* 2012; 41: 110-6.
- Ahmad M, Hollender L, Anderson Q, Kartha K, Ohrbach R, Truelove EL, et al. Research diagnostic criteria for temporomandibular disorders (RDC/TMD): development of image analysis criteria and examiner reliability for image analysis. *Oral Surg Oral Med Oral Pathol Oral Radiol Endod* 2009; 107: 844-60.
- Khanna JN, Ramaswami R. Synovial chondromatosis of the temporomandibular joint with intracranial extension-report of two cases. *Int J Oral Maxillofac Surg* 2017; 46: 1579-83.
- Han WH, Meng JH, Li G, Ma XC. Diagnosis of bilateral calcifications of temporomandibular joint disc by image fusion. *J Craniofac Surg* 2019; 30: e597-8.
- Liu X, Wan S, Shen P, Qiu Y, Sah MK, Abdelrehem A, et al. Diagnostic accuracy of synovial chondromatosis of the temporomandibular joint on magnetic resonance imaging. *PLoS One* 2019; 14: e0209739.
- Maffia F, Vellone V, De Quarto C, Runci Anastasi M, Cascone P. Synovial chondromatosis of the temporomandibular joint with glenoid fossa erosion: Disk preservation for spontaneous anatomical recovery. *J Craniofac Surg* 2019; 47: 1898-902.
- Rennó TA, Chung AC, Gitt HA, Corrêa L, Luz JG. Temporomandibular arthropathies: A retrospective study with histopathological characteristics. *Med Oral Patol Oral Cir Bucal* 2019; 24: e562-70.
- Sozzi D, Bocchialini G, Novelli G, Valente MG, Moltrasio F, Bozzetti A. A rare case of synovial chondromatosis of the inferior TMJ compartment. diagnosis and treatment aspect. *Ann Stomatol (Roma)* 2016; 6: 91-5.
- Campos PS, Freitas CE, Pena N, Gonzalez MO, Almeida SM, Mariz AC, et al. Osteochondritis dissecans of the temporomandibular joint. *Dentomaxillofac Radiol* 2005; 34: 193-7.
- Aoyama S, Kino K, Amagasa T, Kayano T, Ichinose S, Kimijima Y. Differential diagnosis of calcium pyrophosphate dihydrate deposition of the temporomandibular joint. *Br J Oral Maxillofac Surg* 2000; 38: 550-3.
- Stoll ML, Amin D, Powell KK, Poholek CH, Strait RH, Aban I, et al. Risk factors for intraarticular heterotopic bone formation in the temporomandibular joint in juvenile idiopathic arthritis. *J Rheumatol* 2018; 45: 1301-7.
- Ringold S, Thapa M, Shaw EA, Wallace CA. Heterotopic ossification of the temporomandibular joint in juvenile idiopathic arthritis. *J Rheumatol* 2011; 38: 1423-8.
- Benslama L, Schouman T, Toure S, Chardain J, Goudot P. Synovial chondromatosis of the temporomandibular joint: Report and analysis of 12 cases. *J Stomatol Oral Maxillofac Surg* 2019; 120: 476-9.

29. Lee LM, Zhu YM, Zhang DD, Deng YQ, Gu Y. Synovial chondromatosis of the temporomandibular joint: a clinical and arthroscopic study of 16 cases. *J Craniomaxillofac Surg* 2019; 47: 607-10.
30. Cevidanes LH, Hajati AK, Paniagua B, Lim PF, Walker DG, Falconet G, et al. Quantification of condylar resorption in temporomandibular joint osteoarthritis. *Oral Surg Oral Med Oral Pathol Oral Radiol Endod* 2010; 110: 110-7.
31. dos Anjos Pontual ML, Freire JS, Barbosa JM, Frazão MA, dos Anjos Pontual A. Evaluation of bone changes in the temporomandibular joint using cone beam CT. *Dentomaxillofac Radiol* 2012; 41: 24-9.