



Ovarian Artery Rupture Presenting with a Spontaneous Retroperitoneal Hemorrhage of an Anticoagulated Patient: A Successful Treatment with Embolization

항응고치료 환자에서 자발성 후복막강 출혈로 나타난
 난소동맥 파열: 색전술을 이용한 성공적 치료

So Jeong Lee, MD , Min Jeong Choi, MD* ,
 Bong Man Kim, MD , Sang Yoon Kim, MD 

Department of Radiology, Dankook University Hospital, Cheonan, Korea

Retroperitoneal hemorrhage is a potentially lethal complication in patients on anticoagulant therapy and can be caused by ovarian artery bleeding, regardless of the patients' age and obstetric history. This case illustrates the clinical presentation of ovarian artery bleeding in a postmenopausal female on anticoagulant therapy, the diagnostic utility of transcatheter angiography, and successful embolization.

Index terms Rupture, Spontaneous; Hemorrhage; Anticoagulants; Angiography; Endovascular Procedure; Embolization, Therapeutic

INTRODUCTION





Anticoagulant medication is widely used for the prevention and treatment of thromboembolic complications in numerous clinical settings. As the use of anticoagulant medication increases, the incidence of anticoagulant-associated adverse event has also been increased (1). Bleeding is one of the most frequent and potentially fatal complica-

Received January 7, 2020
 Revised March 30, 2020
 Accepted March 31, 2020

*Corresponding author
 Min Jeong Choi, MD
 Department of Radiology,
 Dankook University Hospital,
 119 Dandae-ro, Dongnam-gu,
 Cheonan 31116, Korea.
 Tel 82-41-550-6921
 Fax 82-41-552-9674
 E-mail babiyong@hanmail.net

This is an Open Access article distributed under the terms of the Creative Commons Attribution Non-Commercial License (<https://creativecommons.org/licenses/by-nc/4.0>) which permits unrestricted non-commercial use, distribution, and reproduction in any medium, provided the original work is properly cited.

ORCID iDs

So Jeong Lee 
<https://orcid.org/0000-0002-5673-7365>
 Min Jeong Choi 
<https://orcid.org/0000-0001-8941-3482>
 Bong Man Kim 
<https://orcid.org/0000-0003-3720-9361>
 Sang Yoon Kim 
<https://orcid.org/0000-0001-9951-2505>

tions of anticoagulant medication, which is responsible for a number of hospitalization or mortality (1-3). Retroperitoneal hemorrhage (RPH) is a distinct and a well-known clinical entity that is typically associated with anticoagulant therapy (4). A prior study reported that retroperitoneum is the second most common site where the severe extra-cerebral anticoagulant-related bleeding occurs requiring the management in the intensive care unit (1). Ovarian artery bleeding is a rare etiology of RPH, especially for a female in their postmenopausal stage (5, 6). We hereby report a case of ovarian artery bleeding presenting with a spontaneous RPH, secondary to heparin medication, in which successful treatment was achieved by endovascular embolization with N-butyl-2-cyanoacrylate (NBCA).

CASE REPORT

A 64-year-old female presented with a sudden abdominal and left flank pain 4 hours after undergoing a stent-assisted coil embolization for a cerebral aneurysm in the basilar top. Her past medical history was significant for hypertension, hyperlipidemia and stable angina treated with aspirin and she had taken it until the day before the procedure. The patient was under systemic heparinization during and after the procedure (procedure time: 115 min, heparin dosage: intravenous bolus of 4000 units of unfractionated heparin twice followed by an intravenous heparin infusion of 3000 units) and over the course of the next 4 hours, she had hemodynamic instability. Her blood pressure dropped to 65/53 mm Hg with a heart rate of 93 beats per minute. Her hematocrit value was 30.8% with a hemoglobin level of 10.5g/dL. The patient's activated partial thromboplastin time was 105.1 sec and international normalized ratio was 1.11.

A contrast-enhanced abdominopelvic CT demonstrated a large retroperitoneal space-occupying hematoma with contrast medium extravasation at the inferior portion of left retrorenal space. The hematoma extended to left perirenal space, and pelvic extraperitoneum (Fig. 1A, B).

Her hemodynamic status remained unstable despite intensive medical treatment consisting of stopping the administration of heparin, vigorous volume resuscitation, transfusion (2 units of packed red blood cells, 1 unit of fresh frozen plasma and 1 unit of platelet concentrates), and the administration of vasopressors. Her hematocrit value decreased to 22.6% with a hemoglobin level of 7.6 g/dL. The patient was referred to the interventional unit for an emergent endovascular treatment.

CT images alone were not able to distinguish the bleeding vessels, therefore, angiographies were performed via left renal artery, left renal capsular artery, left lumbar arteries and left ilio-lumbar artery. There was no evidence of active bleeding on the angiographic opacification of these arteries and subsequent aortography was performed with a 5-French pig-tail catheter (Cook Medical Inc., Bloomington, IN, USA). Although it was difficult to identify the culprit artery, aortography discovered the contrast medium extravasation just below the left kidney that was consistent with the CT finding. The culprit artery was catheterized with a 5-French Mickelson catheter (Cook Medical Inc.) and 2.2-French microcatheter (Progreat; Terumo, Tokyo, Japan) with using coaxial technique and the angiography showed contrast medium extravasation from nodular opacification of the left ovarian artery indicating active bleeding

(Fig. 1C). Embolization was performed using NBCA (Histoacryl, B barun, Melsungen, Germany) diluted in iodized oil (Lipiodol, Guerbet, Paris, France). The mixture of NBCA and iodized oil (33% Histoacryl and 67% Lipiodol) was meticulously injected via left ovarian artery to occlude the rupture site, after protecting a branch originating from the proximal portion of the left ovarian artery with microcoil (K3 Fibered platinum coil; 2 mm-2 cm, Kimpo, Ko-

Fig. 1. Spontaneous retroperitoneal hemorrhage caused by ovarian artery aneurysm rupture in a 64-year-old female on anticoagulant therapy.

A, B. Contrast-enhanced abdominopelvic CT reveals left retroperitoneal hematoma with contrast medium extravasation (arrows).

C. Selective angiography shows nodular opacification (arrow) with contrast medium extravasation at the left ovarian artery, indicating active bleeding.

D. Immediate follow-up fluoroscopy after embolization shows the cast formation by the embolic material (arrow) in the left ovarian artery, including the rupture site.

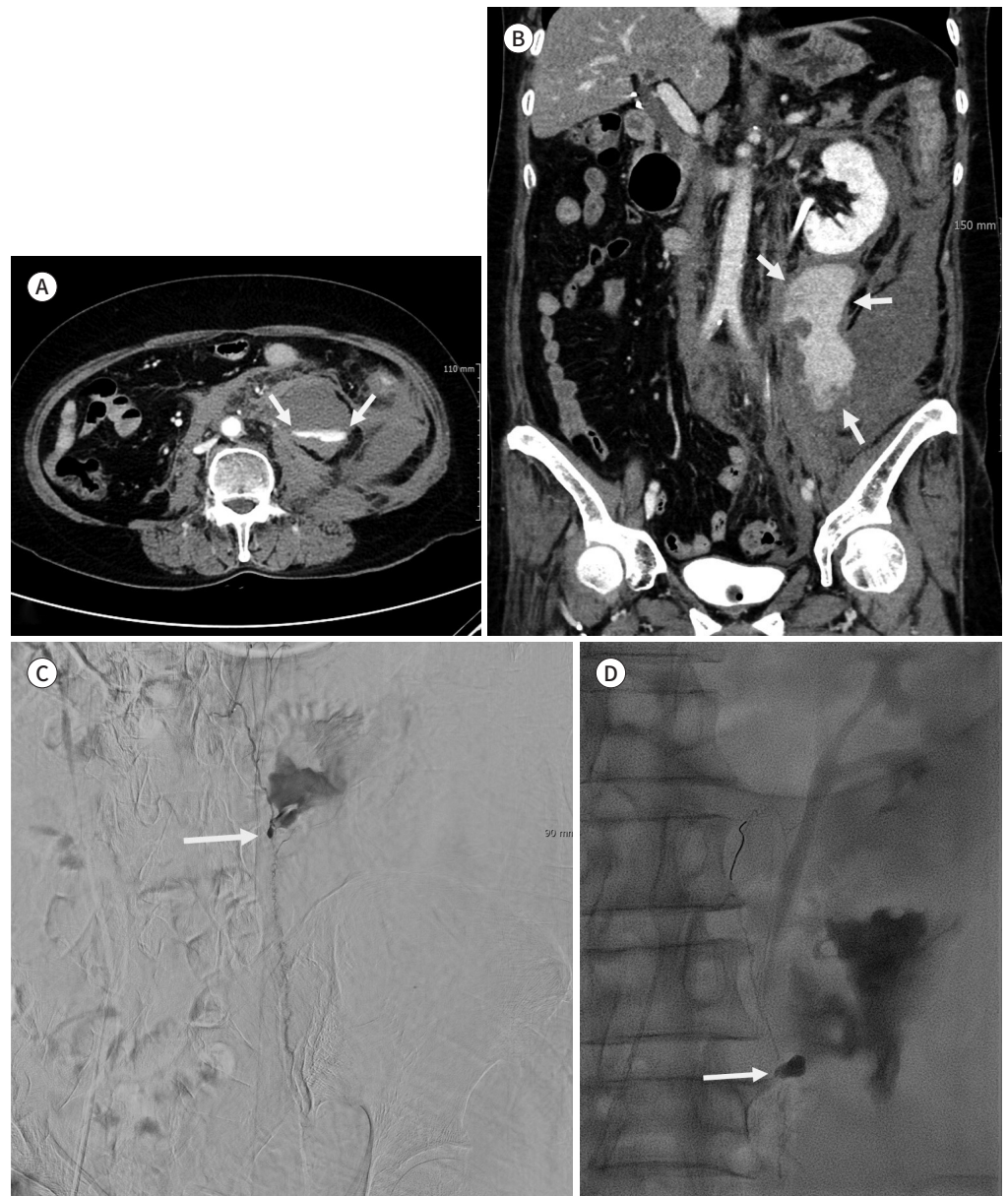
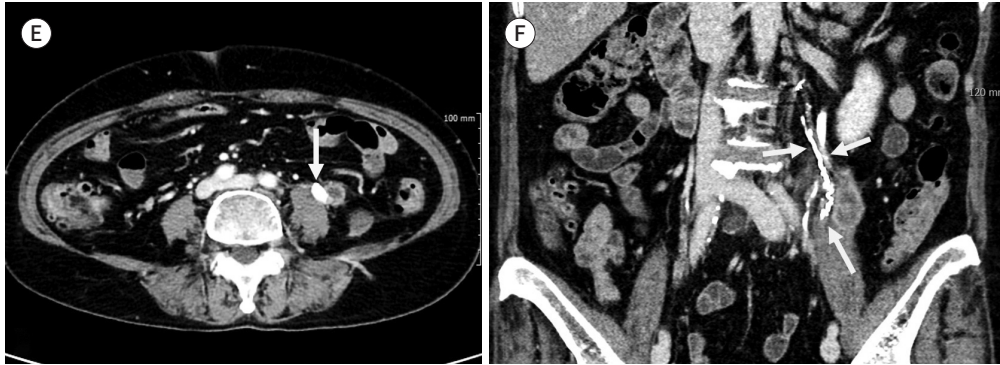


Fig. 1. Spontaneous retroperitoneal hemorrhage caused by ovarian artery aneurysm rupture in a 64-year-old female on anticoagulant therapy.

E, F. Four months after embolization, contrast-enhanced abdominopelvic CT shows regression of the left retroperitoneal hematoma and the embolic material cast (arrows) in the left ovarian artery.



rea). Immediate follow-up fluoroscopy scan demonstrated the cast formation of embolic material (Fig. 1D). Right after the embolization, her blood pressure increased to 133/74 mm Hg. During the hospital day, there was no further decreased hemoglobin level and the original symptoms have improved. The patient went home 13 days after the embolization with no further procedures or operations for the hematoma removal or retroperitoneal decompression. The follow-up CT was performed after 4 months and showed a decreased in size of the retroperitoneal hematoma and the casted embolic material from proximal portion to the rupture site of left ovarian artery (Fig. 1E, F). Until the 1-year clinical follow up, there was not any recognized complications directly attributable to transcatheter angiography and embolization.

DISCUSSION

RPH is rare but with increasing incidence due to complications related anticoagulant medication (2, 4, 7). RPH was reported as the second most common bleeding site according to a study which conducted clinical trials to 100 patients with severe extra-cerebral anticoagulant-related bleeding (1). Another observational study that conducted trials for 89 patients with a final diagnosis of spontaneous RPH found out that two-thirds of the patients were anticoagulated at the time of bleeding (2).

Ovarian artery is a rare site of RPH. It is crucial that prediction and correct identification of bleeding artery facilitates quick and effective hemostasis by endovascular embolization. According to prior studies, bleeding vessels in spontaneous RPH are usually located at muscular and parietal branches rather than visceral branches (3, 4, 7). Isokangas and Perälä (4) reviewed 10 consecutive patients with embolization for RPH which is secondary to the anticoagulant treatment and reported that 18 bleeding sites were confirmed on angiography; 13 lumbar arteries, 2 iliolumbar arteries, 1 inferior gluteal artery, 1 intercostal artery, and 1 medial rectal artery. Farrelly et al. (7) reviewed 25 consecutive patients with spontaneous extraperitoneal hemorrhage referred for endovascular therapy and reported that contrast extravasation was the most commonly identified in the lumbar arteries. There was no ovarian artery discussed

in these studies.

In this case, angiography revealed a nodular opacification with contrast medium extravasation from the ovarian artery suggesting a ruptured (pseudo)aneurysm of the ovarian artery. Ovarian artery aneurysm is a rare entity. Ovarian artery aneurysms are usually related multiparity and their rupture occurs mainly to women in their childbearing age, especially during their peripartum period. It is hypothesized that increased ovarian artery flow due to hormonal and hemodynamic changes during pregnancy could be a mechanism of ovarian artery dilation and subsequent aneurysm formation (5, 6). However, in this case, the patient is a postmenopausal female and her obstetric history includes only one miscarriage without any other pregnancy. Also, her pre-procedural CT did not demonstrate any nodular opacification suggesting (pseudo)aneurysm as well as an ovarian artery itself, unlike the prior reports (5, 6, 8). This case stresses the utility of angiographic exploration that allows a diagnosis of ovarian artery bleeding and eliminates the possibility of other arterial bleeding.

In order to avoid persistent bleeding or rebleeding by retrograde collateral backflow, embolization should be performed for both proximal and distal segment of the rupture site (9). In this case, catheterization of the distal segment with microcatheter was difficult to perform due to hypoplasia and tortuosity of the left ovarian artery. Moreover, it was tough to maintain placing the 5-French mother catheter stably due to the orifice stenosis. When NBCA is adequately diluted, it casts distally to the injection site and allows occlusion of distal vessels (9).

In conclusion, RPH is a potential lethal complication in patients with anticoagulant therapy and can be caused by ovarian artery bleeding rupture regardless of their age and their obstetric history. This case highlights the diagnostic utility of transcatheter angiography for accurate diagnosis and subsequent effective embolization.

Author Contributions

Conceptualization, C.M.J.; investigation, L.S.J., C.M.J.; project administration, L.S.J., C.M.J.; resources, C.M.J., K.B.M., K.S.Y.; supervision, C.M.J.; visualization, L.S.J., C.M.J., K.B.M.; writing—original draft, L.S.J., C.M.J.; and writing—review & editing, C.M.J., K.B.M., K.S.Y.

Conflicts of Interest

The authors have no potential conflicts of interest to disclose.

REFERENCES

1. Hauguel M, Boelle P, Pichereau C, Bourcier S, Bigé N, Baudel JL, et al. Severe extra-cerebral anticoagulant-related bleeding in intensive care unit: a retrospective study from 2000 to 2013. *Medicine (Baltimore)* 2015;94:e2161
2. Sunga KL, Bellolio MF, Gilmore RM, Cabrera D. Spontaneous retroperitoneal hematoma: etiology, characteristics, management, and outcome. *J Emerg Med* 2012;43:e157-e161
3. Park SH, Lee SW, Jeon U, Jeon MH, Lee SJ, Shin WY, et al. Transcatheter arterial embolization as treatment for a life-threatening retroperitoneal hemorrhage complicating heparin therapy. *Korean J Intern Med* 2011;26:352-355
4. Isokangas JM, Perälä JM. Endovascular embolization of spontaneous retroperitoneal hemorrhage secondary to anticoagulant treatment. *Cardiovasc Intervent Radiol* 2014;27:607-611
5. García-Alva R, Guerrero-Hernández M, Anaya-Ayala JE, Leal-Anaya P, Gabutti A, Picazo A, et al. Successful embolization of a ruptured ovarian artery aneurysm in a postmenopausal woman: case report and literature review of gonadal artery aneurysms. *Vasc Endovascular Surg* 2018;52:159-163

6. Zorrilla AM, Fein LA, James K, Alhman PP, Mohan PP, Pastor Carvajal SM. Retroperitoneal hematoma secondary to spontaneous rupture of ovarian artery pseudoaneurysms: case report and review of literature. *J Obstet Gynaecol* 2019;39:422-424
7. Farrelly C, Fidelman N, Durack JC, Hagiwara E, Kerlan RK Jr. Transcatheter arterial embolization of spontaneous life-threatening extraperitoneal hemorrhage. *J Vasc Interv Radiol* 2011;22:1396-1402
8. Toyoshima M, Kudo T, Igeta S, Makino H, Momono Y, Shima T, et al. Spontaneous retroperitoneal hemorrhage caused by rupture of an ovarian artery aneurysm: a case report and review of the literature. *J Med Case Rep* 2015;9:84
9. Madhusudhan KS, Venkatesh HA, Gamanagatti S, Garg P, Srivastava DN. Interventional radiology in the management of visceral artery pseudoaneurysms: a review of techniques and embolic materials. *Korean J Radiol* 2016;17:351-363

항응고치료 환자에서 자발성 후복막강 출혈로 나타난 난소동맥 파열: 색전술을 이용한 성공적 치료

이소정 · 최민정* · 김봉만 · 김상윤

후복막강 출혈은 항응고 치료의 치명적 합병증일 수 있으며, 나이 및 산과력과 상관없이 난소동맥이 출혈 병소일 수 있다. 저자들은 폐경기 여성에서 항응고 치료 중에 발생한 난소동맥 출혈을 경도관 혈관조영술 및 색전술을 통해 정확한 진단 및 효과적인 지혈이 가능했던 증례를 소개하고자 한다.

단국대학교병원 영상의학과