



# Infected Sclerosing Lipogranuloma after Hernioplasty: Ultrasonographic and MRI Findings

탈장성형술 후 음낭 내에 발생한 감염성 경화지방육아종의 초음파 및 자기공명영상 소견: 증례 보고

Jong Soo Park, MD , Jae Ho Cho, MD\* 

Department of Radiology, College of Medicine, Yeungnam University, Daegu, Korea

We report the ultrasonographic and MRI findings of an infected sclerosing lipogranuloma after scrotal hernioplasty. Sclerosing lipogranuloma is a rare foreign-body reaction of fat tissue, with most cases being associated with the genital and urinary tracts. To the best of our knowledge, MRI findings in sclerosing lipogranuloma in the scrotal sac have not yet been published and this is possibly the first study to report the case of an infected sclerosing lipogranuloma in the English literature.

**Index terms** Granuloma; Scrotum; Hernioplasty; Ultrasonography; Magnetic Resonance Imaging

## INTRODUCTION

Smetana and Barnhard (1) first described “sclerosing lipogranuloma” in 1948 to describe a foreign body reaction of fat tissue resulting from injury. Most cases are caused by injected exogenous foreign bodies, such as silicone, paraffin, and oil, into the penis (1-3). Sclerosing lipogranuloma without foreign body injection or a history of trauma is rare (4). Sclerosing lipogranuloma in the scrotum has been reported in < 0.4% of all cases involving male genitalia (5). We report a case of infected sclerosing lipogranuloma in scrotal sac after hernioplasty and provide details of the ultrasonographic (USG) and MRI findings.

Received January 15, 2019  
Revised October 4, 2019  
Accepted October 18, 2019

**\*Corresponding author**

Jae Ho Cho, MD  
Department of Radiology,  
College of Medicine,  
Yeungnam University,  
170 Hyeonchung-ro,  
Nam-gu, Daegu 42415, Korea.

Tel 82-53-620-3026

Fax 82-53-653-5484

E-mail jongsoo8393@naver.com


This is an Open Access article distributed under the terms of the Creative Commons Attribution Non-Commercial License (<https://creativecommons.org/licenses/by-nc/4.0>) which permits unrestricted non-commercial use, distribution, and reproduction in any medium, provided the original work is properly cited.

**ORCID iDs**

Jong Soo Park 

<https://>

[orcid.org/0000-0001-7204-6700](https://orcid.org/0000-0001-7204-6700)

Jae Ho Cho 

<https://>

[orcid.org/0000-0002-1195-1296](https://orcid.org/0000-0002-1195-1296)

## CASE REPORT

A 10-years-old male visited the pediatric division of the general surgery department in our hospital due to right scrotal swelling of several years duration. Testicular USG was performed using an iU20 system (Philips Medical Systems, Best, the Netherlands) with a 5–12 MHz transducer. On USG, an indirect inguinal hernia of intra-peritoneal fat tissue was noted. The symptoms persisted, so hernioplasty was performed. Intraoperatively, a 2 cm × 2 cm × 3 cm sized hernial sac was noted in the scrotum at the antero-medial aspect of the right testis, containing incarcerated omentum. The sac was dissected from adjacent tissue and reduced up to the internal inguinal ring and then double sutures were placed.

After 2 months, the patient visited the urology department due to right scrotal pain and fever (temperature, 38°C) of 3 days duration. On physical exam, the right scrotum was swollen, with erythema and tenderness. Laboratory investigations showed elevated C-reactive protein and erythrocyte sedimentation rate levels (4.59 mg/L and 78 mm/h, respectively).

On USG, diffuse thickening of the scrotal covering was noted. A 6 cm × 5 cm × 3.5 cm sized, multi-septate fluid collection extending to the processus vaginalis was noted in the tunica sac, displacing testis to the periphery (Fig. 1A). A 3.5 cm × 3.5 cm × 3 cm sized, lobulated, hyperechoic mass-like lesion with posterior acoustic shadowing was seen within the multi-septate fluid collection. The mass-like lesion showed no increased vascularity on color Doppler imaging (Fig. 1B), suggesting right infected hydrocele with mass-like lesion.

For further evaluation of the lesion, we performed testicular MRI using a 1.5 Tesla, MRI scanner (Intera 1.5T, Philips Medical Systems). We obtained coronal T1-, coronal and axial T2-weighted images, coronal T1-weighted short tau inversion recovery (STIR) images, and coronal and axial contrast-enhanced T1-weighted images.

The MRI showed an oligolocular cystic lesion with thick enhancing wall in the tunica sac, suggesting infected hydrocele. The right testis was inferiorly displaced. The mass-like lesion within the infected hydrocele showed higher signal intensity than muscle on T1- and T2-weighted images and low signal intensity on STIR and fat suppressed enhanced T1 coronal images without significant enhancement, which is suggested that the lesion showed fat suppression (Fig. 1C-F). Because of the presence of fat tissue and patient's previous history, we considered the possibility of a remnant omental fatty tissue with infected hydrocele.

On USG taken two months after antibiotic treatment, the lesion we considered an infected hydrocele had disappeared, but the echogenic mass considered a remnant of omental fat showed no significant change. Therefore, surgical removal of the fatty tissue in right scrotum was performed.

Intraoperatively, a 3.5 cm × 3.5 cm × 3 cm sized yellowish mass was seen within a 5 cm hydrocele. The hydrocele sac was dissected from adherent tissue and removed.

On gross examination, the lesion was a round, yellowish, solid mass. Histopathological examination showed fibrosclerosis, fat globules, granuloma composed of epithelioid cells and multinucleated giant cells, and inflammatory infiltrate comprised of lymphocytes, macrophages, and eosinophils, providing a final, definitive diagnosis of sclerosing lipogranuloma.

**Fig. 1.** Radiologic findings of infected sclerosing lipogranuloma (arrows) in a 10-year-old boy.

**A.** Longitudinal gray scale sonogram shows a lobulated, hyperechoic mass with posterior acoustic shadowing within a multi-septate fluid collection and peripherally displaced testicle.

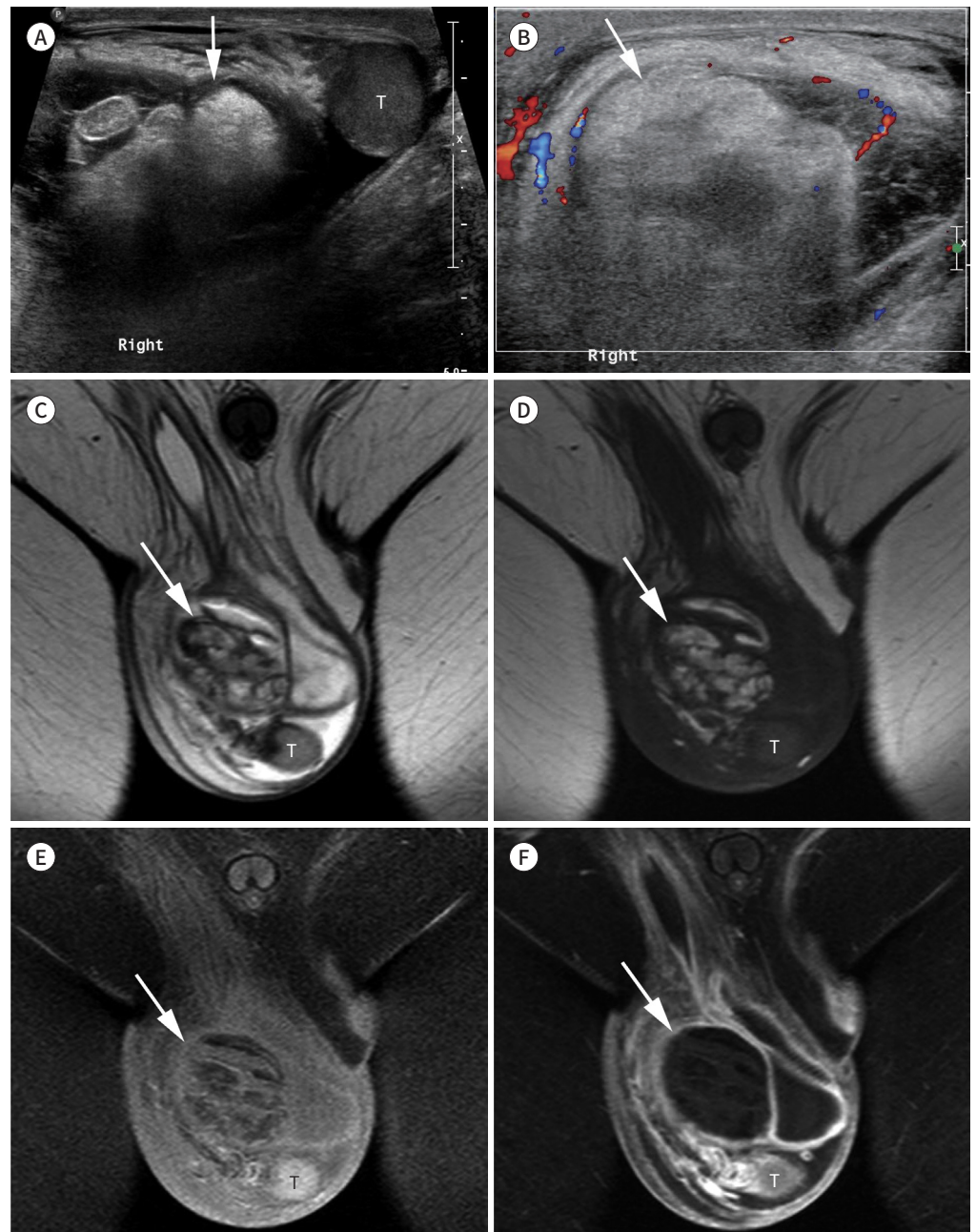
**B.** The mass shows no vascularity on color Doppler imaging.

**C.** T2WI of the scrotum demonstrates a multi-lobulated mass within an oligolocular cystic lesion with a thick wall and associated skin thickening. The mass primarily presents with a relatively high or intermediate signal intensity, with a certain degree of dark signal intensity rim on T2WIs, when compared with a normal testicle.

**D.** The mass mainly appears to be iso-intense than the subcutaneous fat on coronal T1WI. Normal right testis (T) is displaced inferiorly.

**E, F.** Coronal short tau inversion recovery image (**E**) and fat-suppressed T1WI with enhancement (**F**) demonstrate fat suppression of the mass. The thick wall of the cystic lesion is enhanced, indicating the presence of an infected hydrocele.

T = testis, T1WI = T1 weighted image, T2WI = T2 weighted image



## DISCUSSION

Smetana and Barnhard (1) coined the term “sclerosing lipogranuloma” in 1948 for a peculiar granulomatous reaction of fat tissue resulting from injury. Sclerosing lipogranuloma presents histologically with as granulomas, fat globules, multinucleated giant cells, lymphocyte infiltration, and fibrosis (6). “Sclerosing lipogranuloma” without a history of trauma is caused by foreign body injections, such as silicone, paraffin, and mineral oils (1-3). One article describing a case of sclerosing lipogranuloma after hernioplasty and varicocelectomy has been reported in English (7).

When sclerosing lipogranuloma develops in male genitalia, it most often involves the upper scrotum or peno-scrotal junction; less than 0.4% arise in the scrotal sac (5).

Our patient developed a right scrotal swelling and redness 2 months after hernioplasty. On USG and MRI studies, we suggested scrotal abscess with remnant omental fatty tissue. After antibiotic therapy, the subsequent USG still showed suggested remnant omental fatty tissue. Histopathological examination reported a sclerosing lipogranuloma.

Because the infected hydrocele with sclerosing lipogranuloma developed after hernioplasty, we posit a relationship between this lesion and the surgical procedure. There are two hypotheses about pathogenesis of sclerosing lipogranuloma. One possibility is that due to omental incarceration, the entire herniated omentum could not be removed during the hernioplasty. The remaining omental tissue might cause a foreign body reaction, resulting in a sclerosing lipogranuloma. The other hypothesis is that the infected hydrocele might cause an inflammatory response in the surrounding tissue. This would damage adipose tissue, resulting in a sclerosing lipogranuloma.

Ultrasonography is the first modality for evaluation of a scrotal mass. There is one case report (8) describing the USG findings of a sclerosing lipogranuloma of the scrotum in a 43-year-old man. The lesion appeared as a poorly defined, heterogeneously echogenic, extratesticular mass with continuation to the scrotal wall and an elongated appearance (8). In our case, however, the lesion was located within the tunica sac and appeared as a heterogeneously hyper-echoic lesion with posterior acoustic shadowing.

MRI is useful for tissue characterization and localization. Most literature on the MRI features of male genital sclerosing lipogranuloma describe a symmetrical Y-shape, with the arms of the Y surrounding the penile shaft and showing iso- and moderately high- signal intensity when compared to muscle on T1- and T2-weighted images, respectively, with irregular enhancement after gadolinium injection (9). Although MRI findings of sclerosing lipogranuloma of the penis had been reported in several studies, MRI feature of sclerosing lipogranuloma arising in the scrotal sac has not been reported yet. In our case, a lobular mass with infected hydrocele in the scrotal sac after hernioplasty and the mass showed higher signal intensity than muscle on T1- and T2-weighted images and fat suppression on STIR images, we could consider the presence of fatty components, even with a lot of inflammatory changes. Thus, MRI is an important imaging modality for evaluation of any fat component and characterizing the lesion when there is an inflammatory change, such as with an infected hydrocele.

In conclusion, we report a case of sclerosing lipogranuloma within an infected hydrocele. Despite its rarity, if radiologists recognize its radiologic findings, the possibility of sclerosing

lipogranuloma can be considered as a valid differential diagnosis. An MRI can be useful in a differential diagnosis of sclerosing lipogranuloma superimposed with infected hydrocele.

### Author Contributions

Conceptualization, C.J.H.; data curation, P.J.S.; formal analysis, P.J.S.; funding acquisition, C.J.H.; investigation, P.J.S.; methodology, C.J.H.; project administration, C.J.H.; resources, C.J.H.; software, P.J.S.; supervision, C.J.H.; validation, C.J.H.; visualization, P.J.S.; writing—original draft, P.J.S.; and writing—review & editing, C.J.H.

### Conflicts of Interest

The authors have no potential conflicts of interest to disclose.

### REFERENCES

1. Smetana HF, Barnhard WG. Sclerosing lipogranuloma. *Am J Pathol* 1948;24:675-677
2. Oertel YC, Johnson FB. Sclerosing lipogranuloma of male genitalia. Review of 23 cases. *Arch Pathol Lab Med* 1977;101:321-326
3. Newcomer VD, Graham JH, Schaffert RR, Kaplan L. Sclerosing lipogranuloma resulting from exogenous lipids. *AMA Arch Derm* 1956;73:361-372
4. Matsushima M, Tajima M, Maki A, Takanami M, Ando K, Atobe T. Primary lipogranuloma of male genitalia. *Urology* 1988;31:75-77
5. Kojima Y, Inoue H, Adachi Y, Ikehara S, Ohshima M. Sclerosing lipogranuloma of the male genitalia: report of 2 cases—review of 72 cases reported in Japan. *Hinyokika Kiyo* 1992;38:93-97
6. Terada T, Minami S, Onda H, Inatsuchi H, Sekido Y, Shimamura K, et al. Primary sclerosing lipogranuloma with broad necrosis of the scrotum. *Pathol Int* 2003;53:121-125
7. Baladas HG, Ng BK. Sclerosing lipogranuloma of the scrotum following a laparoscopic herniorrhaphy and varicocelectomy—a case report. *Ann Acad Med Singapore* 1997;26:238-240
8. Jung SE, Lee JM, Kang CS, Cho YH. Sclerosing lipogranuloma of the scrotum: sonographic findings and pathologic correlation. *J Ultrasound Med* 2007;26:1231-1233
9. Motoori K, Takano H, Ueda T, Ishihara M. Sclerosing lipogranuloma of male genitalia: CT and MR images. *J Comput Assist Tomogr* 2002;26:138-140

## 탈장성형술 후 음낭 내에 발생한 감염성 경화지방육아종의 초음파 및 자기공명영상 소견: 증례 보고

박종수 · 조재호\*

음낭 내에 발생한 경화지방육아종은 매우 드문 질환으로 지방조직의 이물반응에 의해 발생하는 것으로 알려져 있다. 주로 음경 및 음경음낭이음부에 발생한 임상적 보고 및 음낭 내 발생한 초음파 소견에 대한 증례 보고는 있었지만 저자들이 아는 한도에서는, 음낭 내 경화지방육아종의 자기공명영상 소견에 대하여 자세히 보고된 바는 없었고, 특히나 영문으로는 본 저자들이 탈장성형술 후 발생한 음낭 내 감염성 경화지방육아종에 대해 처음 보고하는 바이다.

영남대학교 의과대학 영상의학교실