

COMMUNICATION

Use of the short saphenous vein graft in microsurgical reconstruction

Jolie Hwee¹, Bien-Keem Tan², Yasunori Hattori³

¹Plastic, Reconstructive and Aesthetic Surgery Section, Tan Tock Seng Hospital, Singapore; ²Department of Plastic, Reconstructive and Aesthetic Surgery, Singapore General Hospital, Singapore; ³Department of Orthopedic Surgery, Ogori Daiichi General Hospital, Yamaguchi, Japan

Correspondence: Bien-Keem Tan

Department of Plastic, Reconstructive and Aesthetic Surgery, Singapore General Hospital, Academia, 20 College Road, 169856 Singapore

Tel: +65-6321 4686, Fax: +65-6227-3573, E-mail: bienkeem@gmail.com

Received: December 8, 2019 • Revised: April 4, 2020 • Accepted: April 17, 2020
pISSN: 2234-6163 • eISSN: 2234-6171
<https://doi.org/10.5999/aps.2019.01851> • Arch Plast Surg 2020;47:282-286



Copyright © 2020 The Korean Society of Plastic and Reconstructive Surgeons
This is an Open Access article distributed under the terms of the Creative Commons Attribution Non-Commercial License (<https://creativecommons.org/licenses/by-nc/4.0/>) which permits unrestricted non-commercial use, distribution, and reproduction in any medium, provided the original work is properly cited.

Vein grafts are commonly used for free tissue transfer in free flap salvage surgery, in irradiated beds after extensive tumor resection, and following high-energy trauma. In these procedures, vein grafts are employed to lengthen the pedicles of flaps to provide access to distant recipient vessels, allowing for versatile flap placement.

Most studies have focused on the use of the long saphenous vein (LSV) graft for free tissue transfer. However, we prefer to use the short saphenous vein (SSV) and preserve the LSV, which is the conduit of choice for a myriad of operations, especially coronary revascularization.

Patients

We present a series of 20 cases of microsurgical reconstruction in which SSV grafts were used in 2018, and we describe the characteristics of this graft and the harvesting technique used. This study was conducted in accordance with the ethical guidelines of our institutional review board (CIRB Ref No: 2017/2444). Written consent was obtained from patients for publication of their photographs.

Harvesting technique

The SSV is harvested with the patient in the supine position with the leg flexed. A line is drawn from the midpoint of the popliteal crease to the point midway between the posterior border of the lateral malleolus and the Achilles tendon (Fig. 1). The vein graft is harvested via a longitudinal incision in the upper aspect of the calf, where the vein is easily identified in the midline, between the muscular fascia and the membranous layer of the subcutaneous tissue [1]. Once identi-

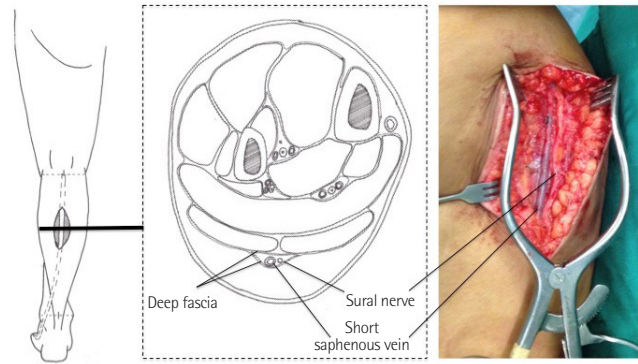


Fig. 1.

Anatomy of the short saphenous vein. Cross-section of the left calf at the point of incision showing the short saphenous vein extending alongside the sural nerve beneath the deep fascia.

fied, the vein is traced proximally and distally, extending the incision along the course of the vessel, and all branches are ligated as they are encountered. During harvesting, the assistant should push the patient's calf toward the surgeon for better visualization. The most common difficulties encountered when identifying the vein is dissection in the wrong plane (the vein is found beneath the deep fascia) and loss of the bearing of the midline. The harvested vein graft is flushed to check for leaking side branches and is then kept inflated with heparinized saline between two vascular clamps. One side is marked with ink to ensure that the direction of blood flow is correct and uninterrupted by valves. The vessel is prepared by removing the adventitia to prevent strictures. The vein graft is first anastomosed to the recipient vessel; after the flap pedicle is divided, the vein graft is then trimmed to the appropriate length, and the anastomosis to the flap vessel is completed.

In 20 cases, we used SSV grafts for microsurgical reconstruction (Table 1). Vein grafts were employed to lengthen the donor vessels to reach recipient vessels outside the zone of injury or the area of tumor resection. In cases of on-table flap venous congestion, SSV grafting was used as salvage for additional venous drainage. We highlight three illustrative cases.

SSV as an extension graft to the external jugular vein for scalp reconstruction in the presence of lower limb varicosities (case 3)

An 79-year-old woman underwent scalp reconstruction for cranio-plasty coverage using a latissimus dorsi muscle flap and a split-thickness skin graft (Fig. 2). The patient had a history of varicose vein stripping, and the LSV was unavailable. Microvascular anastomoses of one artery (the thoracodorsal artery to the superficial temporal artery) and one vein (the thoracodorsal vein to the external jugular vein using the SSV as an extension graft) were performed. The tunnel to the neck was created using a Dilson Luz vascular dilation wand and was kept patent with a 10-mL syringe while the pedicle was

Table 1. Details of cases of short saphenous vein graft used in microsurgery

Case No.	Age (yr)	Indication	Length (cm)	Details	Outcome	Notes
Head and neck reconstruction						
1	36	ALT flap for scalp reconstruction	7	SSV → STA LSV → EJV	Healed	
2	49	LD flap for scalp sarcoma reconstruction	8	SSV → EJV	First recurrence: reconstructed with rectus abdominis flap to same vessels Second recurrence: reconstructed with contralateral LD; SSV from contralateral leg used to lengthen STA	
3	79	LD flap for cranioplasty scalp reconstruction	10	SSV → EJV	Healed	SSV more easily accessible than LSV with patient in lateral position for LD harvest
4	31	LD flap for scalp reconstruction	10	SSV → EJV	Healed	
5	44	Fibula flap for medial clavicle and sternoclavicular joint reconstruction	4	SSV → EJV	Radiographic claviculofibular union at 3 months	
Upper limb reconstruction						
6	52	TAP flap for UL reconstruction	20	SSV → basilic vein	Healed	
7	48	Fibula flap for humerus osteomyelitis complicated by non-union	8	SSV → brachial artery LSV → basilic vein	Flap healed; complicated by non-union at 3 months	SSV easily accessible during harvest of fibula flap
Lower limb reconstruction						
8	78	LD flap for ankle implant coverage; need to alleviate on-table venous congestion	8	SSV → LSV	Flap healed; 2 weeks postoperatively, implant articular surface became infected	
9	49	LD flap for ankle degloving injury	8	SSV → LSV	Healed, ambulating	
10	40	LD flap for exposed Achilles tendon secondary to necrotizing fasciitis; need to alleviate on-table venous congestion	7	SSV → LSV	Healed	
11	58	LD flap and rib for segmental defect of tibia; need to alleviate on-table venous congestion	7	SSV → LSV	Healed	LSV more often fibrotic than SSV
12	61	LD flap for ankle implant coverage	8	SSV → deep vein	Healed	
13	35	ALT flap for ankle degloving injury	8	SSV → LSV	Healed	
Chest wall reconstruction						
14	50	LD flap for chest wall sarcoma reconstruction; ipsilateral vascular bundle resected	10	SSV → contralateral IMA and IMV	Healed	
Breast reconstruction						
15	46	Ipsilateral TRAM flap for superdrainage	4	SSV → thoracodorsal vein	Healed	
16	58	Ipsilateral TRAM flap for superdrainage	4	SSV → thoracodorsal vein	Healed	
17	62	Ipsilateral TRAM flap for superdrainage	5	SSV → branch of axillary vein	Healed	
18	66	Ipsilateral TRAM flap for superdrainage	5	SSV → thoracodorsal vein	Healed	
19	44	Contralateral TRAM flap for superdrainage	7	SSV → thoracodorsal vein	Healed	

ALT, anterolateral thigh; SSV, short saphenous vein; STA, superior thyroid artery; LSV, long saphenous vein; EJV, external jugular vein; LD, latissimus dorsi; TAP, thoracodorsal artery perforator; UL, upper limb; IMA, internal mammary artery; IMV, internal mammary vein; TRAM, transverse rectus abdominis myocutaneous.

passed through.

The superior temporal artery is an excellent artery for scalp reconstruction; however, the superior temporal vein is usually too small. Additionally, the superficial temporal vein is unreliable, as it is relatively likely to have been cauterized during previous neurosurgical operations with bicoronal or question-mark incisions. The authors of the present study often do not use the superficial temporal vein, but instead use a vein graft to the external jugular vein. This case also il-

lustrates that the SSV is more commonly spared than the LSV in cases involving lower limb varicosities.

SSV for second venous anastomosis in clavicular reconstruction (case 5)

A 44-year-old woman with tuberculous osteomyelitis of the right clavicle underwent en bloc resection of the right sternoclavicular

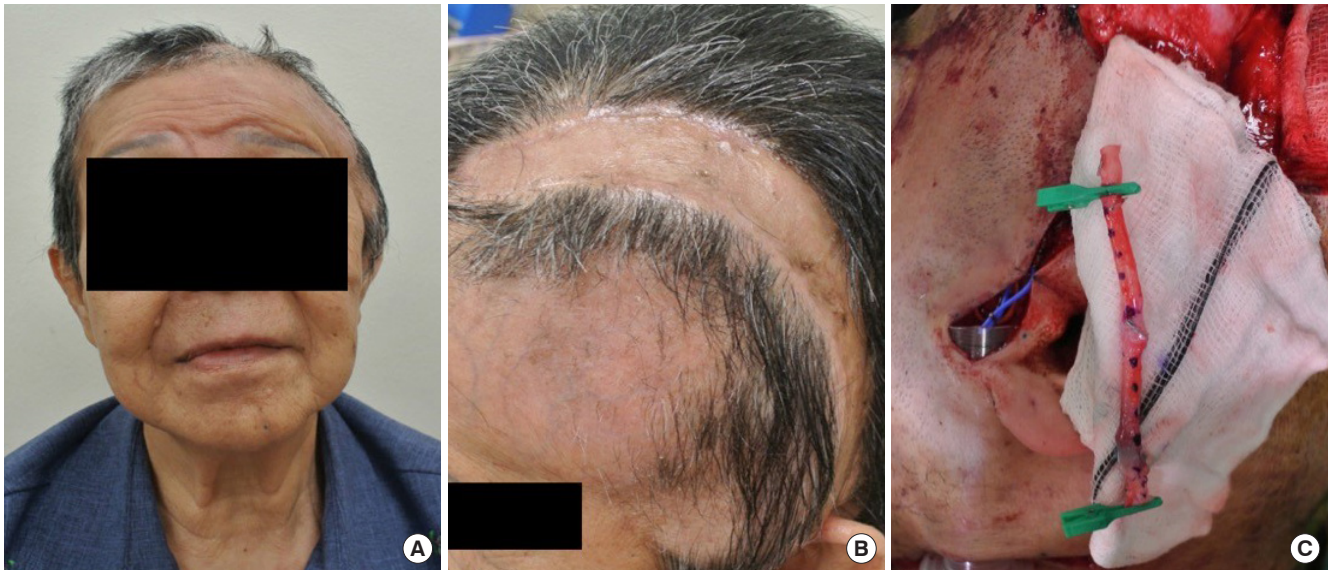

Fig. 2.

Scalp reconstruction (case 3). (A, B) Postoperative result of coverage of cranioplasty with a latissimus dorsi muscle flap and a split-thickness skin graft. Microanastomosis of the thoracodorsal artery to the superficial temporal artery and one vein was performed. (C) The vein graft was harvested and marked along its length to prevent twisting. The tunnel was kept patent with a cut 10-mL syringe while the pedicle was passed through.

joint. The resulting 8 × 6 cm composite defect was reconstructed with a fibular osteocutaneous flap with a 10-cm bone graft. Microvascular anastomoses of one artery (the peroneal artery to the dorsal scapular artery) and two veins (one to the external jugular vein and the other to the internal jugular vein with SSV vein grafting) were performed (Fig. 3).

Whenever possible, two venous anastomoses should be performed. However, it is important that the second vein not sabotage the first vein such that the lie of the first vein is disturbed. The use of the SSV allowed tension-free anastomoses without kinking of the vessels.

SSV as an arterial extender (case 7)

A 48-year-old man with a Gustilo IIIB open fracture of the left humerus complicated by osteomyelitis underwent segmental resection of the lateral diseased segment of the humerus with fibula osteocutaneous flap reconstruction (Fig. 4). A 15-cm-long segment of bone was inset to the lateral humerus and revascularized using the neurovascular bundle of the brachial artery. A 6-cm segment of the SSV was harvested from the ipsilateral leg. Microvascular anastomoses of one artery (the peroneal artery to the brachial artery using an SSV interposition graft) and two veins (one to the cephalic vein and the other to the basilic vein using LSV interposition grafting) were performed.

This case emphasizes that the SSV is a good match for the arteries of common free flaps, such as fibula, radial forearm, and anterolateral thigh flaps. The LSV is often too large and is more suitable for larger-capacitance veins, such as the peroneal and latissimus dorsi veins.

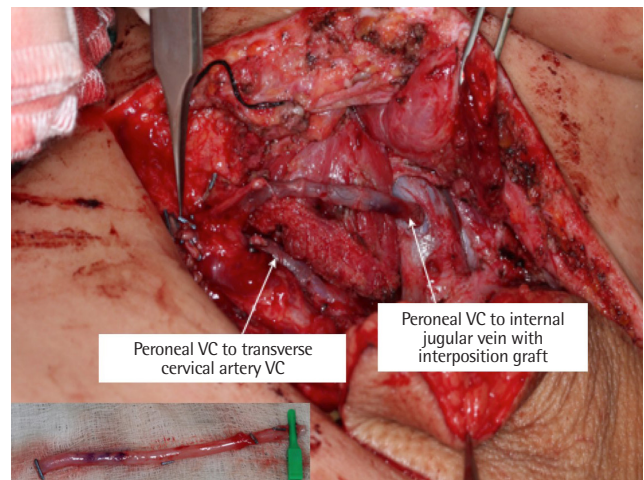


Fig. 3.

Clavicular reconstruction (case 5). Reconstruction of the right sternoclavicular joint and the medial third of the clavicle with a fibula osteocutaneous flap. Microvascular anastomoses of one artery (the peroneal artery to the dorsal scapular artery) and two veins (one to the external jugular vein and the other to the internal jugular vein using short saphenous vein grafting) were performed. VC, venae comitantes.

Additionally, the SSV can be easily harvested along with a fibula flap, as it lies in close proximity beneath the deep fascia.

Discussion

The SSV is our conduit of choice due to its ease of access and suitable vessel diameter. The average width of the vein over its course is 3 mm

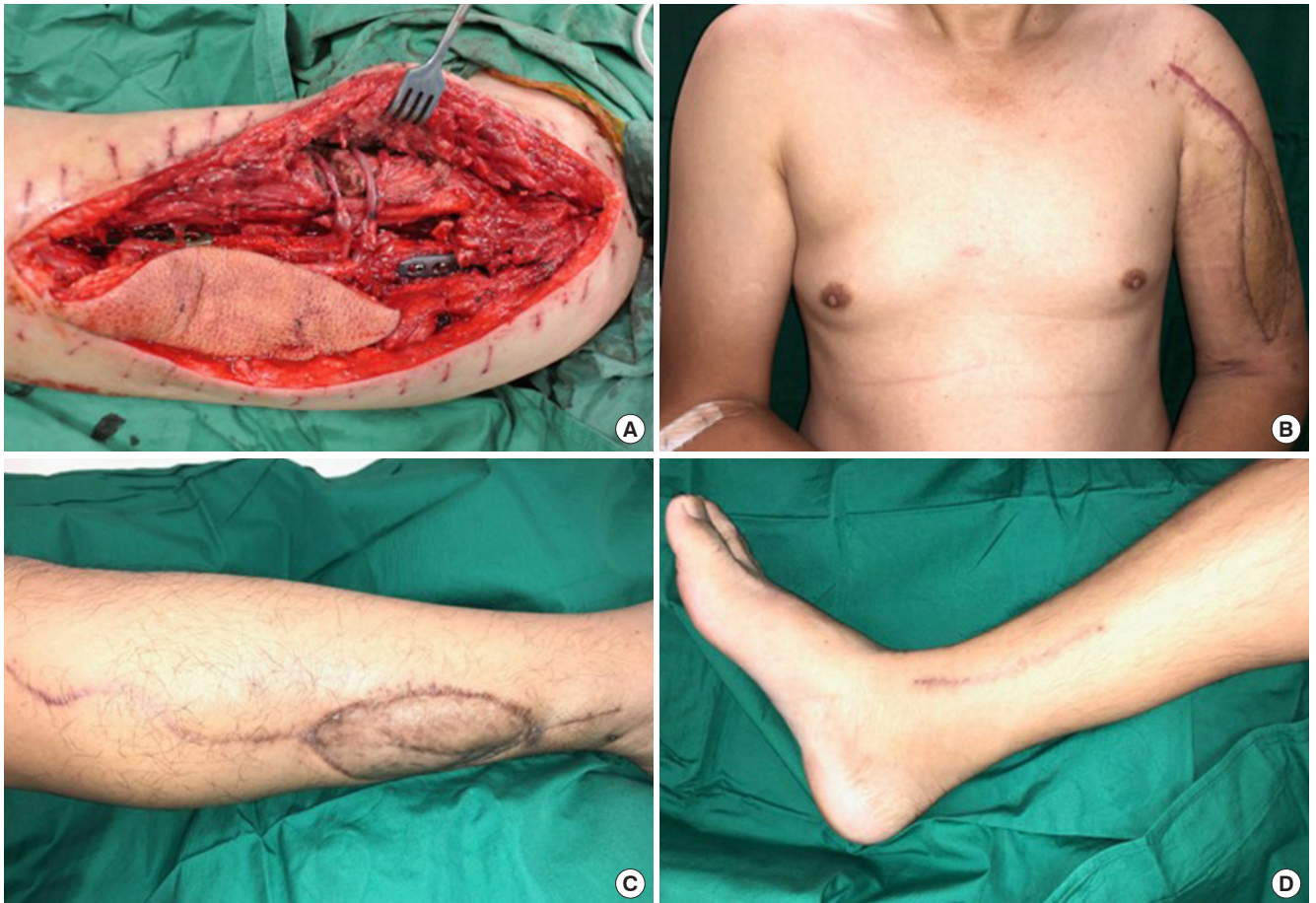


Fig. 4. Upper limb reconstruction (case 7). (A) Reconstruction of the humerus with a fibula osteocutaneous flap. Microvascular anastomoses of one artery (the peroneal artery to the brachial artery using a short saphenous vein interposition graft) and two veins (one to the cephalic vein and the other to the basilic vein using long saphenous vein interposition grafting) were performed. (B) Postoperative result. (C) Fibula flap and short saphenous vein donor site. (D) Long saphenous vein graft donor site.

Table 2. Comparison of the long saphenous vein with the short saphenous vein for vein grafting		
	Long saphenous vein	Short saphenous vein
Advantages	<ul style="list-style-type: none"> • Greater length of vein graft • Easier to harvest “Y” graft configuration where there are two veins available 	<ul style="list-style-type: none"> • Preserves long saphenous vein • Spared during varicose vein stripping • Better arterial match for most muscle flaps (in thickness and diameter) • Thin-walled and easily dilated • Yields a better-hidden posterior scar
Disadvantages	<ul style="list-style-type: none"> • Frequently limited by previous stripping or bypass procedures • Often traumatized by prior venepuncture • Thick-walled, fibrotic, and prone to spasm • Causes scarring over ankle joint 	<ul style="list-style-type: none"> • Posterior calf access

[2], which is a suitable size match for most muscle flaps. Depending on a patient’s habitus, up to 40–50 cm of vein from its origin to the popliteal fossa can be harvested for grafting.

Use of the LSV is frequently limited by previous stripping or prior bypass operations. The SSV is usually spared during varicose vein stripping and is easily dissected from the leg. The LSV should be preserved for bypass operations, to improve the vascularity of fasciocutaneous flaps in the leg [3], or as an alternate outflow vessel for lower limb free flap reconstruction [4]. We propose that SSV grafts are preferable to LSV grafts as autogenous vein grafts. We compare the characteristics of the LSV and SSV for vein grafting in Table 2.

We use the SSV as the conduit of choice for the majority of microsurgical cases that require vein grafting. Use of the SSV is ideal when a long vein graft is required, the patient is concerned about donor site scarring, a concomitant nerve graft is needed, the LSV has been exhausted or is unsuitable due to varicosities, or several vein grafts are required.

The SSV is a valuable asset for the microsurgeon. We propose that

SSV grafts should be considered preferable to LSV grafts due to their ready availability, ease of preparation and harvesting, and optimal handling characteristics. The SSV graft provides a reliable adjunctive technique and is a better caliber match than the LSV for most muscle flaps.

Notes

Conflict of interest

No potential conflict of interest relevant to this article was reported.

Ethical approval

The study was approved by the Institutional Review Board of Singapore General Hospital (IRB No. 2017/2444) and performed in accordance with the principles of the Declaration of Helsinki. Written informed consents were obtained.

Patient consent

The patients provided written informed consent for the publication and the use of their images.

Author contribution

Conceptualization: J Hwee, BK Tan, Y Hattori. Data curation: J

Hwee, BK Tan. Formal analysis: J Hwee, BK Tan. Methodology: Y Hattori. Project administration: J Hwee, BK Tan. Visualization: BK Tan, Y Hattori. Writing - original draft: J Hwee. Writing - review & editing: J Hwee, BK Tan.

ORCID

Jolie Hwee <https://orcid.org/0000-0002-5605-3086>

Bien-Keem Tan <https://orcid.org/0000-0002-7347-8713>

Yasunori Hattori <https://orcid.org/0000-0002-8053-2562>

References

1. Caggiati A. Fascial relationships of the short saphenous vein. *J Vasc Surg* 2001;34:241-6.
2. Kosinski C. Observations on the superficial venous system of the lower extremity. *J Anat* 1926;60(Pt 2):131-42.
3. Foo TL, Chew WY, Tan BK. Improving the reliability of the distally based posterior tibial artery adipofascial flap with the great saphenous venoneural network. *Ann Plast Surg* 2011;67:288-93.
4. Goh T, Tan BK, Ong YS, et al. Serratus anterior venous tributary as a second outflow vein in latissimus dorsi free flaps. *J Reconstr Microsurg* 2011;27:469-74.