



Extracorporeal Membrane Oxygenation in Pediatric Patients with Respiratory Failure: Early Experience with the Double-Lumen Cannula Over 2 Years

Woojung Kim, M.D.¹, Hye Won Kwon, M.D.², Jooncheol Min, M.D.¹, Sungkyu Cho, M.D.¹, Jae Gun Kwak, M.D., Ph.D.¹, Woong Han Kim, M.D., Ph.D.¹

Departments of ¹Thoracic and Cardiovascular Surgery and ²Pediatrics, Seoul National University Children's Hospital, Seoul National University College of Medicine, Seoul, Korea

ARTICLE INFO

Received June 28, 2019
Revised September 2, 2019
Accepted December 25, 2019

Corresponding author

Hye Won Kwon
Tel 82-2-2072-4306
Fax 82-2-747-2471
E-mail drhwkwon@gmail.com
ORCID
<https://orcid.org/0000-0002-4949-9688>

Background: The double-lumen cannula (DLC) has begun to be used worldwide for venovenous (VV) extracorporeal membrane oxygenation (ECMO). We aimed to examine whether the DLC could be an effective tool in the treatment of pediatric respiratory failure in Korea.

Methods: We reviewed the records of patients weighing under 15 kg who underwent ECMO due to respiratory failure between January 2017 and December 2018. Outcomes of ECMO using a DLC and conventional ECMO using central method or 2 peripheral cannulas were compared.

Results: Twelve patients were treated with ECMO for respiratory failure. Among them, a DLC was used in 5 patients, the median age of whom was 3.8 months (interquartile range, 0.1–49.7 months). In these patients, the median values of pH, partial pressure of carbon dioxide, and partial pressure of oxygen were 7.09, 74 mm Hg, and 37 mm Hg before ECMO and corrected to 7.31, 44 mm Hg, and 85 mm Hg, respectively, after ECMO cannulation. Median blood flow rate in the patients treated with ECMO using a DLC was slightly higher than that in the conventional ECMO group, but this difference was not statistically significant (86.1 mL/kg/min and 74.3 mL/kg/min, respectively; $p=1.00$). One patient from the DLC group and 3 patients from the conventional group were weaned off ECMO.

Conclusion: VV ECMO using a DLC provided adequate oxygenation, ventilation, and blood flow rate in Korean pediatric patients with respiratory failure. Further prospective and randomized studies are warranted.

Keywords: Extracorporeal membrane oxygenation, Respiratory insufficiency, Pediatrics

Introduction

Extracorporeal membrane oxygenation (ECMO) has been an important therapy in pediatric patients with cardiopulmonary failure since Bartlett et al. [1] successfully used it in neonates in 1975. ECMO in pediatric patients originally involved a peripheral venoarterial (VA) access procedure using the common carotid artery for blood return and the internal jugular vein for drainage or central VA access. Due to the neurological complications associated with VA ECMO, the use of venovenous (VV) ECMO in pediatric patients is becoming more common [2,3]. How-

ever, conventional VV ECMO using 2 cannulas has some disadvantages, such as cannula kinking, recirculation, and challenges related to the small femoral veins in younger pediatric patients. Recently, the percutaneous double-lumen cannula (DLC, Avalon Elite; Maquet, Rastatt, Germany) has gained interest as an ECMO cannulation modality because of its advantages of single cannulation, less invasiveness, less kinking, and less recirculation [4,5]. In South Korea, ECMO cannulation is becoming more frequent annually, and its use is expected to expand in the future [6]. In this study, we aimed to investigate the outcomes of VV ECMO using a DLC and compared them with those of



conventional VA or VV ECMO performed with other cannulation methods over the past 2 years at a single center in Korea.

Methods

The records of all pediatric patients weighing less than 15 kg who were treated with ECMO due to respiratory failure between January 2017 and December 2018 were reviewed retrospectively. Data regarding age, sex, body weight, etiology of respiratory failure, laboratory findings (such as blood gas profile), blood flow rate through the ECMO circuit, procedure time, cannulation method and position, complications, cannula repositioning, number of circuit changes, and anticoagulation regimen were obtained by reviewing patients' medical records. Pre-ECMO arterial blood gas analysis was obtained just before ECMO cannulation, and post-ECMO arterial blood gas analysis was performed immediately after ECMO cannulation. Bleeding complications were evaluated using the Clavien-Dindo classification system [7]. Patients were then divided into 2 groups, with the DLC group including patients who underwent VV ECMO with an Avalon catheter (Maquet) and the conventional group including patients who underwent VA or VV ECMO using other cannulation methods.

This study was approved by the Institutional Review Board of Seoul National University Hospital in Seoul, Korea (approval no., H-1905-017-103) and was in compliance with the Declaration of Helsinki. The board waived the requirement for patients' informed consent because of the retrospective design.

Choice of cannulation

Patients whose conditions were expected to progress to respiratory failure were consulted for VV ECMO using a DLC. If the parents agreed to pay the import fee, we ordered the DLC after approval by the Korean Food and Drug Administration, and it arrived approximately 2 months later from the United States. The first case consulted for VV ECMO using a DLC had a diagnosis of congenital diaphragmatic hernia (CDH); however, the patient expired before the DLC arrived. For the next case (DLC1), which was also a patient with CDH, we used the DLC that was prepared for the first case, and we then ordered another DLC. When ECMO cannulation was required in a third case, our team decided to use the DLC prepared for the second patient with agreement from both parents. Although the

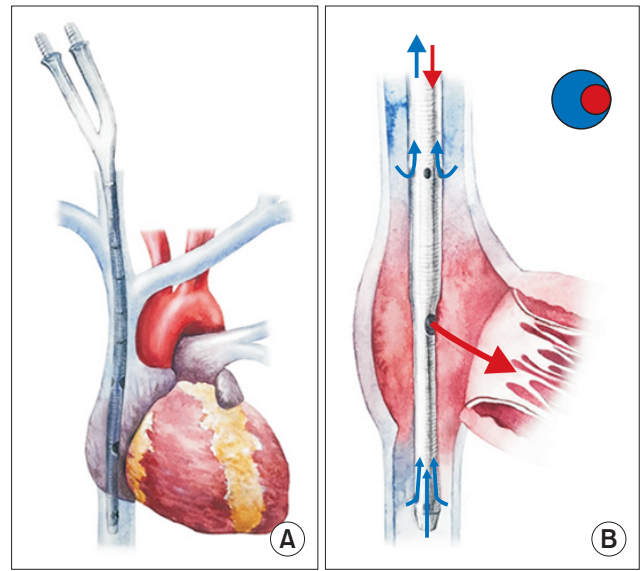


Fig. 1. (A, B) The double-lumen cannula inserted with the proper anatomical configuration. The cannula should be inserted into the right internal jugular vein, advanced into the right atrium, and extended to the inferior vena cava. The drainage hole is indicated by the blue arrow and the return hole by the red arrow.

size of the DLC cannula varies from 13F to 31F, we were only able to import 1 size for each patient. Therefore, we could only use a DLC when the previously-ordered cannula fits for the next patient. When a patient needed emergent VV ECMO cannulation, the surgeon chose peripheral VV ECMO using 2 cannulations if there was no appropriately-sized DLC available for the patient. If a patient was too small for the femoral vein to be used, the surgeon chose central VV ECMO. For patients with ventricular dysfunction or pulmonary hypertension, the surgeon chose central or peripheral VA ECMO.

Surgical procedure and management

Before cannulation, vessel size and anatomy were confirmed by Doppler ultrasonography to prevent cannulation-related vascular injuries and to choose the appropriate cannula size. After cannulation, the cannula position was confirmed by chest X-ray imaging, and daily monitoring for late mechanical complications such as delayed cardiac wall rupture was performed with 2-dimensional echocardiography [8]. If the cannula was not positioned properly to enable acceptable flow, it was repositioned. In ECMO with DLC, the cannula was inserted into the right internal jugular vein (RIJV), advanced into the right atrium (RA), and extended to the inferior vena cava (Fig. 1). In central VA ECMO, a venous drainage cannula was inserted into

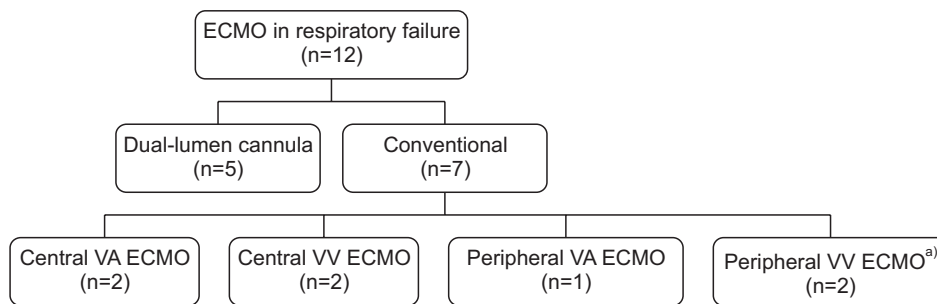


Fig. 2. Number of pediatric patients with respiratory failure supported by ECMO for the past 2 years at Seoul National University Children's Hospital. ECMO, extracorporeal membrane oxygenation; VA, venoarterial; VV, venovenous. a)Using 2 cannulations.

the RA, and an arterial cannula was inserted into the ascending aorta. In central VV ECMO, a drainage cannula was inserted into the RA, and the blood return cannula was inserted into the pulmonary artery. In peripheral VA ECMO, the venous drainage cannula was positioned at the RIJV, while the arterial blood return cannula was placed at the carotid artery. Finally, in peripheral VV ECMO using 2 cannulations, the venous drainage cannula was placed at the femoral vein and the blood return cannula at the RIJV. All peripheral ECMOs were inserted using the Seldinger or semi-Seldinger technique. The Lilliput 2 ECMO (LivaNova, Mirandola, Italy) and Permanent Life Support System (Maquet) were used for the ECMO circuit. Continuous heparin infusion was used as anticoagulation therapy in ECMO, with the heparin infused by bolus at 50–100 U/kg upon cannulation, after which a continuous dose was administered based on the activated partial thromboplastin time (aPTT) at an interval of 4 hours.

Statistical analysis

The demographic and clinical data introduced above were described as the median and interquartile range (IQR) for continuous variables and as the frequency and percentage for categorical variables. Patients were divided into either the DLC group or the conventional group (Fig. 2). Survival and baseline patient characteristics of the 2 groups were compared. The Mann-Whitney U-test was used to compare continuous variables, and the Fisher exact test was used to compare discrete variables. All p-values less than 0.05 were considered to indicate statistical significance. Statistical analyses were performed using IBM SPSS ver. 21.0 (IBM Corp., Armonk, NY, USA).

Results

Twelve patients were treated with ECMO for respiratory

failure. Five patients were treated with VV ECMO using a DLC, and 7 patients were treated with VA or VV ECMO using the conventional cannulation method. The median age of all patients at the time of cannulation was 4.2 months (IQR, 0.1–19.5 months), and the median body weight was 6.4 kg (IQR, 3.7–13.2 kg). The median values of pre-ECMO arterial pH, partial pressure of carbon dioxide (PaCO₂), and partial pressure of oxygen (PaO₂) were 7.18 (IQR, 7.00–7.26), 74.0 mm Hg (IQR, 57.8–93.3 mm Hg), and 39.5 mm Hg (IQR, 17.5–66.8 mm Hg), respectively. The median value of the oxygenation index pre-ECMO cannulation was 36.8 (IQR, 19.4–67.2). The median values of post-ECMO arterial pH, PaCO₂, and PaO₂ were 7.37 (IQR, 7.21–7.50), 44.5 mm Hg (IQR, 33.3–48.0 mm Hg), and 85.0 mm Hg (IQR, 60.5–159.5 mm Hg), respectively. Severe respiratory acidosis was corrected after ECMO cannulation. There were no statistically significant differences in demographic data or the blood gas analysis between the DLC group and the conventional group (Table 1).

Table 2 shows all cases in this study and their etiologies. The etiologies were similar between the DLC group and the conventional group. In neonates, there were more cases of CDH, meconium aspiration syndrome, and bronchopulmonary dysplasia than cases of acquired disease, such as pneumonia.

A 13F DLC was inserted in 4 patients, while a 19F DLC was used in 1; the catheter sizes for the conventional group are shown in Table 2. Blood flow rate through the DLC ECMO was higher than that in the conventional group at 86.1 mL/kg/min (IQR, 59.9–111.1 mL/kg/min) and 74.3 mL/kg/min (IQR, 70.8–89.2 mL/kg/min), respectively, but this difference was not statistically significant (p=1.00). The flow rate in all cases of DLC ECMO was maintained properly. Fig. 3 shows the DLC ECMO flow rate for the initial 10 days. The median ECMO duration was 7 days (IQR, 5.3–27.0 days), and no significant difference was found between the DLC group and the conventional group. The

Table 1. Demographic data and blood gas profile of cases

Variable	Total (N=12)	DLC (n=5)	Conventional (n=7)	p-value
Age (day)	125.5 (3.0–585.0)	116 (1.5–1490)	135 (0.3–611.0)	0.88
Weight (kg)	6.4 (3.7–13.2)	6.3 (3.5–11.2)	6.5 (3.5–13.8)	0.76
Height (cm)	64 (49.4–106.4)	56 (49.0–93.0)	72.0 (50.5–115.0)	0.53
Oxygenation index	36.8 (19.4–67.2)	43.4 (25.8–57.3)	30.1 (11.6–87.3)	0.76
pH, pre	7.18 (7.00–7.26)	7.09 (6.97–7.27)	7.19 (7.04–7.27)	0.43
PaCO ₂ , pre (mm Hg)	74.0 (57.8–93.3)	74 (64.0–97.0)	70.0 (53.7–94.0)	0.64
PaO ₂ , pre (mm Hg)	39.5 (17.5–66.8)	37 (22.5–54.0)	58.0 (17.0–69.0)	0.64
pH, post	7.37 (7.21–7.50)	7.31 (7.17–7.45)	7.45 (7.20–7.51)	0.43
PaCO ₂ , post (mm Hg)	44.5 (33.3–48.0)	44 (32.3–48.0)	45.0 (34.0–55.0)	0.76
PaO ₂ , post (mm Hg)	85.0 (60.5–159.5)	85 (48.5–81.0)	110.0 (65.0–219.0)	0.27

Values are presented as median (interquartile range) for continuous variables.

DLC, double-lumen cannula; PaCO₂, partial pressure of carbon dioxide in the arterial blood; PaO₂, partial pressure of oxygen in the arterial blood; pre, pre-ECMO; post, post-ECMO; ECMO, extracorporeal membrane oxygenation.

Table 2. Demographic data, etiology, cannula data, and outcomes of all patients

Patient	Age	Weight (kg)	Height (cm)	Etiology	Cannulation site	Cannula size (F)	Mean ECMO flow (mL/kg/min)	ECMO duration (day)	Outcome
DLC1	3 day	2.84	49	CDH	RIJV	13	86.0	140	Death
DLC2	0 day	4.07	49	MAS	RIJV	13	105.6	6	Death after conversion to cVA ECMO
DLC3	5.5 mo	6.3	56	BPD	RIJV	13	69.8	1	Death
DLC4	14.7 mo	10.0	75	Pneumonia after HSCT	RIJV	19	116.5	6	Weaned
DLC5	7 yr	12.0	111	Pneumonia after HSCT	RIJV	13	50	24	Death after conversion to pVA ECMO
cVV1	3 day	2.29	46	BPD	MPA and RA	8 and 10	109.2	7	Death
cVV2	4.4 yr	15.2	116	ILD	MPA and RA	8 and 10	86.7	53	Weaned
pVV1	20.4 mo	13.6	72	Pneumonia after HSCT	RIJV and RCFV	12 and 14	74.3	28	Death
pVV2	16.9 mo	13.8	92.7	BO	RIJV and LCFV	12 and 17	72.5	4	Weaned
cVA1	1 day	3.53	50.5	CDH	AA and RA	8 and 12	70.8	26	Death
cVA2	4.5 mo	3.9	56	BPD	AA and RA	8 and 12	112.8	18	Death
pVA1	3.4 mo	6.5	115	PPHN	RCA and RIJV	10 and 12	89.2	7	Weaned

ECMO, extracorporeal membrane oxygenation; DLC, double-lumen cannula; CDH, congenital diaphragmatic hernia; RIJV, right internal jugular vein; MAS, meconium aspiration syndrome; cVA, central venoarterial; BPD, bronchopulmonary dysplasia; HSCT, hematopoietic stem cell transplant; pVA, peripheral venoarterial; cVV, central venovenous; MPA, main pulmonary artery; RA, right atrium; ILD, interstitial lung disease; pVV, peripheral venovenous; RCFV, right common femoral vein; BO, bronchiolitis obliterans; LCFV, left common femoral vein; AA, ascending aorta; PPHN, persistent pulmonary hypertension of the newborn; RCA, right carotid artery.

longest duration of DLC use was 140 days. One patient (20%) in the DLC group and 3 patients (42.9%) in the conventional group were weaned off ECMO. However, this difference was not statistically significant ($p=0.60$) (Table 3). The causes of death in the DLC group were sepsis ($n=1$), right ventricular (RV) failure ($n=1$), thrombus ($n=1$), and multiorgan failure ($n=1$), while those in the conventional group were thrombus ($n=1$), RV failure ($n=1$), and multiorgan failure ($n=2$). Two cases in the DLC group were converted to VA ECMO due to aggravated pulmonary hypertension and associated right heart failure. One patient

(DLC3) underwent cannulation for central VV ECMO first, because the DLC had not arrived yet. We decided to change the central ECMO to DLC because of severe mediastinal bleeding after the DLC arrived; however, the patient expired due to right heart failure with progressive pulmonary hypertension due to underlying bronchopulmonary dysplasia.

The median procedure time of all ECMO operations was 67.5 minutes (IQR, 49.8–125.3 minutes), which was comparable to those of the DLC and conventional groups (64 and 69 minutes, respectively). The procedure time was longer

in 2 patients in the DLC group because additional procedure time was required for removal of a Hickman catheter in the RIJV or sternotomy repair for weaning off central ECMO. Without these 2 cases, the median procedure time of the DLC was 55 minutes. Cannula repositioning was required in 1 case (20%) in the DLC group and in 2 cases (29%) in the conventional group. Procedure-related complications such as RA perforation or vascular injury were not reported in this study (Table 3).

The aPTT during ECMO with DLC was 55–70 seconds, which was lower than that in the conventional group (60–85 seconds). There were no neurological complications in either group. Complications related to anticoagulation included grade II bleeding of multiple organs, with specific manifestations including hematuria and epistaxis. These complications were more frequent in the conventional

group than in the DLC group; however, patients in the DLC group were more likely to require a circuit change (60% in the DLC group versus 14.3% in the conventional group) (Table 3). In one case, DLC ECMO was stopped unexpectedly due to RA thrombosis, and the patient expired on that day despite emergency sternotomy.

Discussion

Peripheral VV ECMO using a DLC allowed for proper gas exchange and an adequate flow rate despite the small size of the cannula. DLC usage was safe in that there were no vascular injuries or neurological complications in the DLC group. Although the mortality rate was higher and the weaning rate was lower in the DLC group than in the conventional group, no statistical significance was noted for either.

Respiratory failure is a very severe condition, leading to death in 40%–60% of cases [9]. According to the Extracorporeal Life Support Organization, VA ECMO was applied in approximately 70% and VV ECMO was applied in approximately 20% of pediatric cases of respiratory failure [10]. However, VV ECMO has recently begun to replace VA ECMO because VA ECMO has several disadvantages in the treatment of respiratory failure [11]. VA ECMO causes the lungs and coronary arteries to become perfused with poorly oxygenated blood, increasing the afterload of the left ventricle. Moreover, embolic complications such as distal limb morbidity have been found to occur relatively frequently in patients treated with VA ECMO [12,13]. Carpenter et al. [3] reported a higher incidence of intracranial hemorrhage in VA ECMO than in VV ECMO, as well as better survival with VV ECMO.

Conventional peripheral VV ECMO is not feasible in pediatric patients with small femoral veins; however, the

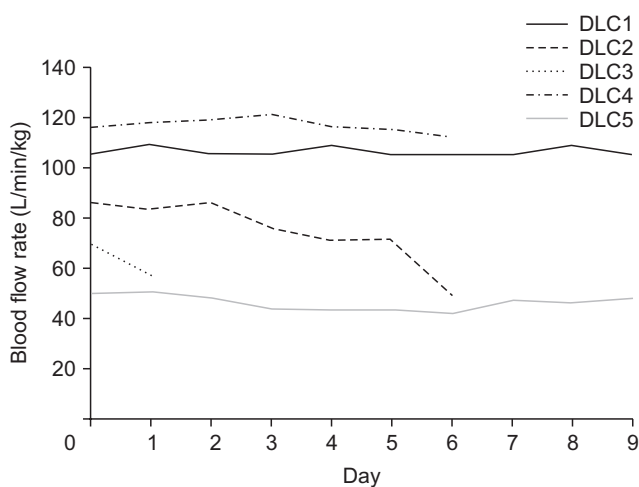


Fig. 3. Blood flow rate in patients who underwent extracorporeal membrane oxygenation with a double-lumen cannula for the first 10 days. DLC, double-lumen cannula.

Table 3. ECMO profile, complications, and mortality

Variable	Total (N=12)	DLC (n=5)	Conventional (n=7)	p-value
ECMO duration (day)	7 (5.3–27.0)	6 (3.5–82.0)	7 (5.0–28.0)	0.88
ECMO flow (mL/kg/min)	80.1 (70.1–101.5)	86.1 (59.9–111.1)	74.3 (70.8–89.2)	1.00
Procedure time (min)	67.5 (49.8–125.3)	64 (48.5–120.0)	69 (48.0–173.0)	0.53
Reposition necessary	2 (16.7)	1 (20.0)	1 (14.0)	1.00
Minimum aPTT (sec)	57.5 (41.3–70.0)	55.0 (42.5–70.0)	60 (40.0–75.0)	0.75
Maximum aPTT (sec)	77.5 (55.0–90.0)	70.0 (52.5–87.5)	85 (55.0–90.0)	0.53
Circuit change	4 (33.3)	3 (60.0)	1 (14.3)	0.22
Bleeding	7 (58.3)	2 (40.0)	5 (71.4)	0.56
Thrombus	2 (16.7)	1 (20.0)	1 (14.0)	1.00
Death during ECMO	8 (66.7)	4 (80.0)	4 (57.1)	0.58

Values are presented as or median (interquartile range) for continuous variables and frequency (%) for categorical variables. DLC, double-lumen cannula; ECMO, extracorporeal membrane oxygenation; aPTT, activated partial thromboplastin time.

newly developed DLC could overcome this disadvantage via single cannulation [14]. In emergency situations, VV ECMO can be inserted faster with the DLC, and complications related to femoral cannulation such as infection and vascular injury can be avoided [4,5,15]. Patients with a DLC have been found to move better, lie in the prone position more easily, and have less trouble engaging in physical therapy than patients treated with conventional ECMO [9,16].

Several studies have reported that DLC VV ECMO was durable and capable of producing satisfactory oxygenation [17,18]. In our study, the ECMO flow rate was maintained in all DLC patients at a statistically similar rate to that achieved using conventional cannulation. This flow rate was sufficient for oxygenation and gas ventilation. In this study, the longest duration of DLC use was 140 days, which is longer than the 14 days recommended by the manufacturer. We believe that VV ECMO using a DLC could be a bridge to lung transplantation with less invasiveness and better mobilization than conventional VV ECMO, especially in pediatric patients given the shortage of donors and relatively long waiting time for transplants [9].

Recent studies have reported remarkable results of the use of the DLC with single cannulation in pediatric practice. Speggorin et al. [8] reported that 94.4% of neonates with respiratory failure could be weaned from the DLC, and Lazar et al. [19] reported a 56% overall survival rate of neonates with respiratory failure using DLC cannulation. However, several studies have reported poor prognoses for hematopoietic stem cell transplantation (HSCT) and CDH with ECMO support [10,20,21]. In our study, only 1 patient in the DLC group could be weaned off ECMO versus 3 patients in the conventional group. This poor outcome may have been due to the fact that 40% of the patients in the DLC group were treated with HSCT, and 20% were diagnosed with CDH. The patients with CDH and HSCT treated in the conventional group (28.5%) also died.

One patient (DLC3) was switched to DLC from central VV ECMO, because of severe mediastinal bleeding, and he then expired due to progressive RV failure. We thought that central VV ECMO could play a pumping role from the RV to the pulmonary artery; however, the DLC could not perform this role, and RV failure thus progressed in the patient due to severe pulmonary hypertension. Therefore, we suggest that central VV ECMO or VA ECMO may be more helpful than DLC VV ECMO in patients with RV failure resulting from pulmonary hypertension.

The DLC is designed to prevent recirculation, and it is easy to insert. However, to achieve appropriate flow rate,

the cannula should be positioned in an anatomically proper fashion (Fig. 1). Jarboe et al. [14] reported that 69% of patients with a DLC who experienced problems with cannula malposition required repositioning. Several studies have suggested an echocardiography- or fluoroscopy-guided insertion technique [22,23]. We performed cannula repositioning in 1 case (20%) in the DLC group and in 1 case (14%) in the conventional group. We were able to reduce the procedure time and perform repositioning without complications when implanting the DLC. Additionally, we were able to use the DLC cannula as the drainage venous cannula when converting to VA ECMO in a case of RV failure (DLC5).

Speggorin et al. [8] reported late perforation of the cardiac wall as a mechanical complication, which led to emergency midline sternotomy in 6.9% of the DLC cases. The lesion in that case was found in the inferior cavo-atrial junction [8]. Moscatelli et al. [24] pointed out that retraction of the DLC tip to improve flow may have been related to the high rate of atrial perforation. To prevent late perforation, we performed echocardiography frequently, and no mechanical complications were reported in our study.

Anticoagulation-related complication is an important issue in the context of ECMO [8,24]. Bleeding complications were lower in the DLC group than in the conventional group (40% and 71.4%, respectively). However, circuit change was required more frequently in the DLC group. Therefore, a lower aPTT target is not recommended, though bleeding complications were relatively infrequent in the DLC group.

Since it was developed in 2009, the DLC has been used for pediatric patients with respiratory failure worldwide [24]. As shown by our center's results, we have found that DLC use facilitated proper oxygenation, gas exchange, and acceptable flow rate capable of lasting for long periods. Because the DLC is not yet commercially available in South Korea, we needed to complete several processes to obtain import permission from the Korean Food and Drug Administration for each DLC. However, it is not reasonable to wait for 2 months for a DLC to arrive from the United States in a case of rapidly progressing respiratory failure. Preparing DLCs in various sizes in Korea would allow them to be used for more pediatric patients with respiratory failure as a less invasive method with a lower risk of vascular injury.

This study has some limitations. This report has an observational and retrospective design. We were not able to obtain a DLC suitable for the body surface area of all patients. Because purchasing a DLC is difficult and expen-

sive, a cannula prepared for another patient was inserted into some emergent cases after obtaining parental consent. To overcome these limitations, the most important step is to officially import all sizes of the DLC. Finally, this study had a small sample size, which is a common weakness of Korean pediatric studies. Further prospective or randomized studies with large numbers of subjects are warranted.

In conclusion, DLC VV ECMO for pediatric patients with respiratory failure provided adequate ECMO flow rate with proper blood gas change and high durability. Therefore, VV ECMO using a DLC could be a good option to treat respiratory failure in pediatric patients with small femoral veins. However, more research is required on the use of the DLC in South Korea.

Conflict of interest

No potential conflict of interest relevant to this article was reported.

Acknowledgments

We would like to acknowledge our appreciation of Yoo Jung Jin for drawing Fig. 1.

Funding

This study was supported by a Grant of the Samsung Vein Clinic Network (Daejeon, Anyang, Cheongju, Cheonan; Fund no. KTCS04-137).

ORCID

Woojung Kim: <https://orcid.org/0000-0001-9530-8638>
 Hye Won Kwon: <https://orcid.org/0000-0002-4949-9688>
 Jooncheol Min: <https://orcid.org/0000-0001-9446-4903>
 Sungkyu Cho: <https://orcid.org/0000-0003-0492-2814>
 Jae Gun Kwak: <https://orcid.org/0000-0002-6375-1210>
 Woong Han Kim: <https://orcid.org/0000-0003-2837-7929>

References

- Bartlett RH, Gazzaniga AB, Huxtable RF, Schippers HC, O'Connor MJ, Jefferies MR. *Extracorporeal circulation (ECMO) in neonatal respiratory failure*. J Thorac Cardiovasc Surg 1977;74:826-33.
- Short BL, Walker LK, Traystman RJ. *Impaired cerebral autoregulation in the newborn lamb during recovery from severe, prolonged hypoxia, combined with carotid artery and jugular vein ligation*. Crit Care Med 1994;22:1262-8.
- Carpenter JL, Yu YR, Cass DL, et al. *Use of venovenous ECMO for neonatal and pediatric ECMO: a decade of experience at a tertiary children's hospital*. Pediatr Surg Int 2018;34:263-8.
- Bermudez CA, Rocha RV, Sappington PL, Toyoda Y, Murray HN, Boujoukos AJ. *Initial experience with single cannulation for venovenous extracorporeal oxygenation in adults*. Ann Thorac Surg 2010;90:991-5.
- Javidfar J, Brodie D, Wang D, et al. *Use of bicaval dual-lumen catheter for adult venovenous extracorporeal membrane oxygenation*. Ann Thorac Surg 2011;91:1763-9.
- Kim H, Yang JH, Cho YH, Jun TG, Sung K, Han W. *Outcomes of extracorporeal membrane oxygenation in children: an 11-year single-center experience in Korea*. Korean J Thorac Cardiovasc Surg 2017;50:317-25.
- Clavien PA, Barkun J, de Oliveira ML, et al. *The Clavien-Dindo classification of surgical complications: five-year experience*. Ann Surg 2009;250:187-96.
- Speggorin S, Robinson SG, Harvey C, et al. *Experience with the Avalon(R) bicaval double-lumen veno-venous cannula for neonatal respiratory ECMO*. Perfusion 2015;30:250-4.
- Berdajs D. *Bicaval dual-lumen cannula for venovenous extracorporeal membrane oxygenation: Avalon(c) cannula in childhood disease*. Perfusion 2015;30:182-6.
- Extracorporeal Life Support Organization. *ECLS registry report: international summary*. Ann Arbor (MI): Extracorporeal Life Support Organization; 2018.
- Extracorporeal Life Support Organization. *ECLS registry report: international summary*. Ann Arbor (MI): Extracorporeal Life Support Organization; 2016.
- Rollins MD, Hubbard A, Zabrocki L, Barnhart DC, Bratton SL. *Extracorporeal membrane oxygenation cannulation trends for pediatric respiratory failure and central nervous system injury*. J Pediatr Surg 2012;47:68-75.
- Skinner SC, Hirschl RB, Bartlett RH. *Extracorporeal life support*. Semin Pediatr Surg 2006;15:242-50.
- Jarboe MD, Gadepalli SK, Church JT, Arnold MA, Hirschl RB, Mychaliska GB. *Avalon catheters in pediatric patients requiring ECMO: placement and migration problems*. J Pediatr Surg 2017;S0022-3468(17)30658-9.
- Hamilton HC, Foxcroft DR. *Central venous access sites for the prevention of venous thrombosis, stenosis and infection in patients requiring long-term intravenous therapy*. Cochrane Database Syst Rev 2007;(3):CD004084.
- Kuhl T, Michels G, Pfister R, Wendt S, Langebartels G, Wahlers T. *Comparison of the Avalon dual-lumen cannula with conventional cannulation technique for venovenous extracorporeal membrane oxygenation*. Thorac Cardiovasc Surg 2015;63:653-62.
- Fallon SC, Shekerdemian LS, Olutoye OO, et al. *Initial experience with single-vessel cannulation for venovenous extracorporeal mem-*

- brane oxygenation in pediatric respiratory failure. *Pediatr Crit Care Med* 2013;14:366-73.
18. Subramanian S, Vafaezadeh M, Parrish AR, McMullan DM. Comparison of wire-reinforced and non-wire-reinforced dual-lumen catheters for venovenous ECMO in neonates and infants. *ASAIO J* 2013;59:81-5.
 19. Lazar DA, Cass DL, Olutoye OO, et al. Venovenous cannulation for extracorporeal membrane oxygenation using a bicaval dual-lumen catheter in neonates. *J Pediatr Surg* 2012;47:430-4.
 20. Gow KW, Wulkan ML, Heiss KF, et al. Extracorporeal membrane oxygenation for support of children after hematopoietic stem cell transplantation: the Extracorporeal Life Support Organization experience. *J Pediatr Surg* 2006;41:662-7.
 21. Gow KW, Heiss KF, Wulkan ML, et al. Extracorporeal life support for support of children with malignancy and respiratory or cardiac failure: the extracorporeal life support experience. *Crit Care Med* 2009;37:1308-16.
 22. Salazar PA, Blitzer D, Dolejs SC, Parent JJ, Gray BW. Echocardiographic guidance during neonatal and pediatric jugular cannulation for ECMO. *J Surg Res* 2018;232:517-23.
 23. Ellis WC, Schafer M, Barrett CS, et al. Vascular anatomical considerations and clinical decision making during insertion of the Avalon(R) Elite Dual Lumen single-site veno-venous ECMO cannula in children weighing less than 20 kg. *Perfusion* 2019;34:267-71.
 24. Moscatelli A, Febbo F, Buratti S, et al. Intensivists performed percutaneous bicaval double-lumen echo-guided extracorporeal membrane oxygenation cannulation at bedside in newborns and children: a retrospective analysis. *Pediatr Crit Care Med* 2019;20:551-9.