

**IMAGES****Subtotal extended thigh flap**

Paolo Persichetti, Daniele Tosi,  
Pietro Francesco Delle Femmine,  
Giovanni Francesco Marangi

*Department of Plastic, Reconstructive and Aesthetic Surgery,  
Campus Bio-Medico of Roma University, Rome, Italy*

**Correspondence:** Daniele Tosi  
Department of Plastic, Reconstructive and Aesthetic Surgery, Campus Bio-Medico of Roma University, Via A. del Portillo 200, Rome 00128, Italy  
Tel: +39-6-225411224, Fax: +39-6-225411220, E-mail: tosi.da@gmail.com

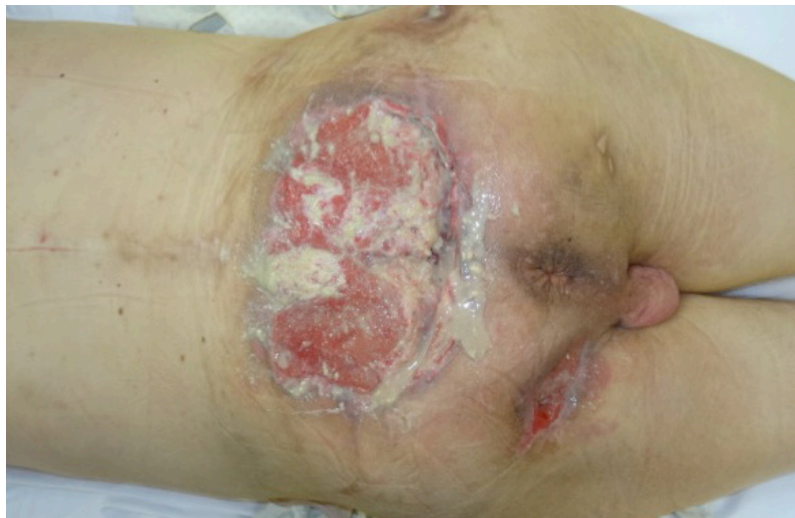Received: August 28, 2018 • Revised: June 29, 2019 • Accepted: July 9, 2019  
pISSN: 2234-6163 • eISSN: 2234-6171  
<https://doi.org/10.5999/aps.2018.01088>  
Arch Plast Surg 2020;47:106-107

Copyright © 2020 The Korean Society of Plastic and Reconstructive Surgeons  
This is an Open Access article distributed under the terms of the Creative Commons Attribution Non-Commercial License (<https://creativecommons.org/licenses/by-nc/4.0/>) which permits unrestricted non-commercial use, distribution, and reproduction in any medium, provided the original work is properly cited.

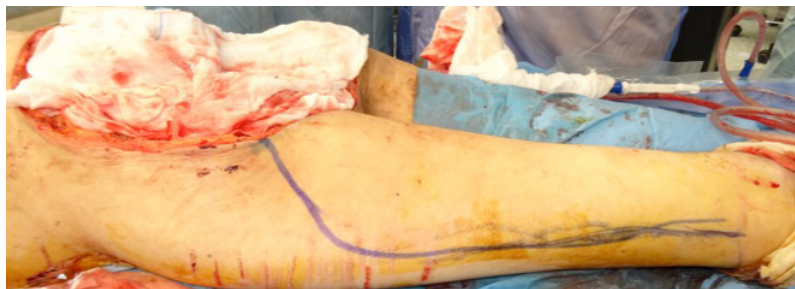In 2010, Chang et al. [1] reported closing a wound after hemipelvectomy using a bilateral subtotal thigh flap. We describe a subtotal extended thigh flap for a 42-year-old male quadriplegic patient who presented with a nonmetastatic Marjolin's ulcer (Fig.

1). Magnetic resonance imaging revealed that soft tissues, the coccyx, and the sacrum bone up to the S2 vertebra were involved.

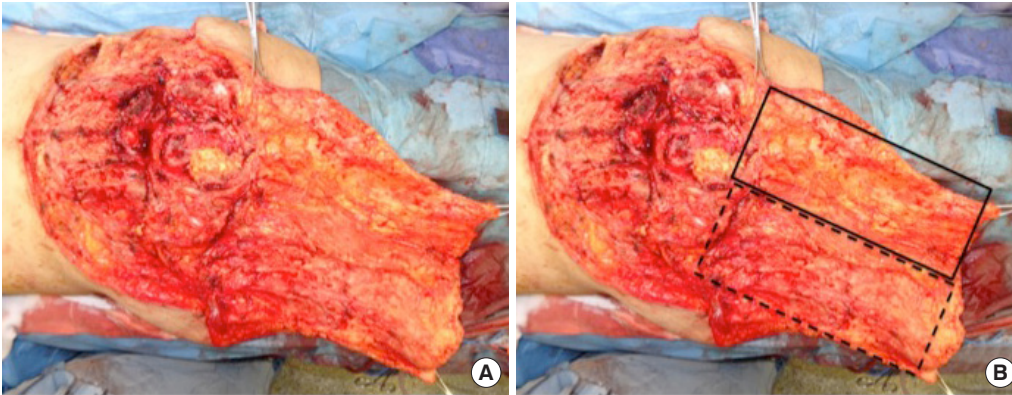
The only option for radical excision of the tumor was subtotal sacrectomy. Total sacral bone disarticulation between S1 and S2, ligation of the thecal sac, and removal of soft tissue and the residual gluteus muscles were performed. A posterolateral femur incision was made (Fig. 2). The popliteal vessels were ligated. Dissection was carried out through the posterolateral intermuscular thigh septum. The flap was harvested distally to proximally. The hamstring muscles were removed to avoid a bulk effect. We obtained a dually-structured flap, with a myo-fasciocutaneous portion (anterolateral side) and a fasciocutaneous portion (medial side) (Fig. 3). The anterolateral portion of the flap was vascularized by perforators from the superficial and deep femoral arteries, while the fasciocutaneous portion of the flap was supplied by perforators from the profunda femoris artery. The flap surface measured 50 × 38 cm (Fig. 4). The posteromedial component of the flap represented an extension of the flap that allowed the total flap surface to be increased; moreover, the fasciocutaneous component was vascularized by a



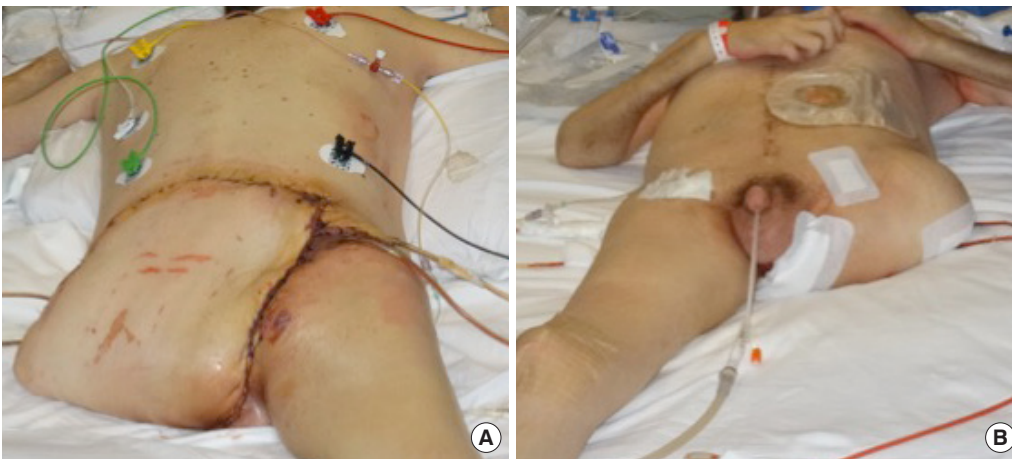
**Fig. 1.**  
Marjolin's ulcer on the sacral region involving the posterior surface of the sacral bone.



**Fig. 2.**  
Posterolateral femur cutaneous incision planned for harvesting the subtotal extended thigh flap.



**Fig. 3.** Subtotal extended thigh flap (A), containing a myofasciocutaneous anterolateral portion (solid line) and a fasciocutaneous medial portion (dashed line) (B).



**Fig. 4.** (A, B) Patient in the prone and supine positions during his 5th day in the intensive care unit.

well-known and secure pattern of perforators.

This modification of the original flap enabled the flap surface to be enlarged, which could be useful in extreme cases of total or subtotal sacral resection.

## Notes

### Conflict of interest

No potential conflict of interest relevant to this article was reported.

### Ethical approval

The study was approved by the Institutional Review Board of Campus Bio-Medico of Roma University and performed in accordance with the principles of the Declaration of Helsinki. Written informed consent was obtained.

### Patient consent

The patient provided written informed consent for the publication and the use of his images.

### Author contribution

Conceptualization: all authors. Data curation: Tosi D, Marangi GF. Formal analysis: Delle Femmine PF. Funding acquisition: all authors. Methodology: Persichetti P. Project administration: Persichetti P. Visualization: all authors. Writing original draft: Tosi D. Writing review and editing: Tosi D. Approval of final manuscript: all authors.

### ORCID

Paolo Persichetti <https://orcid.org/0000-0001-8857-6060>

Daniele Tosi <https://orcid.org/0000-0002-4894-206X>

Pietro Francesco Delle Femmine <https://orcid.org/0000-0003-2962-5576>

Giovanni Francesco Marangi <https://orcid.org/0000-0002-7179-3533>

## Reference

1. Chang DW, Lee JE, Gokaslan ZL, et al. Closure of hemicorporectomy with bilateral subtotal thigh flaps. *Plast Reconstr Surg* 2000;105:1742-6.