

Original Article
Medical Imaging



Ultrasound and clinical findings in the metacarpophalangeal joint assessment of show jumping horses in training

Ana Lúcia M. Yamada ^{1*}, Marcelo Pinheiro², Marília F. Marsiglia ¹,
Stefano Carlo F. Hagen¹, Raquel Yvonne A. Baccarin ³, Luís Cláudio L. C. da Silva ¹

¹Department of Surgery, School of Veterinary Medicine and Animal Science, University of São Paulo, São Paulo, SP 05508 270, Brazil

²Independant Veterinarian, Alameda do Parque 400, Jd Plaza Athene, Itu, SP 13302 225, Brazil

³Department of Clinical Medicine, School of Veterinary Medicine and Animal Science, University of São Paulo, São Paulo, SP 05508 270, Brazil

 OPEN ACCESS

Received: Aug 2, 2019

Revised: Oct 19, 2019

Accepted: Dec 16, 2019

*Corresponding author:

Ana Lúcia M. Yamada

Rua Eurico Gaspar Dutra, 255. Carapicuíba, SP 06342-200, Brazil.

E-mail: anamyamada@usp.br


© 2020 The Korean Society of Veterinary Science

This is an Open Access article distributed under the terms of the Creative Commons Attribution Non-Commercial License (<https://creativecommons.org/licenses/by-nc/4.0>) which permits unrestricted non-commercial use, distribution, and reproduction in any medium, provided the original work is properly cited.


ORCID iDs

Ana Lúcia M. Yamada 


<https://orcid.org/0000-0003-3856-0196>

Marília F. Marsiglia 

<https://orcid.org/0000-0002-8290-4040>

Raquel Yvonne A. Baccarin 

<https://orcid.org/0000-0001-9730-0840>

Luís Cláudio L. C. da Silva 

<https://orcid.org/0000-0002-9939-3611>

Funding

This research was supported by São Paulo State Research Support Foundation (Fundação de Amparo à Pesquisa do Estado de São Paulo–FAPESP process No. 2017/07255-5).

Conflict of Interest

The authors declare no conflicts of interest.

ABSTRACT

Background: Physical exercise is known to cause significant joint changes. Thus, monitoring joint behavior of athletic horses is essential in early disorders recognition, allowing the proper management.

Objectives: The aims of this study were to determine the morphological patterns, physical examination characteristics and ultrasound findings of show jumping horses in training and to establish a score-based examination model for physical and ultrasound follow-ups of metacarpophalangeal joint changes in these animals.

Methods: A total of 52 metacarpophalangeal joints from 26 horses who were initially in the taming stage were evaluated, and the horses' athletic progression was monitored. The horses were evaluated by a physical examination and by B-mode and Doppler-mode ultrasound examinations, starting at time zero (T0), which occurred concomitantly with the beginning of training, and every 3 months thereafter for a follow-up period of 18 months.

Results: The standardized examination model revealed an increase in the maximum joint flexion angles and higher scores on the physical and ultrasound examinations after scoring was performed by predefined assessment tools, especially between 3 and 6 months of evaluation, which was immediately after the horses started more intense training. The lameness score and the ultrasound examination score were slightly higher at the end of the study.

Conclusions: The observed results were probably caused by the implementation of a training regimen and joint adaptation to physical conditioning. The joints most likely undergo a pre-osteoarthritic period due to work overload, which can manifest in a consistent or adaptive manner, as observed during this study. Thus, continuous monitoring of young athlete horses by physical and ultrasound examinations that can be scored is essential.

Keywords: Equine; jumping horse; metacarpophalangeal joint; lameness; osteoarthritis; ultrasound imaging

INTRODUCTION

Among jumping horses, especially those that are trained for competitions, there is a high incidence of orthopedic injuries, including joint injuries. This high incidence of injuries can be

Author Contributions

Conceptualization: Yamada ALM, Silva LCLC;
Data curation: Yamada ALM, Pinheiro M;
Funding acquisition: Yamada ALM, Silva LCLC; Investigation: Yamada ALM, Marsiglia MF, Pinheiro M; Methodology: Yamada ALM, Baccarin RYA, Hagen SCF; Project administration: Silva LCLC; Supervision: Yamada ALM, Silva LCLC; Validation: Baccarin RYA, Hagen SCF; Writing - original draft: Yamada ALM, Marsiglia MF; Writing - review & editing: Yamada ALM, Marsiglia MF.

explained by the high performance and the intense and long training times required for jumping horses involved in competitions [1,2]. Moreover, the repetitive trauma and impact resulting from the execution of jumping movements overload the distal structures of the thoracic limbs, and the metacarpophalangeal joints, flexor tendons and hooves are the areas that are most affected by injuries [2]. The metacarpophalangeal joint, which is commonly called the fetlock, is constantly subjected to maximum exertion, which causes a large amount of biomechanical stress during locomotion, resulting in frequent injury to the soft tissue and articular surface [3,4]. Therefore, horses who perform sports activities that overload the metacarpophalangeal joint are at risk for the development of osteoarthritis and require periodic follow-ups, preferably follow-ups that involve imaging examinations and rigorous physical assessments, for the early detection of disorders [5,6].

The early stages of osteoarthritis, including pre-osteoarthritis, can manifest even in inexperienced animals, especially after a phase of sports conditioning adaptation or after periods of training [7,8]. Both pre-osteoarthritis and adaptive changes can occur without obvious clinical signs [8-10]. Most athletes can adjust to exercise regimens or increases in exercise intensity. However, the articular cartilage seems unable to completely recover from constant trauma resulting from exercise and can enter an inflammatory and degenerative cycle that culminates in clinical and progressive presentations of the disease [8,11,12]. Therefore, a combination of diagnostic tools is important for detecting and following up early changes [9,13]. Furthermore, diagnostic tools and evaluation protocols need to be standardized and validated, preferably through noninvasive and inexpensive methods [14,15].

Serial physical and imaging examinations can identify joint changes or injuries in the early stages, enabling a better understanding of the pathogenesis, characterizing the initial presentation and the progression of diseases such as osteoarthritis, and allowing early therapeutic intervention [6,9,10,16]. Ultrasound is a tool that is important for assessing various segments of the metacarpophalangeal joint and is essential for detecting changes and providing diagnostic conclusions [3,4,17]. Recent technological advancements and the proximity of the metacarpophalangeal joint to the surface allow detailed images of soft tissues to be obtained [18] and early inflammatory changes, bone injuries and irregularities, and the structure and alignment of tendons and ligaments to be visualized [19-21].

Thus, an ultrasound study of the metacarpophalangeal joint in horses who underwent show jumping training was performed to identify morphological patterns, relevant variables, and other ultrasound findings. Furthermore, the ultrasound examination was combined with a detailed physical examination to monitor the behavior of this joint in horses undergoing athletic progression. Finally, the present study proposes a score-based examination model that incorporates both physical and ultrasound monitoring results of the metacarpophalangeal joint and indicates the consequences of high-performance exercise adaptation and practice.

MATERIALS AND METHODS

Animals

This study was approved by the Ethics Committee on Animal Use of the School of Veterinary Medicine and Animal Science at the University of São Paulo under protocol number 8840030417. This study evaluated 52 metacarpophalangeal joints from both thoracic limbs of 26 female and male show jumping horses who were between 3 and 4 years of age and weighed between 450 and 700 kg.

Initially, the horses did not present with any type of musculoskeletal condition and did not previously show metacarpophalangeal joint changes or diseases. Before the study began, to determine the experimental group, all possible entrants were submitted to a rigorous physical examination, radiographic examination (5 projections were performed: lateromedial, dorsopalmar, oblique, and lateral-flexed) and ultrasound screening. The horses did not show any underlying diseases. Only horses without injuries on the radiographic and ultrasonographic examinations and without clinical disorders of the metacarpophalangeal joint were included in the study. The horses were included in the study when they were at the beginning stage of a training program for jumping competitions, and their athletic progression was monitored. During the follow-up period, the training phases, the type and duration of the exercises, and the physical condition of the animals were standardized (as much as possible) to better study the response of a group of young animals to physical exercise and assess the joint conditions over the course of athletic progression.

Thus, all joints underwent a detailed physical examination and an ultrasound examination at the time of inclusion in the study, defined as time point zero (T0), and every 3 months thereafter, for a total follow-up time of 1 and a half years and a total of 7 evaluation time points (T0–T6). At the end of the study (after 18 months/T6), the horses were between 4.5 and 5.5 years old and were frequently participating in show jumping events.

Physical examination

The physical examination was performed at T0 and every 3 months thereafter for 1.5 years (T0–T6) for all 52 joints. The physical examination results were scored using a scale ranging from 0 to 21 points, with was modified from a previous score-based examination protocol [15], as described in **Table 1**. For the items “maximum flexion angle decrease” and “joint perimeter increase,” the differences between the value of the parameter obtained at T0 and the values obtained at the following time points (T1 to T6) were scored. The parameter values at T0 were considered the baseline values from which the differences between the evaluations were calculated. For the items “lameness,” “response to flexion test” and “changes on local palpation,” the changes observed separately at each time point were scored.

In the lameness examination, both thoracic limbs were evaluated and scored according to the American Association of Equine Practitioners (AAEP) scale, which ranges from 0 to 5 [22]. This examination was supplemented by a complementary classification, which provided a score from 0 to 10 [23]; the complementary evaluation was necessary because horses can have a tendency to show very discrete degrees of lameness. The joints were subjected to forced flexion tests for 1 min, followed by trotting. If there was exacerbation of lameness following the flexion test, the level of lameness was scored again (AAEP score). The joint angle was measured in degrees with a goniometer, and the examined joint was flexed to the physical limit or to the demonstration of pain sensitivity. Likewise, during the physical examination, the presence of synovial effusion was determined by digital palpation and the consequent degree of joint distension, measured as the joint perimeter using a tape measure. The joints were also palpated and examined for the presence of pain, crepitation and abnormal joint mobility.

Ultrasound examination

The 52 metacarpophalangeal joints included in the study were evaluated by ultrasound (6 to 18 MHz linear transducer, MyLab30 Vet ultrasound machine; Esaote, Italy) in B mode and Doppler mode, performed at T0 and every 3 months thereafter for one and a half years (T0–T6). The

Table 1. Score-based physical examination protocol

Variables	Categories	Score
Lameness (AAEP)	0	0
	1	1
	2	2
	3	3
	4	4
	5	5
Response to the flexion test	Negative	0
	Positive + 1 degree	1
	Positive + 2 degrees	2
	Positive + 3 degrees	3
	Limb functional impotence	4
Decrease in maximum flexion angle (in degrees)	≤ to 5°	0
	6° to 10°	1
	11° to 15°	2
	16° to 20°	3
	≥ to 20°	4
Increase in joint perimeter (in cm)	≤ 0.5 cm	0
	0.6 to 2.0 cm	1
	2.1 to 4.0 cm	2
	4.1 to 6.0 cm	3
	≥ 6.1 cm	4
Changes upon local palpation	Normal	0
	Mild reaction	1
	Moderate discomfort and/or mild change in mobility	2
	Moderate discomfort and/or moderate change in mobility	3
	Significant discomfort and/or abnormalities of mobility, crepitation	4
Total (final sum)		21

Physical examination protocol used a scale ranging from 0 to 21 points (final sum) and considered the lameness examination (0 to 5 points according to the AAEP score [22]), response to the flexion test (score after the forced flexion test, AAEP score), decrease in the maximum flexion angle (metacarpophalangeal joint angle measurement, based on T0), increase in the joint perimeter (based on T0) and changes upon local palpation. AAEP, American Association of Equine Practitioners.

ultrasound examination was always performed by the same evaluator, who had the experience needed to conduct the study.

In this evaluation, all articular surfaces were evaluated in both the longitudinal and transverse planes, and the joint was supported and flexed. The ultrasound images were assigned scores ranging from 0 to 38 points [15], as described in **Table 2**. The following items were evaluated: the appearance and amount of synovial fluid; thickness and insertion of the joint capsule; appearance and vascularization of the capsule and synovial membrane; appearance and thickness of the synovial plica; appearance of the articular and periarticular ligaments (collateral ligaments, suspensory ligaments, and oblique sesamoidean ligaments); thickness and appearance of the chondral surface; appearance and regularity of the subchondral bone; and presence of osteophytes and enthesophytes. The structures of the metacarpophalangeal joint were measured at one time, at T0 only, so that the standard morphological values in healthy horses could be obtained.

Statistical analysis

The analyses were performed in SPSS 21.0 (IBM SPSS Statistics for Windows, Version 21.0; IBM Corp., USA) [24]. A descriptive statistical analysis of the data was first performed by calculating the mean and standard deviation of the scores and angles at each time point. The Shapiro-Wilk test was then used to test the normality of the data distributions and based on these results (Shapiro-Wilk *p* values were < 0.001 for the angles and scores), nonparametric tests were used for the analyses. The differences between the time points were assessed using the Friedman test, followed by the Wilcoxon test. The differences were considered significant when *p* < 0.05.

Table 2. Classification and scoring of each evaluated parameter in the ultrasound examination using a scale ranging from 0 to 38 points (final sum)

Variables	Categories	Score
Synovial fluid appearance	Normal	0
	Anechoic	1
	Predominantly anechoic	2
	Predominantly heterogeneous	3
	Heterogeneous with hyperechoic floating foci/debris	4
Synovial fluid amount	Normal	0
	Increased +	1
	Increased ++	2
	Increased +++	3
	Increased ++++	4
Joint capsule thickness	Normal	0
	Increased by 20% in localized areas	1
	Increase	2
	Increase by more than 20%	3
Joint capsule appearance	Normal	0
	Localized hypoechoic area	1
	Hypoechoic areas with hyperechoic foci	2
Joint capsule insertion	Smooth	0
	Discretely irregular	1
	Irregular	2
	Severe irregularity	3
Appearance of periarticular ligaments	Normal	0
	Heterogeneous and/or hypoechoic areas	1
	Heterogeneous and/or hyperechoic areas	2
	Massive injury or rupture	3
Origin and insertion of articular/periarticular ligaments	Normal	0
	Presence of irregularities	1
	Discrete bone proliferation	2
	Severe bone proliferation	3
	Severe bone proliferation and/or fragments	4
Synovial vascularization	Normal	0
	Slightly increased vascularization	1
	Increased vascularization	2
Joint cartilage thickness and appearance	Well-defined, continuous chondral line, smooth and easily identifiable	0
	Difficult-to-identify chondral line with 50% of surface preserved	1
	Difficult-to-identify chondral line, discontinuous and rough	2
	No identification of the line with presence of fragments	3
	Absence of the line with diffuse subchondral alteration	4
Subchondral surface appearance	Smooth	0
	Irregular	1
	Areas of depression	2
Synovial plica appearance	Normal	0
	Predominantly hyperechoic	1
	Hyperechoic calcification sites	2
Synovial plica size	Normal	0
	Increased up to 50%	1
	Increased by more than 50%	2
Presence of subchondral osteophytes	Smooth joint margin	0
	Rough joint margin	1
	Presence of osteophytes	2
	Evident osteophytes or fragments	3
Total (final sum)		38

RESULTS

At the beginning of this study, there were 26 horses of the Brazilian Sport Horse breed who were stabled in horse farms and training centers in São Paulo, Brazil. Some of the

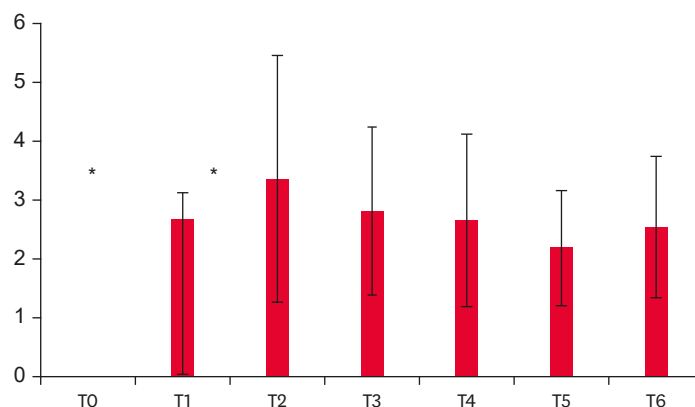


Fig. 1. Mean values observed after classification of the physical examination (score-based physical examination protocol, classified using scores ranging from 0 to 21 points – **Table 1**) at all time points (T0–T6).

*There was a significant difference ($p < 0,05$) between T0 and the other time points and between T1 and T2.

youngest horses had been stabled recently. At T0, the horses were beginning a dressage and show jumping training program that included obstacles on a track, but they had not yet participated in a competition. At the end of the study (at T6), most animals had completed intense training and were participating regularly in show jumping events.

Fig. 1 summarizes the physical examination classifications based on the joint scores (mean of the sum, **Table 1**). The baseline values for the study were a flexion angle = 140° and joint perimeter = 28.5 cm (mean of animals at T0). At T1, only 10 animals showed mild pain sensitivity upon palpation of the joint, with a mild degree of effusion. A significant difference was found ($p < 0.05$) between the mean of the sum of the scores obtained at T0 and the mean of the sum of scores obtained at other time points. There was also a significant difference in the mean sum of the scores between T1 and T2. After T2, the scores remained more consistent, with no significant differences. Among the time points, T2 showed the highest sum score, and the maximum value corresponding to one of the joints reached 8 points out of the overall total of 21 points. T0 and T1 were the time points with the lowest scores, with a minimum of zero points. The physical examination parameter that showed the highest score per animal was the maximum flexion angle, where the highest angle was 160° and the lowest was 124° . The joint perimeter and changes upon palpation did not show significant differences between the analyzed times.

The mean maximum flexion angles observed are shown in **Table 3** and **Fig. 2**. The joint angle results followed the same statistical trend as the sum of the scores observed after the physical examination, with higher values mainly occurring after T2 and more consistent values occurring after thereafter. The joints examined showed discrete degrees of lameness, and the highest score on the AAEP scale was 2. In the complementary classification ranging from 0 to 10, the highest score was 3, and forced flexion increased the degree of lameness by a maximum of 2 points. The lameness scores were higher at the end of the study, after T5. **Fig. 3** shows the mean lameness values over time.

The most commonly observed ultrasound changes are shown in **Fig. 4** and are summarized as follows: osteochondral irregularities, increased and heterogeneous plica, increased thickness of the joint capsule, synovitis with increased vascularization observed by Doppler ultrasound, and collateral ligament abnormalities. The T0 measurements that were obtained in the ultrasound examination of the metacarpophalangeal structures for use as standard reference

Table 3. Measured value of maximum flexion angles measurement observed at all time points (T0–T6)

Time points	Angle		
	Mean \pm SD	Median	Percentile 25%–75%
T0	139.7 \pm 8.2 ^a	140 ^a	134–146
T1	142.7 \pm 8.3 ^b	144 ^b	137–149
T2	148.5 \pm 5.3 ^c	150 ^c	146–151
T3	146.8 \pm 4.3 ^{de}	148 ^{de}	144–149
T4	147.9 \pm 3.9 ^{cd}	147 ^{cd}	145–150
T5	146.3 \pm 3.3 ^e	147 ^e	144–149
T6	144.2 \pm 3.9 ^b	144 ^b	142–148
<i>p</i> value*	< 0.001		< 0.001

**p* value of the Friedman test (nonparametric analysis of variance for repeated measures); different letters represent significant differences between time points.

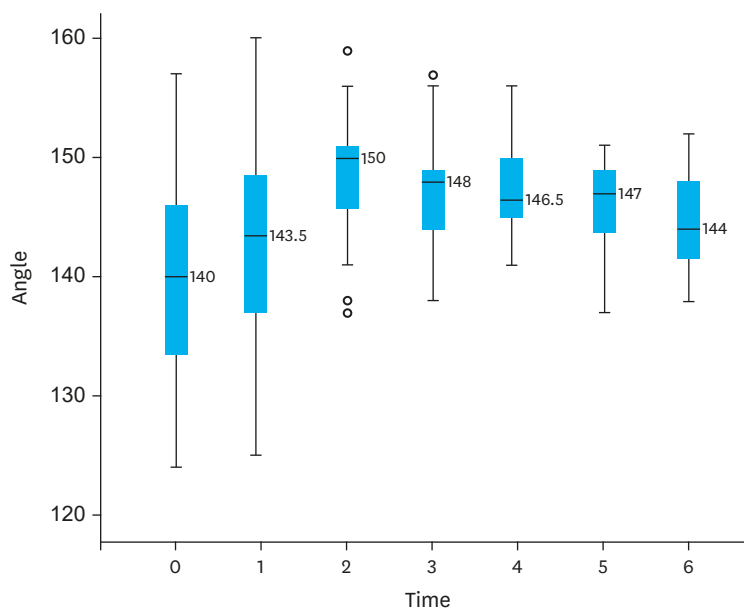


Fig. 2. Comparison of the median flexion angle values. The boxes represent the variability of the data. The lower end of the box corresponds to the value of 25% of the sample, the upper end corresponds to 75% of the sample, and the centerline is the median (50% of the samples).

° indicates the presence of outliers.

values in healthy animals are described in **Table 4**. In the multiple comparisons, for the sum of the ultrasound injury scores, as previously described (mean of the sum, **Table 2**), the scores were significantly lower at T0 than at all other time points, with the exception of T2. However, from T1 onward, there were no significant differences, as shown in **Table 5** and **Fig. 5**.

It is important to highlight that most of the ultrasonographic findings were mainly observed after T1. At the beginning of the training program (between T1 and T2), most of the Doppler ultrasound results presented synovitis with increased vascularization, increased and heterogeneous plica and an increased thickness of the joint capsule. Increased vascularization of the capsule and synovium, as observed with Doppler ultrasound, was a common finding in the joints with higher maximum flexion angles and positive forced flexion test results, and it was correlated with abnormalities in the synovial membrane, synovial fluid, and plica appearance. After T3, the findings from the ultrasonographic examination were most frequently associated with osteochondral irregularities and collateral ligament abnormalities. Nevertheless, after T3, many joints also showed increased vascularity. Radiographic

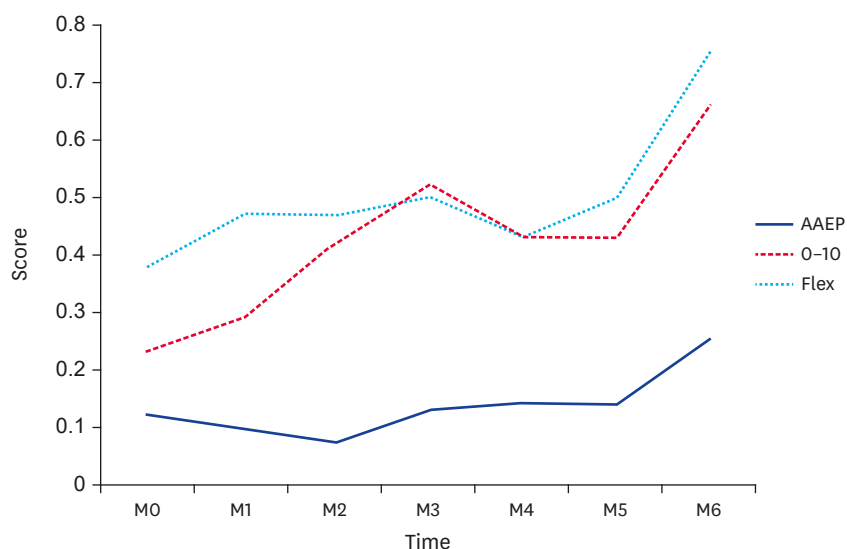


Fig. 3. Mean of the lameness scores for the AAEP scores ($p = 0.331$), 0-10 complementary score ($p = 0.124$), and after forced flexion (Flex) ($p = 0.321$) during the study period (T0- T6). There was no statistical difference in the evaluated scores. AAEP, American Association of Equine Practitioners.

examinations were performed as supplements to the ultrasonographic examinations to obtain data that can provide answers to any questions that may arise during the exams. However, no significant differences were observed in the results of the follow-up radiographic examinations.

DISCUSSION

Musculoskeletal disorders, including osteoarthritis, which is characterized by progressive and disabling symptoms, are common in sport horses. Articular cartilage degradation is

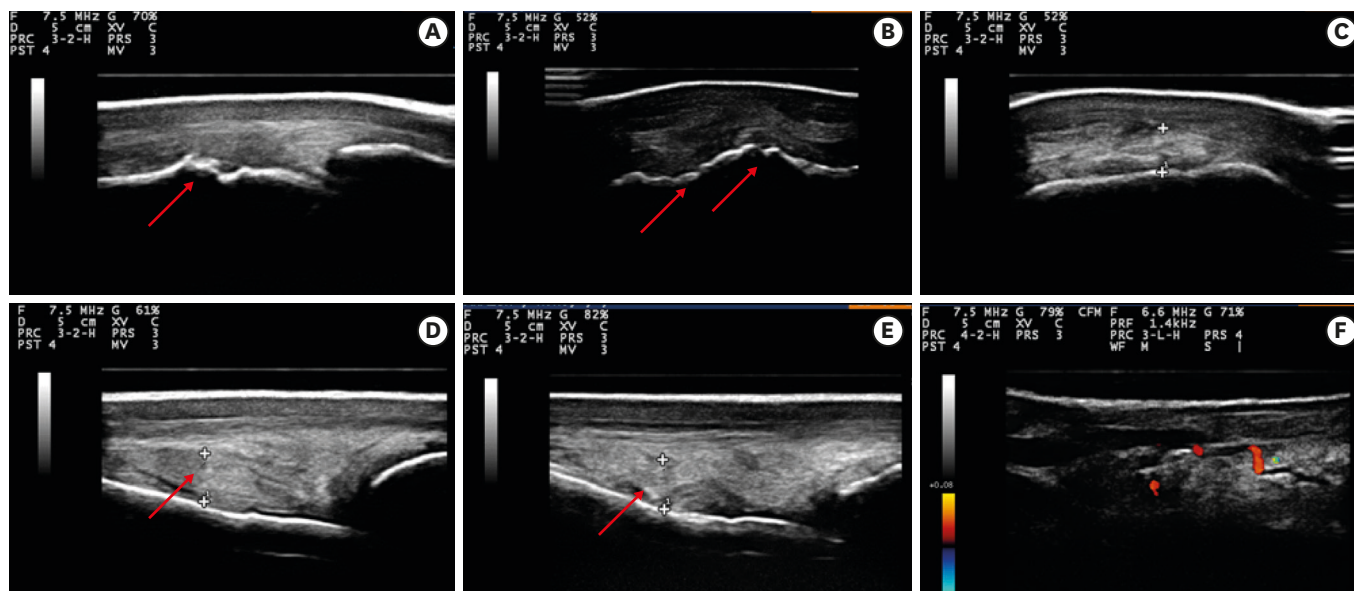


Fig. 4. Ultrasound images showing the primary observed changes: osteochondral irregularities in the articular surface of the main metacarpal bone (arrows in A and B); articular capsule heterogeneity (C); increased and heterogeneous plica (arrows in D and E) and synovitis and increased vascularization (F).

Table 4. Values of the morphological patterns observed in the T0 ultrasound examination

Variables	Mean (cm)	SD
CP M	0.646	0.135
CP L	0.590	0.108
CP IN MT	0.342	0.068
CP IN PH	0.266	0.073
CA TK M	0.104	0.025
CA TK L	0.080	0.020
CA TK CR	0.115	0.040
CL L PO	0.408	0.069
CL L PI	0.464	0.068
CL M PO	0.430	0.077
CL M PI	0.428	0.073
PLICA	0.308	0.067
ANNULAR	0.192	0.034
FSL L	1.413	0.347
FSL M	1.584	0.359

Thickness of the joint capsule in the transverse plane at the medial/lateral third metacarpal bone (CP M/CP L); thickness of the joint capsule insertion in the transverse plane in the third metacarpal bone (CP IN MT) and in the transverse plane in the first phalanx (CP IN PH); thickness of the joint cartilage in the transverse plane in the medial/lateral condyles/sagittal crest (CA TK M/CA TK L/CA TK CR); cross-sectional area of the fetlock suspensory ligament medial/lateral branches (FSL M/FSL L); thickness in the longitudinal plane of the medial/lateral collateral ligaments (CL M/CL L) at origin (PO) and insertion (PI); plica thickness (PLICA); and annular ligament thickness (ANNULAR).

Table 5. Measured value of values observed in the ultrasound exam (ultrasound examination using scores ranging from 0 to 38 points – **Table 2**) at all time points (T0–T6)

Time points	Score		
	Mean \pm SD	Median	Percentile 25–75%
T0	2.1 \pm 1.5 ^a	2 ^a	1–3
T1	3.3 \pm 2.1 ^b	3 ^b	2–5
T2	3.1 \pm 2.7 ^{ab}	2 ^{ab}	1–5
T3	3.4 \pm 2.2 ^b	3 ^b	2–4
T4	3.6 \pm 2.8 ^b	3 ^b	1–6
T5	4.1 \pm 2.3 ^b	4 ^b	2–5
T6	4.4 \pm 2.1 ^b	5 ^b	3–6
<i>p</i> value*	< 0.001		< 0.001

**p* value of the Friedman test (nonparametric analysis of variance for repeated measures); different letters represent significant differences between time points.

associated with changes in the subchondral bone and soft tissues in this disease, which results in economic losses and a significant reduction in athletic horse performance [11,25]. Thus, there is a growing demand for the detection of osteochondral degeneration and inflammatory processes in early osteoarthritis, where cell damage and molecular and enzymatic changes typically manifest first [9,16]. Given the importance of the cyclical trauma caused by sporting practices [11], it is essential to identify patients who are at risk of osteoarthritis to initiate early treatment when it is still possible to circumvent the destructive and disabling effects of osteoarthritis [16].

Therefore, this study aimed to describe the findings of early metacarpophalangeal joint disease resulting from training implementation. Predefined score tables were used successfully, which connected the ultrasound and physical examination results. The most striking result that emerged was that some joints undergo a period of overload adaptation and exercise adjustment, while others may or may not progress to pre-osteoarthritis or osteoarthritis. The metacarpophalangeal joint was chosen as the object of study because it is known that this structure is frequently affected by osteoarthritis in jumping horses due to the stress applied to it and its wide range of motion [2,26]. Furthermore, it is particularly

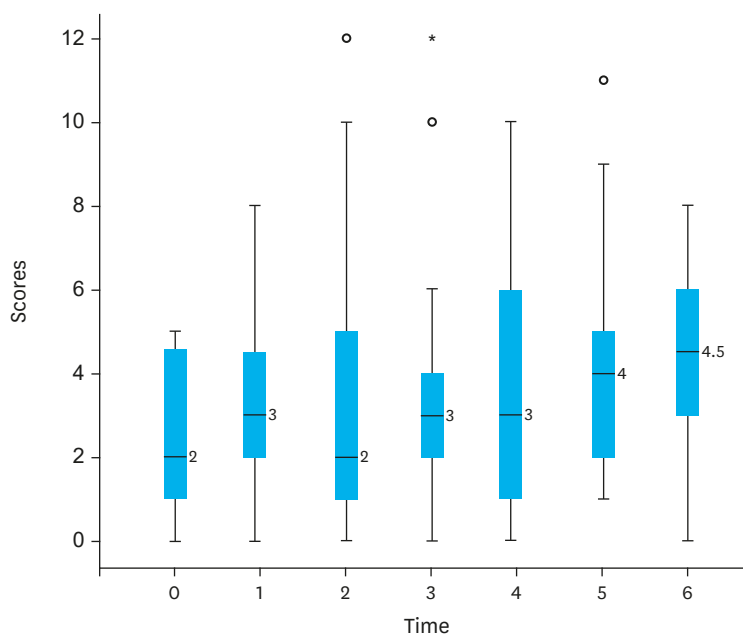


Fig. 5. Median values observed after classification of the ultrasound exam (ultrasound examination using scores ranging from 0 to 38 points - **Table 2**) at all time points (T0-T6). The boxes represent the data variability. The lower end of the box corresponds to the value of 25% of the sample, the upper end corresponds to 75% of the sample, and the centerline is the median (50% of the samples).

* and ° indicate the presence of outliers.

susceptible to chondral damage, especially on the dorsal surface, and it is also predisposed to ligament injuries due to hyperextension [2,26,27].

The horses evaluated in our study showed clear changes in the evaluated parameters. For example, there was a lower ability to flex the joint and higher scores on the physical examination at the time points following the start of training. We assume that these clinical findings most likely result from the joint adapting to training and that they may indicate an accumulated injury risk. It is well known that permanent changes in the joint structure, especially of the chondral tissue, may be triggered by the imposition of physical exercise on young animals, depending on the amount and type of exercise [28]. Nevertheless, progressive training is necessary because it promotes joint adaptation and development and accelerates the maturation of the joint, preparing it for work overload. However, it should be noted that there seems to be a delicate balance between the changes expected during the exercise adaptation process and the onset of osteoarthritis [28,29].

It is widely known that sports training results in an inflammatory response in the joints, with increased chondral degradation, the release of various catabolic enzymes and the involvement of pro-inflammatory factors [8,29]. However, it is expected that the joints will adjust to the physiological needs imposed by exercise [29]. Consequently, during the study, the physical examination findings that reflect a worsening in the joint condition observed mainly after 6 months of training (T2) may be transient. Depending on the training (and rest periods) and proper athlete monitoring, this transient condition has a high possibility of progressing to osteoarthritis [29]. Thus, even if joints have the ability to sustain work overload, they are likely to undergo periods of greater degradation, which may be related to the development of pre-osteoarthritis or early osteoarthritis, as the training program can

induce significant and progressive changes in the chondral biochemical composition [28]. The practice of exercise with repetitive trauma resulting from impacts significantly increases the onset of joint injuries and the development of degenerative joint diseases [27,30].

The joints monitored in this study showed, after a period of increased joint change (T1/T2) demonstrated by higher scores in the physical and ultrasound examinations, a stabilized joint condition, which suggests an adaptation or partial recovery of joint health. However, the lameness scores increased over time, which may indicate that some overload changes became permanent. The intensity and frequency of training of jumping horses, corresponding to a high degree of exercise performed by these animals, can significantly contribute to the development of joint injuries, and it is always necessary to respect and observe the recommended limits to maintain joint and tissue health [2,31]. The idea that some animals may not recover from the exercise adjustment phase and may develop pre-osteoarthritis and consequently osteoarthritis should be considered. However, the imposition of mild to moderate training programs seems to protect the joints, even in young animals, through the mechanical stimulation of chondrocytes [32], and it is important to highlight that any exercise intensity affects the extracellular matrix and the chondrocytes [28,33].

In addition to sports overload, other factors may predispose patients to joint injury. Genetic predisposition and environmental influences are the 2 primordial factors [9,16]. The experimental group of this study was uniform and was composed of Brazilian Sport Horses, which facilitated the standardization and process of comparing the parameters and scores. In addition, this study monitored the animals using easily applicable methods, the horses were housed in stud farms and training centers, and the horses participating in an athletic training program that is regularly used by the equestrian community. However, environmental factors, such as the type of diet, track quality and frequency of training, can induce the development of osteochondral changes [10,16]. Therefore, both genetic influences and environmental factors should be considered when joint changes are observed, especially in young horses and during the training period. However, these issues were not considered and were not the objective of this study, as such an investigation would be complex due to the heterogeneous origin of the animals.

When using ultrasound to monitor and diagnose joint diseases, especially osteoarthritis in its early stages, it is indispensable to have full anatomical knowledge of the joint, along with mastery of the ultrasound technique [4,34] and the science of morphological patterns [15], which were obtained at T0 in this study. During the evaluation, it is ideal to establish an injury score to describe the severity of the findings, preferably one that is associated with the physical examination or other imaging exams, thus enabling adequate monitoring of the patient and correlations with the treatment results [15].

During our study, in addition to the high physical examination scores, a series of ultrasound changes was also observed, such as osteochondral irregularities, changes related to the joint capsule, and plica and synovial vascularization. These results can be explained once it is known that exercise causes deleterious effects on the synovial membrane, such as thickening, increased vascularization and synovial proliferation [28,29]. Furthermore, pro-inflammatory molecules are released into the synovial fluid of horses subjected to exercise [28,29], and bone remodeling and chondral degradation can also be observed [12].

In addition, our study enabled the correlation of ultrasound findings with physical examination results. During the 18-month follow-up period, the joints showed a higher frequency of positive responses on the flexion test at the end of the study after T5. The lameness scores also increased over time. The changes described in the literature resulting from the imposition of exercise, such as lameness, positive responses on the flexion test, ultrasound changes in the subchondral bone and chondral tissue and increased vascularization [7,8,12,27,29,35], were increasingly observed from T0 to T2. Thus, more studies need to be conducted to understand the potential of joint recovery and prevent constant degradation, taking into account the amount of training imposed and possible therapeutic interventions. Therefore, thorough monitoring of athletic horses is highly important.

The ultrasound findings were also consistent with the changes found in metacarpophalangeal osteoarthritis [21,34] and were in agreement with the results of the physical examination. The ultrasound results reinforce the idea that the animals enter a period of articular degradation, or pre-osteoarthritis, after the imposition of physical exercise. Thus, the clinical and ultrasound monitoring of athlete horses is essential, and there is an obvious risk of developing joint diseases [9,16]. It is possible to modulate tissue adaptation to physical effort and to detect injuries early [9,31]. Therefore, we must try to identify which injuries are reversible (i.e., those resulting from possible joint adaptation) and which injuries may be irreversible. In addition, the workload can also be adjusted, and early therapy interventions can be initiated.

Several diagnostic tests have been validated for the detection of osteoarthritis. However, in our study, ultrasound enabled the visualization and standardization of joint structure measurements, which improved the scoring system efficiency and provided an accurate examination of these horses. Therefore, ultrasound examinations are highly relevant in proposed joint assessment protocols. The scoring system based on clinical examinations and imaging methods was essential for standardization and obtaining accurate and predictive information, which thereby demonstrated the accuracy of ultrasound monitoring in a standardized model and the importance of a scoring system combined with a lameness assessment [15].

In conclusion, the horses showed visible changes primarily between 3 and 6 months after the onset of physical exercise, and the changes were evident in physical and ultrasound examination scores and articular angles. The worsening joint conditions most likely resulted from the adjustments and adaptations to exercise resulting from work overload. The ultrasound examination and lameness scores were slightly higher at the end of the study, suggesting that the changes observed after the implementation of exercise may be permanent or progressive and lead to a pre-osteoarthritis or early osteoarthritis stage. However, the horses also showed consistency in a portion of the findings during the follow-up period, indicating that this phase can also be part of an adaptive period in the long term. The proposed examination model, based on the scores, was shown to be adequate for following up athletic horses. Therefore, continuous clinical and ultrasound monitoring of the behavior of this joint in young athletic horses is critical, and it is essential to use an appropriate examination model that can be scored to identify early changes and individuals who are at risk. Further studies are encouraged to delimit the probable period of adaptation to exercise or pre-osteoarthritis onset. This information may help clarify the situations in which this condition progresses to the disease and correlate the intensity of the work and the response of each joint, thus allowing early therapeutic interventions and training adjustments to be implemented.

ACKNOWLEDGMENTS

We thank the São Paulo State Research Support Foundation (Fundação de Amparo à Pesquisa do Estado de São Paulo–FAPESP) process No. 2017/07255-5 and the University of São Paulo School of Veterinary Medicine and Animal Science.

REFERENCES

1. Murray RC, Dyson SJ, Tranquille C, Adams V. Association of type of sport and performance level with anatomical site of orthopaedic injury diagnosis. *Equine Vet J Suppl* 2006;38:411-416.
[PUBMED](#) | [CROSSREF](#)
2. De Sousa NR, Luna SP, Pizzigatti D, Martins MT, Possebon FS, Aguiar AC. Relation between type and local of orthopedic injuries with physical activity in horses. *Cienc Rural* 2017;47:1-7.
[CROSSREF](#)
3. De Bastiani G, de La Côte FD, Brass KE, Kommers GD, Denoix JM. Association of ultrasound and anatomopathologic findings of equine metacarpophalangeal lesions. *J Equine Vet Sci* 2014;34:1218-1225.
[CROSSREF](#)
4. Seignour M, Coudry V, Norris R, Denoix JM. Ultrasonographic examination of the palmar/plantar aspect of the fetlock in the horse: technique and normal images. *Equine Vet Educ* 2012;24:19-29.
[CROSSREF](#)
5. Davidson EJ. Lameness evaluation of the athletic horse. *Vet Clin North Am Equine Pract* 2018;34:181-191.
[PUBMED](#) | [CROSSREF](#)
6. Ley CJ, Björnsdóttir S, Ekman S, Boyde A, Hansson K. Detection of early osteoarthritis in the centrodistal joints of Icelandic horses: evaluation of radiography and low-field magnetic resonance imaging. *Equine Vet J* 2016;48:57-64.
[PUBMED](#) | [CROSSREF](#)
7. Moshtagh PR, Korthagen NM, Plomp SG, Pouran B, Zadpoor A, Weinans H. Bone remodeling is an early sign of biomechanically induced pre-osteoarthritis. *Osteoarthritis Cartilage* 2017;25:S295-S296.
[CROSSREF](#)
8. Severino RM, Jorge PB, Martinelli MO, de Lima MV, Severino NR, Duarte Junior A. Analysis on the serum levels of the biomarker CTX-II in professional indoor soccer players over the course of one season. *Rev Bras Ortop* 2015;50:331-335.
[PUBMED](#) | [CROSSREF](#)
9. Ryd L, Brittberg M, Eriksson K, Jurvelin JS, Lindahl A, Marlovits S, Möller P, Richardson JB, Steinwachs M, Zenobi-Wong M. Pre-osteoarthritis: definition and diagnosis of an elusive clinical entity. *Cartilage* 2015;6:156-165.
[PUBMED](#) | [CROSSREF](#)
10. Chu CR, Williams AA, Coyle CH, Bowers ME. Early diagnosis to enable early treatment of pre-osteoarthritis. *Arthritis Res Ther* 2012;14:212.
[PUBMED](#) | [CROSSREF](#)
11. McIlwraith CW, Frisbie DD, Kawcak CE. The horse as a model of naturally occurring osteoarthritis. *Bone Joint Res* 2012;1:297-309.
[PUBMED](#) | [CROSSREF](#)
12. Moshtagh PR, Korthagen NM, Plomp SG, Pouran B, Castelein RM, Zadpoor AA, Weinans H. Early signs of bone and cartilage changes induced by treadmill exercise in rats. *JBMR Plus* 2018;2:134-142.
[PUBMED](#) | [CROSSREF](#)
13. Machado VM, Aguiar AC, Viana GF, Crosignani NO, Puoli Filho JN. Diagnostic value of computed tomography, radiography and ultrasonography in metacarpophalangeal joint disorders in horses. *Arq Bras Med Vet Zootec* 2016;68:66-72.
[CROSSREF](#)
14. De Lasalle J, Alexander K, Olive J, Laverty S. Comparisons among radiography, ultrasonography and computed tomography for ex vivo characterization of stifle osteoarthritis in the horse. *Vet Radiol Ultrasound* 2016;57:489-501.
[PUBMED](#) | [CROSSREF](#)
15. Silva MM. Development of a score protocol for articular diseases evaluation in horses and its correlation with post therapy results [doctoral thesis]. 94 p. School of Veterinary Medicine and Animal Science, University of São Paulo, São Paulo, 2014.

16. Madry H, Kon E, Condello V, Peretti GM, Steinwachs M, Seil R, Berruto M, Engebretsen L, Filardo G, Angele P. Early osteoarthritis of the knee. *Knee Surg Sports Traumatol Arthrosc* 2016;24:1753-1762.
[PUBMED](#) | [CROSSREF](#)
17. Modransky PD, Rantanen NW, Hauser ML, Grant BD. Diagnostic ultrasound examination of the dorsal aspect of the equine metacarpophalangeal joint. *J Equine Vet Sci* 1983;3:56-58.
[CROSSREF](#)
18. Smith M, Smith R. Diagnostic ultrasound of the limb joints, muscle and bone in horses. *In Pract* 2008;30:152-159.
[CROSSREF](#)
19. Patterson-Kane JC, Firth EC. The pathobiology of exercise-induced superficial digital flexor tendon injury in Thoroughbred racehorses. *Vet J* 2009;181:79-89.
[PUBMED](#) | [CROSSREF](#)
20. Docking SI, Cook J. Pathological tendons maintain sufficient aligned fibrillar structure on ultrasound tissue characterization (UTC). *Scand J Med Sci Sports* 2016;26:675-683.
[PUBMED](#) | [CROSSREF](#)
21. Vanderperren K, Saunders JH. Diagnostic imaging of the equine fetlock region using radiography and ultrasonography. Part 1: Soft tissues. *Vet J* 2009;181:111-122.
[PUBMED](#) | [CROSSREF](#)
22. Keegan KG. Evidence-based lameness detection and quantification. *Vet Clin North Am Equine Pract* 2007;23:403-423.
[PUBMED](#) | [CROSSREF](#)
23. Wyn-Jones G. *Equine lameness*. Blackwell Scientific Publications, Oxford, 1988.
24. IBM Corp. *IBM SPSS Statistics for Windows, Version 21.0 (Released 2012)*. IBM Corp., Armonk, 2012.
25. Souza MV. Osteoarthritis in horses-Part 1: Relationship between clinical and radiographic examination for the diagnosis. *Braz Arch Biol Technol* 2016;59:e16150024.
[CROSSREF](#)
26. Mora R, Binanti D, Mora N, Fantinato E, Ferrante V, Pedrotti L, Riccaboni P. Pathological findings and immunohistochemical evaluation of MMP-2 and TIMPs in equine fetlock affected by degenerative joint disease. *Am J Clin Exp Med* 2015;3:172-177.
[CROSSREF](#)
27. Pool RR, Meagher DM. Pathologic findings and pathogenesis of racetrack injuries. *Vet Clin North Am Equine Pract* 1990;6:1-30.
[PUBMED](#) | [CROSSREF](#)
28. Te Moller NC, van Weeren PR. How exercise influences equine joint homeostasis. *Vet J* 2017;222:60-67.
[PUBMED](#) | [CROSSREF](#)
29. Rasera L, Massoco CO, Landgraf RG, Baccarin RY. Exercise induced apoptosis and necrosis in the synovial fluid cells of athletic horses. *Pesqui Vet Bras* 2008;28:231-236.
[CROSSREF](#)
30. Rickey EJ, Cruz AM, Trout DR, McEwen BJ, Hurtig MB. Evaluation of experimental impact injury for inducing post-traumatic osteoarthritis in the metacarpophalangeal joints of horses. *Am J Vet Res* 2012;73:1540-1552.
[PUBMED](#) | [CROSSREF](#)
31. Firth EC. The response of bone, articular cartilage and tendon to exercise in the horse. *J Anat* 2006;208:513-526.
[PUBMED](#) | [CROSSREF](#)
32. Kawcak CE, McIlwraith CW, Firth EC. Effects of early exercise on metacarpophalangeal joints in horses. *Am J Vet Res* 2010;71:405-411.
[PUBMED](#) | [CROSSREF](#)
33. Brama PA, Holopainen J, van Weeren PR, Firth EC, Helminen HJ, Hyttinen MM. Influence of exercise and joint topography on depth-related spatial distribution of proteoglycan and collagen content in immature equine articular cartilage. *Equine Vet J* 2009;41:557-563.
[PUBMED](#) | [CROSSREF](#)
34. Denoix JM, Jacot S, Bousseau B, Perrot P. Ultrasonographic anatomy of the dorsal and abaxial aspects of the equine fetlock. *Equine Vet J* 1996;28:54-62.
[PUBMED](#) | [CROSSREF](#)
35. Kawcak CE, McIlwraith CW, Norrdin RW, Park RD, Steyn PS. Clinical effects of exercise on subchondral bone of carpal and metacarpophalangeal joints in horses. *Am J Vet Res* 2000;61:1252-1258.
[PUBMED](#) | [CROSSREF](#)