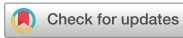

Original Article
Medical Imaging



Comparison of dental radiography and computed tomography: measurement of dentoalveolar structures in healthy, small-sized dogs and cats

Seunghye Lee ¹, Kichang Lee ^{1*}, Hyeona Kim ¹, Jeongsu An ¹, Junho Han ¹, Taekwon Lee ¹, Hogyun Jeong ¹, Youngkwon Cho ²

¹College of Veterinary Medicine, Jeonbuk National University, Iksan 54596, Korea
²College of Health Sciences, Cheongju University, Cheongju 28503, Korea



Received: May 17, 2020
Revised: Aug 13, 2020
Accepted: Aug 14, 2020

*Corresponding author:

Kichang Lee

College of Veterinary Medicine, Jeonbuk National University, 79 Gobong-ro, Iksan 54596, Korea.
E-mail: kcleee@jbnu.ac.kr

© 2020 The Korean Society of Veterinary Science

This is an Open Access article distributed under the terms of the Creative Commons Attribution Non-Commercial License (<https://creativecommons.org/licenses/by-nc/4.0>) which permits unrestricted non-commercial use, distribution, and reproduction in any medium, provided the original work is properly cited.

ORCID iDs

Seunghye Lee 
<https://orcid.org/0000-0002-8475-2829>
Kichang Lee 
<https://orcid.org/0000-0002-6961-0849>
Hyeona Kim 
<https://orcid.org/0000-0002-1984-708X>
Jeongsu An 
<https://orcid.org/0000-0001-8546-4610>
Junho Han 
<https://orcid.org/0000-0001-8482-3351>
Taekwon Lee 
<https://orcid.org/0000-0002-6232-9974>
Hogyun Jeong 
<https://orcid.org/0000-0001-6101-0235>
Youngkwon Cho 
<https://orcid.org/0000-0003-2293-5141>

ABSTRACT

Background: Dental diseases are common in dogs and cats, and accurate measurements of dentoalveolar structure are important for planning of treatment. The information that the comparison computed tomography (CT) with dental radiography (DTR) is not yet reported in veterinary medicine.

Objectives: The purpose of this study was to compare the DTR with CT of dentoalveolar structures in healthy dogs and cats, and to evaluate the CT images of 2 different slice thicknesses (0.5 and 1.0 mm).

Methods: We included 6 dogs (2 Maltese and 1 Spitz, Beagle, Pomeranian, mixed, 1 to 8 years, 4 castrated males, and 2 spayed female) and 6 cats (6 domestic short hair, 8 months to 3 years, 4 castrated male, and 2 spayed female) in this study. We measured the pulp cavity to tooth width ratio (P/T ratio) and periodontal space of maxillary and mandibular canine teeth, maxillary fourth premolar, mandibular first molar, maxillary third premolar and mandibular fourth premolar.

Results: P/T ratio and periodontal space in the overall dentition of both dogs and cats were smaller in DTR compared to CT. In addition, CT images at 1.0 mm slice thickness was generally measured to be greater than the images at 0.5 mm slice thickness.

Conclusions: The results indicate that CT with thin slice thickness provides more accurate information on the dentoalveolar structures. Additional DTR, therefore, may not be required for evaluating dental structure in small-sized dogs and cats.

Keywords: Dental radiography; multi-detector computed tomography; pulp cavity; periodontal space

INTRODUCTION

Dental diseases such as periodontitis and endodontic disease are common in dogs and cats, and often progress to a severe state. Periodontitis is associated with widening of the periodontal ligament space, secondary vertical and horizontal bone loss, and can be characteristically visible on radiographs. Endodontic disease affects the vital structures of teeth such as the pulp cavity and leads to discomfort, pain and destruction of the periodontal structure [1]. Periodontal disease is associated with systemic diseases such as renal, hepatic, and cardiac disorders, which highlights the importance of a proper diagnosis and adequate treatment [2,3].

Funding

This research was supported by Basic Science Research Program through the National Research Foundation of Korea (NRF), funded by the Ministry of Education (2018R1D1A1B07050529).

Conflict of Interest

The authors declare no conflicts of interest.

Author Contribution

Conceptualization: Lee S, Lee K, Cho Y; Data curation: Lee S, Kim H, An J, Han J, Lee T, Jeong H; Formal analysis: Lee S, Kim H, An J; Funding acquisition: Lee K; Investigation: Lee S, Kim H, An J; Methodology: Lee S, Lee K, Kim H, An J; Software: Lee S, Kim H, An J, Han J, Lee T, Jeong H; Writing - original draft: Lee S; Writing - review & editing: Lee S, Lee K, Cho Y.

Dental radiography (DTR) is the most widely used diagnostic modality in veterinary dentistry [4]. DTR has limits, consequent distortion and overlay of anatomic structures as a result of an inconsistent X-ray beam [5,6]. Furthermore, a previous study comparing DTR and surgical measurements showed that radiographic assessments underestimated bone loss up to 1.5 mm in humans [7].

Computed tomography (CT) provides cross-sectional images without distortion and can detect lesions at all locations including the buccal and lingual aspects [8,9]. Structures that are challenging to image in radiography such as temporomandibular joints and nasal cavity can be easily visualized in CT, so that CT can overcome the limitations of DTR and provide more information.

For the diagnosis of tooth lesions, it is very important to detect the lesion accurately and sensitively. For examples, in apical abscess at mandibular tooth, assessing width of lysis and degree of remained mandibular bone make it possible to estimate the prognosis of the mandibular bone such as pathologic fracture. Also, it is essential to identify of morphologic anatomy of pulp cavity for endodontic treatment such as size of gutta percha and other filling materials. And there have been studies comparing CT with DTR for detecting and evaluating dental disease, and CT provides more sufficient and accurate information in human [10,11].

To the author's knowledge, no studies have been performed to compare measurements of teeth structure or lesion, despite it is important to determine the exact extent or length of the lesion or tooth structure to assess the possibility of pathologic fractures in severe periodontitis of a mandibular tooth or to measure the length of the root canal in pre-procedural radiographs for endodontic treatment. The aim of this study is to measure and compare dentoalveolar structures in DTR and CT. We hypothesized that measurements in DTR would be different from that on CT due to distortion and overlap. Also, it was expected that CT would be sufficient to replace DTR for dental diagnoses.

MATERIALS AND METHODS

This study was a retrospective design and approved by Animal Care and Use Committee of the Jeonbuk National University (CBNU 2019-053).

We included 6 dogs and 6 cats in the study. They were all client-owned, volunteered for this study although there is no specific consent form. The animals were considered clinically healthy if they had not exhibited any specific findings in the following examinations: clinical signs, physical examinations, blood testing, and four views of skull radiographs (lateral, dorsoventral, two oblique views with an open mouth). Animals with abnormal findings in the above tests who had received dental treatment in the past were excluded from the study.

The breeds of the dogs were Maltese (n = 2), Spitz (n = 1), Beagle (n = 1), Pomeranian (n = 1), and mixed (n = 1), and the cats were all domestic short hairs. The mean age of the dogs was 4.6 years (range, 1 to 8 years), and the cats was 1.8 years (range, 8 months to 3 years).

All animals were sedated with medetomidine hydrochloride (40 µg/kg, IV, Domitor; Orion Pharma, Finland) and tiletamine-zolazepam (5 mg/kg, IV, Zoletile; Virbac, France). DTR and CT were performed under the same sedation event.

DTR images were obtained using dental X-rays (AnyRayII, Vatech Korea, Korea). The exposure setting was 2 mA at 60 kVp for 0.03 sec to 0.08 sec according to size of teeth.

CT images were obtained using a 16-row multidetector CT scanner (Alexion, TSX-034A, Toshiba Medical System, Japan) with the following parameters: 120 kVp, 150 mAs, 0.688 pitch, and 0.75 rotation time. CT was each performed twice 0.5 mm and 1.0 mm slice thicknesses (CT 0.5, CT 1.0) at the same posture and scan condition. All images were multiplanar reconstructed (MPR) with using a bone algorithm.

All images were transferred to a picture-archiving and communication system (PACS), and the measurements were conducted using a PACS viewer (INFINIT; Infinit Healthcare, Korea). Measurements were performed blindly by one observer and repeated twice for the same image, site, and window setting. The measurements of the CT images were performed at the bone window (window level: 500, window width: 4,000), and bone density of the images was adjusted to optimize assessment.

Dentoalveolar structures of the maxillary and mandibular maxillary and mandibular canine teeth (UC, LC), the maxillary fourth premolar (UPM4), the mandibular first molar (LM1), the maxillary third premolar (UPM3), and the mandibular fourth premolar (LPM4) were measured. These teeth were chosen because of their accessibility, deep roots, and positioning in reference to each other. In measuring the periodontal space, UPM3 and LPM4 were excluded because they were very small in some animals, leading to difficulty in evaluation with both modalities.

Two measurements were performed for each tooth: 1) pulp-cavity to tooth width ratio (P/T ratio), (A/B), and 2) width of the periodontal space (POS), (C). Standardized measurements of P/T ratio were performed at the level of the cemento-enamel junction (CEJ) of the tooth, and the POS was measured in periapical created by drawing a line from axis of the pulp cavity perpendicular to this axis (Fig. 1) [12]. In multi-rooted teeth, measurement is performed consistently in the cranial root.

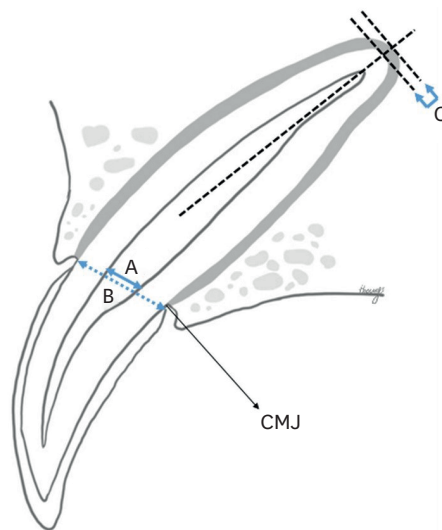


Fig. 1. Pulp cavity (A), to tooth wide (B) and POS (C). Measurements of P/T ratio were performed at the level of cemento-enamel junction of tooth. POS were measured by drawing line that axis of pulp cavity and perpendicular to axis line. P/T ratio, pulp cavity to tooth width ratio; POS, periodontal space; CMJ, cemento enamel junction.

For statistical analysis, SPSS software (IBM SPSS Statistics for Window, Version 25.0; IBM Corp., USA) was used. Repeated measured analysis of variance was performed to compare to P/T ratio and width of the POS according to measurement method for evaluating the teeth of dogs and cats.

RESULTS

Intraclass correlation coefficients (ICC) were used to verify the reliability of measurements, and very high ICC was obtained for the P/T ratio at 0.991 and for the POS at 0.978 with excellent agreement.

On multiple comparisons, mean value of measurements in P/T ratio was largest when measured with CT 1.0, followed by CT 0.5 and DTR (**Fig. 2**). The overall mean value and SD of P/T ratio was 0.17 ± 0.08 for DTR, 0.20 ± 0.08 for CT 0.5, and 0.22 ± 0.08 for CT 1.0, and there was a statistically significant difference ($p < 0.001$).

The results for each tooth and the P/T ratio of UC and UPM4 were higher in CT 0.5 and CT 1.0 compared to DTR. The P/T ratio of LC, UPM3, LPM4, and LM1 was highest in CT 1.0, followed by CT 0.5 and DTR (**Table 1**). There was a statistically significant difference between all teeth ($p < 0.01$). The tooth with the smallest difference among the modalities was UC, and the differences of LC and LM1 were smaller than those of the other teeth. However, the ratio

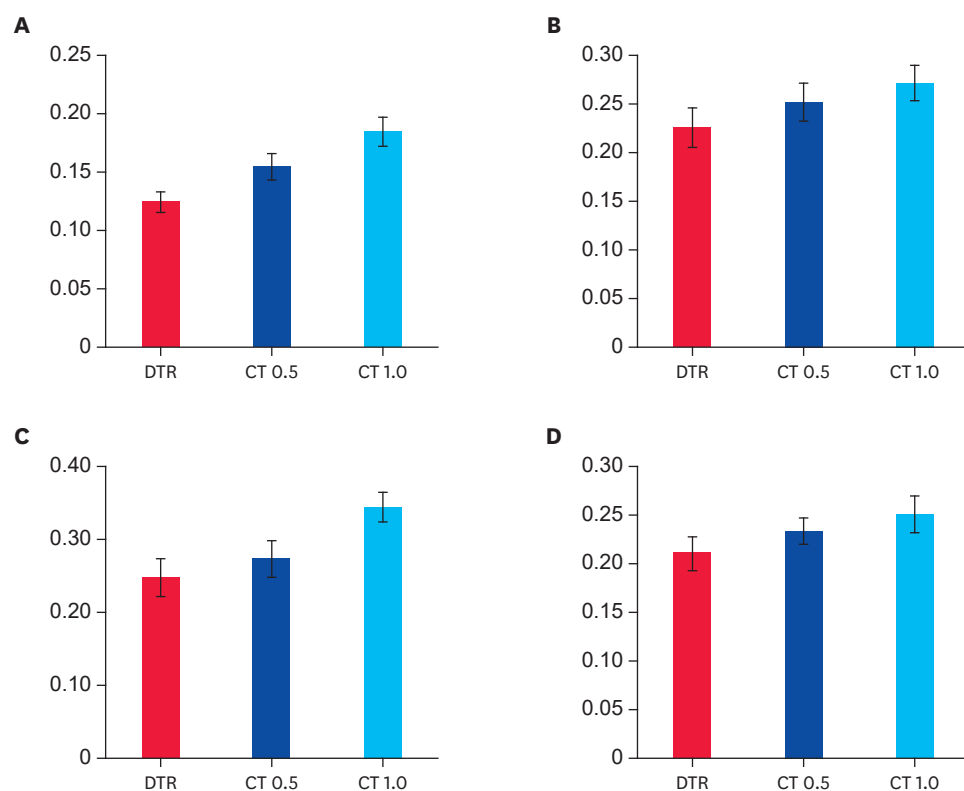


Fig. 2. Difference of P/T ratio according to measurement method of dogs (A) and cats (B) and difference of POS of dogs (C) and cats (D). In both dogs and cats, P/T ratio and POS were measured significantly larger ($p < 0.001$) in CT 0.5 than DTR, and larger in CT 1.0 than CT 0.5.

P/T ratio, pulp-cavity to tooth width ratio; POS, periodontal space; DTR, dental radiography; CT 0.5, 0.5 mm slice thickness computed tomography; CT 1.0, 1.0 mm slice thickness computed tomography.

Table 1. Difference P/T ratio according to tooth measurement methods in dogs and cats

Variable	Teeth	DTR	CT 0.5	CT 1.0	<i>p</i>
P/T ratio	Total	0.17 ± 0.08	0.20 ± 0.08	0.22 ± 0.08	< 0.001
	UC	0.17 ± 0.11	0.18 ± 0.11	0.19 ± 0.10	< 0.001
	LC	0.15 ± 0.07	0.16 ± 0.07	0.18 ± 0.06	< 0.001
	UPM3	0.17 ± 0.07	0.23 ± 0.05	0.26 ± 0.05	< 0.001
	UPM4	0.15 ± 0.05	0.19 ± 0.05	0.21 ± 0.05	< 0.001
	LPM4	0.18 ± 0.07	0.22 ± 0.06	0.27 ± 0.05	< 0.001
	LM1	0.21 ± 0.12	0.22 ± 0.12	0.24 ± 0.11	< 0.001

Values are expressed as mean ± SD. All measurements are statistically significant with $p < 0.001$.

P/T ratio, pulp-cavity to tooth width ratio; DTR, dental radiography; CT 0.5, 0.5 mm slice thickness computed tomography; CT 1.0, 1.0 mm slice thickness computed tomography; UC, maxillary canine teeth; LC, mandibular canine teeth; UPM3, maxillary third premolar; UPM4, maxillary fourth premolar; LPM4, mandibular fourth premolar; LM1, mandibular first molar.

Table 2. Difference width of POS according to tooth measurement methods in dogs and cats

Variable	Teeth	DTR	CT 0.5	CT 1.0	<i>p</i>
Periodontal space	Total	0.23 ± 0.09	0.25 ± 0.08	0.30 ± 0.09	< 0.001
	UC	0.27 ± 0.08	0.29 ± 0.07	0.33 ± 0.08	< 0.001
	LC	0.25 ± 0.12	0.26 ± 0.13	0.30 ± 0.10	< 0.001
	UPM4	0.20 ± 0.05	0.24 ± 0.03	0.28 ± 0.06	< 0.001
	LM1	0.21 ± 0.06	0.23 ± 0.05	0.29 ± 0.09	< 0.001

Values are expressed as mean ± SD (mm). All measurements are statistically significant with $p < 0.001$.

POS, periodontal space; DTR, dental radiography; CT 0.5, 0.5 mm slice thickness computed tomography; CT 1.0, 1.0 mm slice thickness computed tomography; UC, maxillary canine teeth; LC, mandibular canine teeth; UPM4, maxillary fourth premolar; LM1, mandibular first molar.

of UPM4 was moderately different from those of DTR, CT 0.5, and CT 1.0, and the difference of UPM3 and LPM4 was larger than those of the other teeth.

The mean value and SD of measurements in POS width of the total teeth was 0.23 ± 0.09 for DTR, 0.25 ± 0.08 for CT 0.5, and 0.30 ± 0.09 for CT 1.0, and there was a statistically significant difference ($p < 0.001$). Similar to P/T ratio, the POS was the largest in CT 1.0, followed by CT 0.5 and DTR (**Fig. 2**). For the results for each tooth and in all teeth, the POS was the largest in CT 1.0, followed by CT 0.5 and DTR (**Table 2**). The differences in measurements in each modality were slightly greater in UPM4 and LM1 compared to UC and LC.

The results after separating dogs and cats exhibited the same tendency as the results for all teeth (**Fig. 2**). First, the mean of P/T ratio of dogs was 0.12 ± 0.04 for DTR, 0.15 ± 0.05 for CT 0.5, and 0.18 ± 0.06 for CT 1.0. In cats, the mean of ratio was 0.23 ± 0.09 for DTR, 0.25 ± 0.08 for CT 0.5, and 0.27 ± 0.08 in CT 1.0. The mean of POS of dogs was 0.25 ± 0.10 for DTR, 0.27 ± 0.10 for CT 0.5, and 0.34 ± 0.08 in CT 1.0. In cats, the mean of width of this space was 0.25 ± 0.10 , 0.27 ± 0.10 , and 0.34 ± 0.08 for DTR, CT 0.5, and CT 1.0, respectively. All analyses exhibited statically significant differences at a level of 5% ($p < 0.001$).

DISCUSSION

The P/T ratio and POS in the dentition of both dogs and cats were smaller in DTR compared to CT. This was consistent with our hypothesis that measurement in DTR would be different from that on CT. In DTR image, distortion of structures is inevitable due to characteristics of the filming CT provides cross-sectional images and MPR images, allowing selection of images that best represent a specific structure. This supports a previous study showing that measurements in DTR can be underestimated [8].

The images obtained at CT 1.0 was generally measured to be greater than those at CT 0.5. CT 1.0 images have high quality and can provide sufficient information to evaluate tooth structure in medium-sized dogs [13]. However, animals included in this study were small-sized dogs and cats with small teeth. As a result, even CT 1.0 images were insufficient. In poor-resolution images, demarcation of the structures is blurred, resulting in possible overestimation.

The teeth with small differences in P/T ratio among modalities were UC, LC, and LM1. These teeth were represented as actual structures because of easy access with an intraoral sensor and visibility due to deep and large roots compared to other teeth. In UPM4 and UPM3, the difference in measured values of DTR and CT was greater than in other teeth. This is because maxillary teeth are more likely to be misread due to overlap among anatomical structures of the skull such as the zygomatic arch.

UPM4 is a multi-rooted tooth, and superimposition was unavoidable. Therefore, the width of the POS differed less among the modalities at UC and LC and was greater than at UPM4.

One interesting point is that the P/T ratio in cats was greater in dogs. The P/T ratio is closely correlated with age in dogs and cats, especially at 1 year of age [11,14]. The mean age of cats included in the experiment was 1.8 years, which was significantly younger than the mean age of 4.6 years in dogs, consistent with previous studies concluded that P/T ratio is greater in younger animals than older animals.

The repeated emphasis in this study is that the main advantage of CT is providing cross section images with no distortion or overlap. Assessment of oral disease using CT is useful not only for interproximal lesions, but also for evaluating lesions in all directions, including lingual and buccal aspects, which are difficult to detect with DTR. Thus, CT negates the need for separate oral inspection with the periodontal probe, as required with DTR.

In the early stage of tooth disease may not be detected in DTR due to normal surrounding teeth and skull structures, however, CT images can overcome this disadvantage. Also, changes of the skull such as oronasal fistulas that occur as the disease progresses can be evaluated as a whole, so that more information can be provided in planning treatment and evaluating the prognosis of the patient. Despite of the cost of CT, CT allows an overall evaluation of the skull structure including teeth and surrounding structure, and CT imaging may be more cost-effective. Therefore, CT is sufficient to replace DTR for detailed evaluations.

Because this study was performed on clinically normal teeth of small-sized dogs and cats, further studies of patients with oral disease will be useful to confirm the clinical application feasibility of CT.

The limitation of this study is that there was no gold-standard reference, which yielded difficulty in assessment of the method representing the measured value compared to the actual value. It was difficult to perform surgical measurements because all animals included in this study were clinically healthy and client-owned. However, CT provides an image that was closer to the actual structure than that of DTR. In addition, image of CT 0.5 exhibited better resolution and higher quality than image of CT 1.0. Therefore, images of CT 0.5 can be considered the most similar to actual teeth.

In conclusion, CT can provide more accurate evaluation by obtaining images without distortion and overlap and is sufficient for replacing DTR. The teeth and surrounding structures of small-sized dogs and cats were so small that 0.5 mm slice thickness images were recommended. In DTR, measurements of dentoalveolar structures such as P/T ratio and POS were smaller than CT measurements. Therefore, CT with thin slice thickness is feasible, and additional DTR is not required for evaluating dentoalveolar structures in small-sized dogs and cats.

ACKNOWLEDGEMENTS

Special thanks to Se-jin Park for helping us with the statistical analysis of this study. Also, we would like to express my special gratitude to Nam-Su Kim and Won-il Kim for methodological advice.

REFERENCES

1. Logan EI, Finney O, Hefferren JJ. Effects of a dental food on plaque accumulation and gingival health in dogs. *J Vet Dent*. 2002;19(1):15-18.
[PUBMED](#) | [CROSSREF](#)
2. Pavlica Z, Petelin M, Juntos P, Erzen D, Crossley DA, Skaleric U. Periodontal disease burden and pathological changes in organs of dogs. *J Vet Dent*. 2008;25(2):97-105.
[PUBMED](#) | [CROSSREF](#)
3. Glickman LT, Glickman NW, Moore GE, Goldstein GS, Lewis HB. Evaluation of the risk of endocarditis and other cardiovascular events on the basis of the severity of periodontal disease in dogs. *J Am Vet Med Assoc*. 2009;234(4):486-494.
[PUBMED](#) | [CROSSREF](#)
4. Tsugawa AJ, Verstraete FJ. How to obtain and interpret periodontal radiographs in dogs. *Clin Tech Small Anim Pract*. 2000;15(4):204-210.
[PUBMED](#) | [CROSSREF](#)
5. Hirschmann PN. Radiographic interpretation of chronic periodontitis. *Int Dent J*. 1987;37(1):3-9.
[PUBMED](#)
6. Korostoff J, Aratsu A, Kasten B, Mupparapu M. Radiologic assessment of the periodontal patient. *Dent Clin North Am*. 2016;60(1):91-104.
[PUBMED](#) | [CROSSREF](#)
7. Eickholz P, Hausmann E. Accuracy of radiographic assessment of interproximal bone loss in intrabony defects using linear measurements. *Eur J Oral Sci*. 2000;108(1):70-73.
[PUBMED](#) | [CROSSREF](#)
8. Misch KA, Yi ES, Sarment DP. Accuracy of cone beam computed tomography for periodontal defect measurements. *J Periodontol*. 2006;77(7):1261-1266.
[PUBMED](#) | [CROSSREF](#)
9. Fuhrmann RA, Buecker A, Diedrich PR. Assessment of alveolar bone loss with high resolution computed tomography. *J Periodontal Res*. 1995;30(4):258-263.
[PUBMED](#) | [CROSSREF](#)
10. Iikubo M, Kobayashi K, Mishima A, Shimoda S, Daimaruya T, Igarashi C, et al. Accuracy of intraoral radiography, multidetector helical CT, and limited cone-beam CT for the detection of horizontal tooth root fracture. *Oral Surg Oral Med Oral Pathol Oral Radiol Endod*. 2009;108(5):e70-e74.
[PUBMED](#) | [CROSSREF](#)
11. Campbell RD, Peralta S, Fiani N, Scrivani PV. Comparing intraoral radiography and computed tomography for detecting radiographic signs of periodontitis and endodontic disease in dogs: an agreement study. *Front Vet Sci*. 2016;3:68.
[PUBMED](#) | [CROSSREF](#)
12. Park K, Ahn J, Kang S, Lee E, Kim S, Park S, et al. Determining the age of cats by pulp cavity/tooth width ratio using dental radiography. *J Vet Sci*. 2014;15(4):557-561.
[PUBMED](#) | [CROSSREF](#)

13. Soukup JW, Drees R, Koenig LJ, Snyder CJ, Hetzel S, Miles CR, et al. Comparison of the diagnostic image quality of the canine maxillary dentoalveolar structures obtained by cone beam computed tomography and 64-multidetector row computed tomography. *J Vet Dent*. 2015;32(2):80-86.
[PUBMED](#) | [CROSSREF](#)
14. Knowlton FF, Whittemore SL. Pulp cavity-tooth width ratios from known-age and wild-caught coyotes determined by radiography. *Wildl Soc Bull*. 2001;29:236-244.