

다형샘종 제거 후 발생한 연구개 점막 결손의 무세포 동종 진피기질을 이용한 재건 1례

이재성¹ · 임길채² · 김정홍² · 강제경¹ · 신명수¹ · 윤병민^{1*}

제주대학교 의과대학 성형외과학교실¹, 제주대학교 의과대학 이비인후과학교실²

Use of Acellular Allogenic Dermal Matrix in Soft Palate Reconstruction after Excision the Pleomorphic Adenoma

Jae Seong Lee, MD¹, Gil Chae Lim, MD², Jeong Hong Kim, MD², Jae Kyoung Kang, MD¹,
Myoung Soo Shin, MD¹, Yun Byung-Min, MD^{1*}

Department of Plastic and Reconstructive Surgery College of Medicine Jeju National University, Jeju, Korea¹,

Department of Otorhinolaryngology, College of Medicine Jeju National University, Jeju, Korea²

= Abstract =

Recent studies have reported on the reconstruction of oral mucosal defects using acellular dermal matrix (ADM). This case report describes the reconstruction of a soft-palate mucosal defect using ADM. A 43-year-old man developed a 2.5 cm × 3 cm soft-palate mucosal defect after the removal of a lump on the soft palate and reconstructed the defect using ADM without further complications. Reconstruction of the soft palate with ADM could be more convenient than traditional methods including primary closure, skin graft, and local or free flap without complications.

Key Words : Acellular allogenic dermal matrix, Soft palate reconstruction

Introduction

Soft-palate reconstruction can be performed using various methods, including primary closure, skin grafting, local flap, and free flap.¹⁾ However, recent studies have used acellular dermal matrix (ADM) for reconstructing skin defects in various areas. ADM has been used for the reconstruction of cleft palate or cleft palate fissures²⁾ as well as defects that form after lump removal. Previous studies showed that us-

ing ADM for the reconstruction of intra-oral defects has some benefits compare to traditional methods without further complications.^{3,4)}

This case report demonstrates the use of ADM for treating a defective region that is relatively larger than those described in previous studies.

Case report

The patient was a 43-year-old man who underwent fine needle aspiration for a mass observed on the right side of the soft palate that was diagnosed as a pleomorphic adenoma at the otorhinolaryngology outpatient clinic. A lumpectomy was performed in the otorhinolaryngology department and the patient was referred to our department for reconstruction of the expected soft-palate defect after the

Received : October 18, 2018

Revised : November 8, 2018(1차) / April 17, 2019(2차)

Accepted : April 21, 2019

+Corresponding author: Yun Byung-Min, MD

Department of Plastic & Reconstructive Surgery, College of Medicine, Jeju National University, 66 Jejudaehak-ro, Jeju 63243, Korea

Tel: +82-64-717-1742, Fax: +82-64-755-6130

E-mail: almostfree@hanmail.net

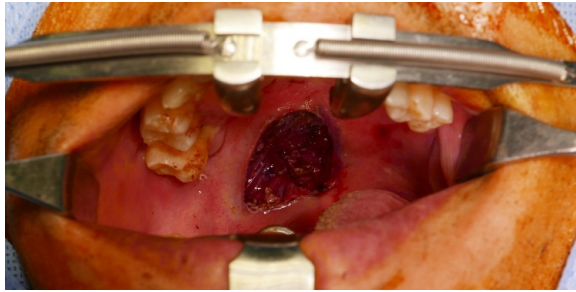


Fig. 1. A mucosa defect with an ovoid shape measuring 2.5 cm x 3 cm in size occurred following mass removal at an otolaryngology clinic

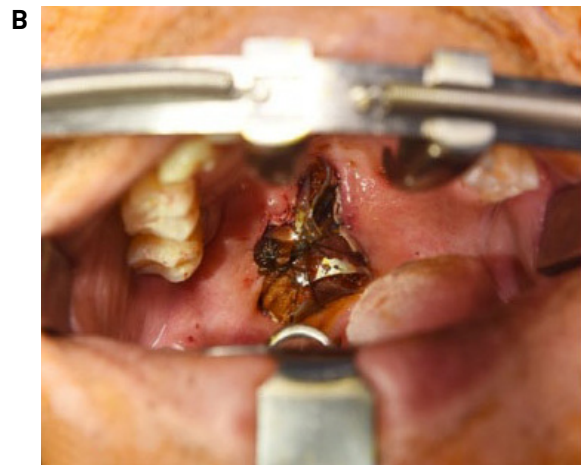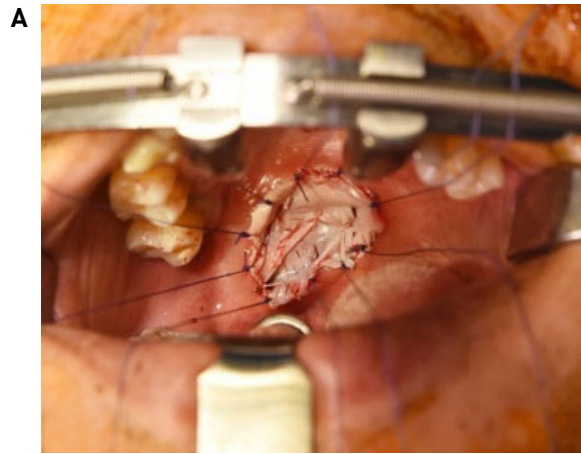


Fig. 2. An ADM was trimmed and applied according to the defect size and (A) tie over dressing was applied. (B)

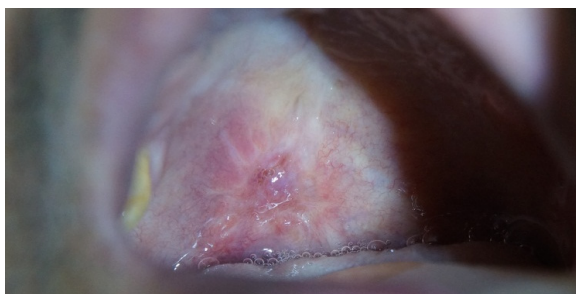

Fig. 3. One month after surgery.

surgery. The initial soft-tissue incision (2 cm in diameter) resulted in a defect on the soft palate (2.5 cm × 3 cm). At this point, the nasal palate mucous membrane was preserved (Fig. 1). Thereafter, MegaDerm ADM (L&C Bio, Seoul, Korea) was designed and cut to match the defect. After the defect was covered, a tie-over dressing was placed using 4-0 Vicryl sutures (Ethicon; Johnson and Johnson, Livingston, UK) (Fig. 2). The patient stopped oral diet temporarily until postoperative day(POD4) and received total parenteral nutrition(TPN) to provide adequate nutrition. In addition, the patient underwent a betadine gargle every 2 hours to maintain his intra-oral hygiene. On POD 7, the stitches from the tie-over dressing were removed. Successful graftuptake without loss was observed and the patient was followed up after discharge. The patient has recovered fully without extrusion of the reconstructed area or complications (i.e. infection, dysphagia, dysarthria, fistula) (Fig. 3). Furthermore, functional aspects including articulation and deglutition were also preserved.

Discussion

Defects of the soft palate can arise due to various causes, including congenital deformities as well as traumatic injuries or surgical procedures. Since a soft-tissue defect can induce functional disabilities such as dysphagia, dyslalia, or nasal cavity reflux, it is crucial to provide appropriate site reconstruction to improve patient quality of life.⁵⁾ Multiple methods (i.e. primary closure, skin graf, local flap, myocutaneous flap, and free flap) are being used to reconstruct the soft palate, and complex factors such as lesion size and area, pre-surgical treatment, and underlying diseases affect the clinician or surgeon's decision-making process.¹⁾

Smaller soft-palate defects can be reconstructed via primary closure, a local flap, and a skin graft, with a pharyngeal flap and palatal island flap being frequently used as local flaps. However, larger defects that exceed the midline of the soft palate can induce velopharyngeal insufficiency.⁶⁾ On the other hand, split thickness skin grafts (STSG) allow for the reconstruction of medium-sized defects as well as relatively more convenient acquisition of donor skin, easier successfuluptake, and preservation of the functional aspects of the soft palate.⁷⁾ Nonetheless, STSG also has its drawbacks, including **extrusion** of the recipient site, pain in the donor

site, infection, and possible scarring.

Large soft-palate defects are often reconstructed using myocutaneous and free flaps. While myocutaneous flaps provide safety and abundant size, they can induce functional disabilities due to their thickness and reduced volume after muscle contraction.⁸⁾ Since the development of microsurgical techniques, free flap surgeries have become more popular. More specifically, the radial forearm flap – which is thin, flexible, and relatively hairless – is widely being used to reconstruct larger intra-oral defects. Defects that are extremely large ($\geq 3/4$ of the entire palate) can be treated simultaneously with a radial forearm flap and superiorly based pharyngeal flap, which allows for the reconstruction of larger defects and the preservation of function (i.e. vocalization and deglutition).⁹⁾

In contrast to these traditional reconstruction methods, recent studies have introduced the use of ADM for the reconstruction of skin defects in different regions. ADM is a material with a maintained human dermal structure but from which the immunogenic cellular components have been selectively removed. This provides a stable frame for the movement of epithelial cells and fibroblasts as well as angiogenesis.¹⁰⁾ ADM has recently been used in various fields, including breast reconstruction, anorectal fistula repair, hernia repair, and skin donor site repair. ADM has also been used for intra-oral mucosal defect reconstruction, mostly for cleft palates and oronasal fistulae in pediatric patients in earlier studies.²⁾ Clark et al.¹¹⁾ demonstrated that utilizing ADM for two-flap primary palatoplasty allows for the reconstruction of clefts ≥ 15 mm wide without fistula. Further, applications of ADM in the reconstruction of the buccal mucosa, gums, and lower lip have provided good outcomes.³⁾ Although contractions were more evident in lip and buccal defect reconstructions – which have relatively looser textures than other regions of the oral mucosa – no obvious graft contractions were observed during compact oral mucosa reconstruction.

A previous study demonstrated that ADM can sufficiently replace the traditional standard treatment method of STSG for the reconstruction of small intra-oral mucosal defects.⁴⁾ comparatively assessed the utility of the two methods. Reconstruction using ADM has demonstrated benefits compared to STSG, including lower donor-site morbidity, lower

cost, surgical procedure time, and functional status. Moreover, histopathological examinations confirmed that the use of ADM for reconstruction reduced the frequency of inflammation, fibrosis, and keratinization compared with STSG.

This case report demonstrated that we could successfully restore a relatively larger (2.5 cm \times 3 cm) sized soft-palate defect using ADM. Traditional methods for surgical resection of benign tumors place a considerable burden on patients in terms of potential scarring, infection, and donor-site pain. We demonstrated that the use of ADM can successfully reconstruct defects that form after the surgical removal of benign tumors, with considerable benefits including shorter surgical time, lower medical costs, and the absence of complications or functional disabilities.

References

- 1) Tsue TT, Kriet DJ, Wallace DI, Girod DA. *Planning and diagnostic evaluation in oral cavity reconstruction*. In: Day TA, Girod DA, editors. *Oral Cavity Reconstruction*. New York, NY: Taylor and Francis; 2006. p.79-94.
- 2) Helling ER, Dev VR, Garza J, Barone C, Nelluri P, Wang PT. *Low fistula rate in palatal clefts closed with the Furlow technique using decellularized dermis*. *Plast Reconstr Surg*. 2006;117:2361-2365.
- 3) Shi LJ, Wang Y, Yang C, Jiang WW. *Application of acellular dermal matrix in reconstruction of oral mucosal defects in 36 cases*. *J Oral Maxillofac Surg*. 2012;70:e586-e591.
- 4) Girod DA, Sykes K, Jorgensen J, Tawfik O, Tsue T. *Acellular dermis compared to skin grafts in oral cavity reconstruction*. *The Laryngoscope*, 2009, 119.11: 2141-2149.
- 5) Kavanagh KT, Hinkle WG. *Reconstruction of the soft palate after jaw, tongue, neck dissection with subtotal palatotomy*. *Laryngoscope*. 1987;97(12):1461-3.
- 6) Moore BA, Magdy E, Nettekville JL, Burkey BB. *Palatal reconstruction with the palatal island flap*. *Laryngoscope* 2003; 112(6):946-51.
- 7) Petruzzelli GJ, Johnson JT. *Skin grafts*. *Otolaryngol Clin North Am*. 1994;27:25-37.
- 8) Haughey BH. *Tongue reconstruction: Concepts and practice*. *Laryngoscope*. 1983;103(10):1132-41.
- 9) Brown JS, Zuydam AC, Jones DC, Rogers SN, Vaughan ED. *Functional outcome in soft palate reconstruction using a radial forearm free flap in conjunction with a superiorly based pharyngeal flap*. *Head Neck*. 1997;19(6):524-34.
- 10) Fosnot J, Kovach SJ III, Serletti JM. *Acellular dermal matrix: General principles for the plastic surgeon*. *Aesthet Surg J*. 2011; 31(Suppl):5S-12S.
- 11) Clark JM, Saffold SH, Israel JM. *Decellularized dermal grafting in cleft palate repair*. *Arch Facial Plast Surg*. 2003;5:40-44.