

Effects of Therapeutic Exercise on Pain, Physical Function, and Magnetic Resonance Imaging Findings in a Patient with Multilevel Lumbar Disc Herniation: A Case Report

Background: In some clinical guidelines followed in clinical practice, nonsurgical treatments are recommended as the primary intervention for patients with lumbar disc herniation (LDH). However, the effect of a therapeutic exercise program based on stabilization of the lumbar spine for treatment of multilevel LDH has not been evaluated thoroughly.

Objective: To investigate the effects of therapeutic exercise on pain, physical function, and magnetic resonance imaging (MRI) findings in a patient with multilevel LDH.

Design: Case Report

Methods: A 43-year-old female presented with low back pain, radicular pain and multilevel LDH (L3-L4, L4-L5, L5-S1). The therapeutic exercise program was conducted, in 40-min sessions, three times a week, for 12 weeks. Low back and radicular pain, lumbar disability, and physical function were measured before and after 6 and 12 weeks of the exercise program. MRI was performed before and after 12 weeks of the program.

Results: After 6 and 12 weeks of the therapeutic exercise, low back and radicular pain and lumbar disability had decreased, and lumbar range of motion (ROM) was improved bilaterally, compared with the initial values. Also improved at 6 and 12 weeks were isometric lumbar strength and endurance, and the functional movement screen score. The size of disc herniations was decreased on MRI obtained after 12 weeks of therapeutic exercise than on the pre-exercise images.

Conclusions: We observed that therapeutic exercise program improved spinal ROM, muscle strength, functional capacity, and size of disc herniation in LDH patient.

Key words: *Therapeutic exercise, Multilevel disc herniation, Magnetic resonance imaging*

Ahram Kim, Ph.D., Prof^{a,c}, Hoseong Lee, Ph.D., Prof^{b,c}

^aNamseoul University, Cheonan; ^bDankook University, Cheonan; ^cInstitute of MEDI-Sports, Cheonan, Republic of Korea

Received : 03 January 2019

Revised : 21 February 2019

Accepted : 27 February 2019

Address for correspondence

Ho-Seong Lee, Ph.D

Department of Kinesiologic Medical Science, Graduate, Dankook University, 119, Dandae-ro, Dongnam-gu, Cheonan-si, Chungcheongnam-do, Republic of Korea
TEL: +82 41-550-3838,
E-mail: hoseh28@dankook.ac.kr

INTRODUCTION

Lumbar disc herniation (LDH) is a common health problem that decreases quality of life ¹⁾ and leads to degenerative lumbar spinal disease in older adults ²⁾. LDH most typically presents as low back and radicular leg pain with muscle spasms and restricted trunk movement ³⁾ and causes both physical and social functional impairment ⁴⁾. Less than 5% of all cases of LDH occur in the upper lumbar area ⁵⁾, in which multilevel LDH is very uncommon ⁵⁾. In comparison with single-level LDH ⁶⁾, multilevel LDH causes significant

damage to the paraspinal muscles and the curvature of the back, prolonged recovery time, and may result in chronic low back pain (LBP).

In as many as 98% of cases, LDH occurs at the L4-5 and L5-S1 levels ⁷⁾. It develops most frequently at the posterolateral aspect of the disc, where the disc is the most weak ⁷⁾. Although LDH can occur at any age, it is most common in those aged 30-50 years. LDH is classified into three types according to location: median, lateral, and posterolateral ⁸⁾. Symptoms develop as a result of compression and irritation of the adjacent nerve roots ⁹⁾.

Although surgery for LDH is the most common spinal surgery performed¹⁰, nonsurgical treatments have favorable outcomes for the majority of these patients¹¹. Although current surgical techniques are less invasive than those in the past, they have significant limitations in terms of effectiveness, safety, and cost¹². Furthermore, a previous study has reported a 24% complication rate associated with these surgical interventions, with almost half of the complications being serious; 8% of patients who undergo surgery experience complications¹². These findings emphasize the importance of conservative care, which is beneficial to most patients and has a very low complication rate¹³. However, previous studies reported that pain and kinetic deficits remain in 30%–70% of patients after surgery. The persistence of these symptoms after surgery could be the result of paraspinal muscle weakness and musculoskeletal imbalance and highlights the importance of exercise training to relieve LBP^{14, 15, 16}.

In some clinical guidelines followed in clinical practice, nonsurgical treatments are recommended as the primary intervention for patients with LDH who do not have cauda equina syndrome^{17,18}. Among the numerous nonsurgical options, physical or exercise therapy has been shown to be beneficial for patients with LDH^{19,20}. Recent systematic reviews have reported that several nonsurgical therapies, such as ultrasound, low-power laser irradiation, stabilization exercises, and manipulation, are more effective in altering the prognosis of patients with LDH compared with no treatment or sham manipulation²¹. However, there is still no consensus regarding the most effective treatment.

The exercises for patients with LDH are designed to improve spinal stability and are among the most popular rehabilitation programs for increasing athletic performance and relieving pain. These exercises are also termed lumbar spine stabilization²², core stabilization²³, and motor control exercises²⁴. Their aim is to improve the musculature and activation of deep muscles such as the multifidus and transversus abdominis, diaphragm, and pelvic floor. These exercises also improve flexibility and strength deficits in the superficial muscles of the spine, and the ability to retain precise neural control of these muscles. Lumbar spine stabilization exercise, which has a strong theoretical foundation, is widely used in lumbar spine rehabilitation^{20, 21, 23}. However, the effect of a therapeutic exercise program based on stabilization of the lumbar spine for treatment of multilevel LDH has not been evaluated thoroughly. Therefore, further studies are required to investigate the safest and

most effective noninvasive treatment for patients with multilevel LDH.

The purpose of this study was to investigate the effects of therapeutic exercise on pain, physical function, and magnetic resonance imaging (MRI) findings in a patient with multilevel LDH. In deciding a management approach, selection of a patient-specific exercise and rehabilitation program that targets muscular stabilization and the precise manipulation of the spine is a cost-effective treatment that is ideal for patient recovery and an early return to work. This case report demonstrates the rehabilitation over a relatively short period of a patient with chronic LBP and an extruded lumbar disc.

METHODS

Subjects

A 43-year-old woman presented with severe LBP and radicular pain in the right leg below the knee that had persisted for more than 5 years. She had a history of multiple episodes of LBP that compromised her ability to perform general activities of daily living such as bending, lifting, and twisting. She described her LBP as an initial sharp pain accompanied by constant muscle spasms and muscle cramps in her right leg. An MRI revealed disc herniations in the right L3-4, L4-5, and L5-S1 regions. At her first visit to the MEDI-Sports Institute, Cheonan, Korea, her initial back pain and leg pain were each rated as 7.40/10.00. The pain was exacerbated by prolonged sitting and standing. She had no symptoms of cardiac, respiratory, or skin sensation dysfunction. This study was approved by the Ethics Committee of Namseoul University, Korea, in accordance with the ethical standards of the Declaration of Helsinki (IRB no. NSU-1042479-201804-HR-008). Written informed consent was obtained from the patient prior to assessments and therapeutic exercises.

Materials and outcome measures

Low back pain and disability assessments

We used the visual analogue scale (VAS) and Oswestry Disability Index (ODI) in the Korean version as valid and reliable measures for assessing pain and disability. The patient completed ODI and VAS assessments before and after 6 and 12 weeks of the exercise program.

Pain severity was measured using the VAS, with 0 indicating no pain, and 100 mm indicating the worst

pain level. The patient was asked to mark the point on a horizontal line that represented her pain severity. Thus, the VAS score for LBP severity was calculated as the distance from the lowest point on this horizontal line to the point marked by the patient ²⁵.

The ODI has been shown to be a valid and reliable test for assessing pain-related disability in individuals with LBP ²⁶. The ODI has an internal consistency of 0.82–0.90 and a test-retest reliability of 0.88–0.94 ²⁷. Higher ODI scores represent more severe disability.

Lumbar range of motion test

Lumbar range of motion (ROM) in flexion, extension, and lateral flexion was measured using a digital goniometer (Baseline®, Fabrication Enterprises Inc., White Plains, NY, USA), which has been reported as an objective and reliable method ²⁸ and is recommended in international clinical guidelines ²⁹. The upper edge of the sacrum and the lower edge of T12 vertebra were palpated in a patient in a standing position. Measurements were taken first in neutral, then in maximum flexion, and finally in a maximum extension position. In neutral, the patient was asked to stand in a comfortable position with his hands hanging without any effort toward the ground. From this position, she had to perform maximum flexion followed by maximum extension with her knees straight, especially at the end of movement. Then Neutral position and equal axis using measured lateral flexion. The middle of the platform of one inclinometer was put on the spinous process of S1. The inclinometers were zeroed, and the movement of the lumbar spine was read directly from scale of the inclinometer at the extremes of flexion, extension and lateral flexion. To achieve a high measurement reliability, all measurements were made by the same physical therapist and researcher ³⁰. The average of three readings was used for each flexion, extension, and lateral flexion measurement. All lumbar ROM measurements were taken before and after 6 and 12 weeks of the therapeutic exercise program.

Functional movement screen

The functional movement screen (FMS) comprises seven movement tasks and three clearance screens ³¹. The movement tasks are a deep squat, hurdle step, inline lunge, shoulder mobility test, active straight leg raise, trunk stability pushup, and rotary stability test. Five of these tasks (hurdle step, inline lunge, shoulder mobility test, active straight leg raise, and rotary stability test) were performed on both the right and left sides. In the three clearance screens, the presence of pain was assessed during shoulder internal rota-

tion/flexion, end-range spinal flexion, and end-range spinal extension. The FMS is scored on an ordinal scale of 0–3. A score of 3 represents the subject's ability to perform the functional movement pattern as described, a score of 2 indicates that some type of compensation is present when completing the pattern, and a score of 1 is given when the subject is unable to perform the movement pattern. A zero is recorded if there is pain associated with any portion of the tasks or clearance screens ³². The FMS was performed before and after 6 and 12 weeks of the therapeutic exercise program.

Low back muscle endurance test

The Biering-Sørensen muscle endurance test was used to assess muscle endurance in the lower back ³³. The patient was positioned in the prone position on a table, and then moved up until the upper body was off the table and the iliac crests were at the top edge of the table. The lower body was secured to the table with seatbelt straps at the ankles and thighs. The arms were held across the chest with hands placed on opposite shoulders, and the horizontal position was held until exhaustion was reached. The test was stopped as soon as the subject could no longer maintain a horizontal position level with the table. The subject was given one opportunity to reposition their upper body during the test, and standard verbalized encouragement was given to the patient for the duration of the test ³⁴. The Biering-Sørensen muscle endurance test was performed before and after 6 and 12 weeks of the therapeutic exercise program.

Lumbar extension strength test

Isometric lumbar extension strength was evaluated using a lumbar extension exercise device (Daeyang Mechanics, Seoul, Korea). The patient was seated upright, with the pelvis in a stabilized condition. The knees were adjusted to bring the thighs parallel to the seat. The lower legs were placed in the leg supports and secured with lower-leg restraint pads. The anterior thighs and the pelvis were secured to the device with a restraint pad ³⁵. After determining the passive lumbar ROM in the sagittal plane, the subject performed a series of submaximal isometric strength tests and light dynamic exercises to familiarize herself with the device. After a 15-min rest period, the subject was repositioned in the lumbar device as described above, and the maximum voluntary isometric torque output was measured for lumbar extension at seven positions, from 110° to 182° at intervals of 12° ³⁶. When ready for testing, the subject was requested to build up to maximal effort for 2–3 s

and to maintain the contraction for a further 1 s, with a rest interval of 10 s between angle settings. During the test, the subject was given verbal encouragement to generate maximum torque³⁶⁾. The isometric lumbar extension strength tests were performed before and after 6 and 12 weeks of the therapeutic exercise program.

Magnetic resonance imaging

MRI was performed using a 1.5 T unit (Signa, General Electric Medical Systems, Milwaukee, WI, USA). The lumbar spine was evaluated at the L1–S1 levels. The images acquired were sagittal T1-weighted fast spin-echo (FSE), sagittal T2-weighted FSE, and axial T2-weighted FSE (3680/128 repetition time/echo time, 180 × 256 matrix, 280 mm field of view, 4 mm section thickness, NEX = 2). MRI scans were obtained before and after the 12-week therapeutic exercise program.

Experimental procedures

Therapeutic exercise program

We used a modified version of the therapeutic exercise program of Shamsi et al³⁷⁾, which includes limb and spine stretches and strengthening exercises for the abdominal flexor and lumbar extensor muscles. The main exercises conducted for improving lumbar stability and muscle strength were lumbar joint mobilization, lumbar spine flexion-distraction, abdominal bridge, plank, side plank, and single-leg extensions from a 4-point kneeling position. The program was conducted in 40-min sessions, three times a week, for 12 weeks. Each 40-min session included 5 min of stretching as both warm-up and

cool-down exercises (Table 1).

Lumbar joint mobilization treatment was given at the L4 level. It was similar to a typical clinical session, involving 3 cycles of large amplitude of oscillatory posteroanterior forces applied into the end of the available range of each subject, which is equivalent to grade III treatment according to Maitland and Edwards³⁸⁾. Each cycle lasted for about 60 seconds. The treatment was given by a physiotherapist who had received previous training in Maitland and Edwards³⁸⁾ method of spinal mobilization and had more than 5 years of clinical experience in musculoskeletal conditions. The physiotherapist was requested to use an appropriate rate of mobilization and magnitude of force that he/she would generally use in a normative clinical situation.

In the flexion-distraction technique, the therapist touched each patient's lumbar spinous process with the thenar of one hand. He then held the tail handle of the Cox table with his other hand and lowered the caudal pelvic section of the table. In doing so, he applied flexion-distraction motions five times for four to five seconds each time in order to apply distraction for 20 seconds in total. When moving the caudal segment downward, the therapist lowered it to around 5 cm and applied the respective motions for a total of 20 seconds. One set consisted of five repetitions, and three sets were applied to each patient. After applying the flexion-distraction technique, the therapist repeated the foramen magnum pump technique 10 times, applying flexion-distraction motions by lowering the tail unit of the table while supporting the back of the patient's head with one hand³⁹⁾. All techniques and exercise performed by same physical therapist.

Table 1. Components of the therapeutic exercise program

Order	Period	Exercise type	Intensity
Warm-up(5 min)		Stretching	
		Lumbar joint mobilization	
		Lumbar spine flexion-distraction	5 min
Exercises(30 min)	1-12 weeks	Abdominal bridge	30 s hold/rep
		Plank	10 reps × 2 sets
		Side plank	Rest intervals: Between sets: 30 s
		Single-leg extensions from 4-point kneeling position	Between exercises: 60 s
Cool-down(5 min)		Stretching	

RESULTS

Table 2 lists the VAS and ODI scores before and at 6 and 12 weeks of the therapeutic exercise program. The VAS score decreased from 74,00 mm before, to

47,00 and 24,00 mm after 6 and 12 weeks, respectively, of the program. The ODI score decreased from 15,00 before, to 7,00 and 2,00 after 6 and 12 weeks, respectively, of the program.

Table 2. Pain and disability scores before and after 6 and 12 weeks of therapeutic exercise.

	Before	6 weeks	12 weeks
VAS (mm)	74,0	47,0	24,0
ODI (score)	15,0	7,0	2,0

VAS; visual analogue scale, ODI, Oswestry disability index.

Table 3 lists the lumbar ROM values before and at 6 and 12 weeks of the program. Compared with before the program, all four lumbar ROM values were higher after 12 weeks of the program. Table 3 also lists the lumbar muscle endurance and

lumbar FMS scores. FMS score increased after 6 and 12 weeks compared than before, respectively, of the program. Lumbar muscle endurance increased after 6 and 12 weeks compared than before, respectively, of the program.

Table 3. Changes in lumbar ROM, endurance, and FMS before and after therapeutic exercise.

	Before	6 weeks	12 weeks
Flexion (°)	75,5	81,3	85,7
Extension (°)	24,5	33,1	33,8
Rt. lateral flexion (°)	18,0	21,2	23,0
Lt. lateral flexion (°)	21,0	23,1	26,8
Endurance (s)	13,0	23,7	29,3
FMS (score)	11,0	13,0	16,0

ROM, range of movement; FMS, functional movement screen.

Over the course of the program, the isometric lumbar extension strength increased (Fig. 1) and the disc

herniations decreased in size (Fig. 2).

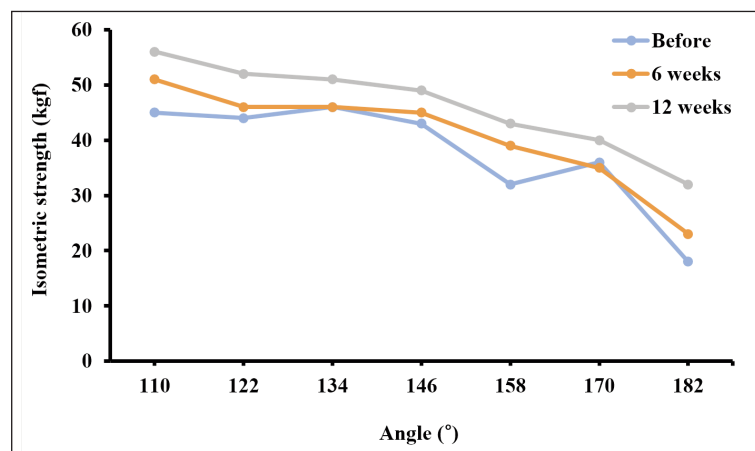


Fig. 1. Change in lower back strength before and after 6 and 12 weeks of therapeutic exercise. Values were measured at 110°, 122°, 134°, 146°, 158°, 170°, and 182° during the isometric lumbar extension strength test.

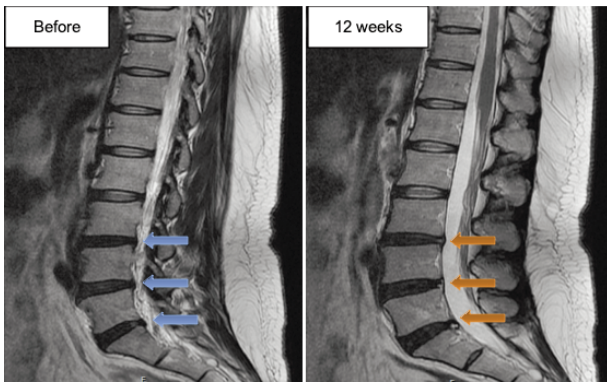


Fig. 2. Changes in the extent of disc herniation (arrows) at L3-L4, L4-L5, and L5-S1 before and after 12 weeks of therapeutic exercise.

DISCUSSION

We evaluated the patient's LBP using qualitative and quantitative assessments. The effects of the therapeutic exercise program were evaluated in detail using clinical (physical examination and pain and disability score measurements) and imaging (MRI) parameters. MRI provides an objective measure of the effectiveness of treatment. After 12 weeks of the therapeutic exercise, there was a reduction in the size of the disc herniations on MRI, and improvements in the physical examination findings and pain disability scores. It is previously reported that therapeutic exercise can effectively relieve low back and leg pain by reducing the size of the disc herniations in patients with multilevel LDH²³. Following therapeutic exercise, our patient described a decreased pain intensity in the lower back and legs, and improved performance in ROM and strength tests.

The most common therapies for LBP are those based on stabilization of the lumbar spine in exercise-based programs. Such an exercise program can improve the ROM of the spine via stretching exercises, increasing muscle power via strengthening exercises, and correcting postural deficits via control exercises. They can also reduce pain⁴⁰ and improve functional abilities by improving ROM, muscle strength, and body posture^{41, 42}, as a comprehensive rehabilitation program that comprises postural training, deep muscle reactivation, stretching, and strengthening of the prime movers of the spine and subsequent progression to functional exercises^{20, 23, 24}. Therefore, the best therapeutic exercise mechanism for relieving low back and leg pain and improving

functional capacity in patients with multilevel LDH will probably increase muscle strength, and improve body posture and ROM of the spine.

Previous studies have reported that therapeutic exercise programs based on lumbar spine stabilization show improvements in the musculature of the transversus abdominis⁴³, in the activation of the transversus abdominis⁴⁴ and multifidus⁴⁵, and in proprioception⁴⁶. Improvements in the musculature of the transversus abdominis and proprioceptive action, along with co-contraction of the transversus abdominis and multifidus muscles, increase lumbosacral segmental stability^{20, 23, 24, 47}. In turn, improved lumbosacral segmental stability helps reduce compressive overloads and attenuates or eradicates the back pain associated with instability. This leads to improvement in functional capacity and helps prevent lumbar disc disease⁴⁵, based on evidence from previous studies regarding the relationship between disc herniation and instability^{46, 49, 50, 51}.

Compared with computed tomography, MRI provides more detailed information on disc herniation and its natural history^{52, 53}. In the present study, repeated MRI revealed significant morphological regression of the herniated discs. Unlu et al²¹, performed computed tomography before and during lumbar traction to assess whether retraction of herniated disc material occurred during the traction. In approximately two-thirds of the patients in that study, the herniated portion retracted partially, or disappeared. Sari et al⁵⁴, and Ozturk et al⁵⁵, used computed tomography in a quantitative and detailed evaluation of the effect of lumbar spinal traction on herniated material in patients with LDH and found that lumbar spinal traction decreased the size of the herniated disc and resulted in improved symptoms and clinical findings. The advent of MRI has enabled imaging of spontaneous decreases in the size of herniated discs^{56, 57}. In general, it takes 6 months for the morphologic changes in a herniated disc to become visible on MRI⁵⁸. Takada et al⁵⁷, demonstrated effective reductions in the degree of protrusion of a herniated disc on MRI at 6-12 months after the onset of symptoms in 37 of 42 patients, whereas Slavin et al⁵⁶, reported the complete disappearance of an extruded fragment on an MRI obtained ~30 weeks after the original MRI examination. In both of these studies, the patients had received various medical treatments or physical therapies. In the present study, the significant changes in the MRI findings after a short period (12 weeks) of therapeutic exercise are evidence of the beneficial effects of the program.

Our results are consistent with those of a recent review of the efficacy of therapeutic exercise programs that involve exercise-based lumbar spine stabilization for LDH¹⁵, even multilevel LDH. They suggested that a therapeutic exercise program is effective for the reduction of pain, disability, and hernia protrusion in patients with LDH.

The limitation of our current study is case report. Furthermore, the VAS and ODI are both subjective outcomes of measure which can be suboptimal in their reliability as we are dependent on the patient's perception of their pain and functional capacity.

CONCLUSION

We demonstrated that therapeutic exercise in a patient with multilevel LDH had the effects of decreased LBP, increased lumbar ROM and muscle strength, improved functional capacity, and an apparent reduction in the size of the disc herniations. These findings have clinical implications for therapeutic exercise in such patients.

REFERENCES

1. Hakan T, Gürçan S. Spontaneous regression of herniated lumbar disc with new disc protrusion in the adjacent level. *Case Rep Orthop* 2016; 1538072.
2. Jönsson B, Strömquist B. The straight leg raising test and the severity of symptoms in lumbar disc herniation. A preoperative evaluation. *Spine (Phila Pa 1976)* 1995; 20(1): 27–30.
3. Zhao WP, Kawaguchi Y, Matsui H et al. Histochemistry and morphology of the multifidus muscle in lumbar disc herniation: comparative study between diseased and normal sides. *Spine (Phila Pa 1976)* 2000; 25(17): 2191–9.
4. Ye C, Ren J, Zhang J et al. Comparison of lumbar spine stabilization exercise versus general exercise in young male patients with lumbar disc herniation after 1 year of follow-up. *Int J Clin Exp Med* 2015; 8(6): 9869–75.
5. Khan ZH, Hamidi S, Miri M et al. Post-operative pain relief following intrathecal injection of acetylcholine esterase inhibitor during lumbar disc surgery: a prospective double blind randomized study. *J Clin Pharm Ther* 2008; 33(6): 669–75.
6. Wu H, Yu WD, Jiang R et al. Treatment of multilevel degenerative lumbar spinal stenosis with spondylolisthesis using a combination of microendoscopic discectomy and minimally invasive transforaminal lumbar interbody fusion. *Exp Ther Med* 2013; 5(2): 567–71.
7. Kamanli A, Karaca-Acet G, Kaya A et al. Conventional physical therapy with lumbar traction; clinical evaluation and magnetic resonance imaging for lumbar disc herniation. *Bratisl Lek Listy* 2010; 111(10): 541–4.
8. Awad JN, Moskovich R. Lumbar disc herniations: surgical versus nonsurgical treatment. *Clin Orthop Relat Res* 2006; 443: 183–97.
9. Schiphorst Preuper HR, Reneman MF, Boonstra AM et al. The relationship between psychosocial distress and disability assessed by the Symptom Checklist-90-Revised and Roland Morris Disability Questionnaire in patients with chronic low back pain. *Spine J* 2007; 7(5): 525–30.
10. Jansson KA, Németh G, Granath F et al. Surgery for herniation of a lumbar disc in Sweden between 1987 and 1999. *J Bone Joint Surg [Br]* 2004; 86: 841–7.
11. McCulloch JA. Focus issue on lumbar disc herniation: macro- and microdiscectomy. *Spine (Phila Pa 1976)* 1996; 21(24 Suppl): 45S–56S.
12. Bozzao A, Gallucci M, Masciocchi C et al. Lumbar disk herniation: MR imaging assessment of natural history in patients treated without surgery. *Radiology* 1992; 185(1): 135–41.
13. Cassidy JD, Thiel HW, Kirkaldy-Willis WH. Side posture manipulation for lumbar intervertebral disk herniation. *J Manipulative Physiol Ther* 1993; 16(2): 96–103.
14. Nasser MJ. How to approach the problem of low back pain: an overview. *J Family Community Med* 2005; 12(1): 3–9.
15. Shimia M, Babaei-Ghazani A, Sadat BE et al. Risk factors of recurrent lumbar disk herniation. *Asian J Neurosurg.* 2013; 8(2): 93–6.
16. Yazdani AH, Hesari P, Eghbali-Khosro S et al. Effects of six-week exercise training protocol on pain relief in patients with lumbar disc herniation. *J Anal Res Clin Med* 2016; 4(1): 27–33.
17. Troyanovich SJ, Harrison DD, Harrison DE. Low back pain and the lumbar intervertebral disk: clinical considerations for the doctor of chiropractic. *J Manipulative Physiol Ther* 1999; 22(2): 96–104.
18. Luijsterburg PA, Verhagen AP, Braak S et al. Neurosurgeons' management of lumbosacral

- radicular syndrome evaluated against a clinical guideline. *Eur Spine J* 2004; 13(8): 719–23.
19. Hahne AJ, Ford JJ, Hinman RS et al. Outcomes and adverse events from physiotherapy functional restoration for lumbar disc herniation with associated radiculopathy. *Disabil Rehabil* 2011; 33(17–18): 1537–47.
 20. Kennedy DJ, Noh MY. 2011. The role of core stabilization in lumbosacral radiculopathy. *Phys Med Rehabil Clin N Am* 2011; 22(1): 91–103.
 21. Unlu Z, Tasci S, Tarhan S et al. Comparison of 3 physical therapy modalities for acute pain in lumbar disc herniation measured by clinical evaluation and magnetic resonance imaging. *J Manipulative Physiol Ther* 2008; 31: 191–8.
 22. Barr KP, Griggs M, Cadby T. Lumbar stabilization: core concepts and current literature, Part 1. *Am J Phys Med Rehabil* 2005; 84: 473–80.
 23. Akuthota V, Ferreiro A, Moore T et al. Core stability exercise principles. *Curr Sports Med Rep* 2008; 7: 39–44.
 24. Byström M, Rasmussen-Barr E, Grooten W. Motor control exercises reduces pain and disability in chronic and recurrent low back pain. A meta-analysis. *Spine* 2013; 38: E350–E358.
 25. Parker SL, Godil SS, Mendenhall SK et al. Two-year comprehensive medical management of degenerative lumbar spine disease (lumbar spondylolisthesis, stenosis, or disc herniation): a value analysis of cost, pain, disability, and quality of life: clinical article. *J Neurosurg Spine* 2014; 21(2): 143–9.
 26. Fairbank JC, Pynsent PB. The Oswestry Disability Index. *Spine (Phila Pa 1976)* 2000; 25(22): 2940–52.
 27. Roland M, Fairbank J. The Roland–Morris Disability Questionnaire and the Oswestry Disability Questionnaire. *Spine (Phila Pa 1976)* 2000; 25(24): 3115–24.
 28. Youdas JW, Carey JR, Garrett TR. Reliability of measurements of cervical spine range of motion—comparison of three methods. *Phys Ther*. 1991; 71(2): 98–104
 29. Saur PM, Ensink FB, Frese K et al. Lumbar range of motion: reliability and validity of the inclinometer technique in the clinical measurement of trunk flexibility. *Spine (Phila Pa 1976)* 1996; 21(11): 1332–8.
 30. Delitto A, George SZ, Van Dillen LR et al. Low back pain. *J Orthop Sports Phys Ther* 2012; 42(4): A1–57.
 31. Cook G, Burton L, Hoogenboom BJ et al. Functional movement screening: the use of fundamental movements as an assessment of function—Part 1. *Int J Sports Phys Ther*. 2014; 9(3): 396–409.
 32. Shultz R, Anderson SC, Matheson GO et al. Test–retest and interrater reliability of the functional movement screen. *J Athl Train* 2013; 48(3): 331–6.
 33. The Canadian Physical Activity, Fitness and Lifestyle Approach. Edition 3. Publisher. Canadian Society for Exercise Physiology 2004.
 34. McKeon MD, Albert WJ, Neary JP. Assessment of neuromuscular and haemodynamic activity in individuals with and without chronic low back pain. *Dyn Med* 2006; 5: 6.
 35. Lee HS. Enhanced muscle activity during lumbar extension exercise with pelvic stabilization. *J Exerc Rehabil* 2015; 11(6): 372–7.
 36. Graves JE, Webb DC, Pollock ML et al. Pelvic stabilization during resistance training: its effect on the development of lumbar extension strength. *Arch Phys Med Rehabil* 1994; 75(2): 210–5.
 37. Shamsi MB, Sarrafzadeh J, Jamshidi A. Comparing core stability and traditional trunk exercise on chronic low back pain patients using three functional lumbopelvic stability tests. *Physiother Theory Pract* 2015; 31(2): 89–98.
 38. Maitland GD, Edwards BC. *Vertebral manipulation*, 5th ed. Oxford: Butterworth–Heinemann; 1993
 39. Kwon WA, Ryu YS, Ma SY. The effects of Cox distraction manipulation on functional assessment measures and disc herniation index in patients with L4–5 herniated disc. *Journal of the Korean Data & Information Science Society*, 2012, 23: 727–38
 40. Duncan C, Arantxa B, James M. Effects of Low Grade Axial Loading on Discogenic Low Back Pain: A Case Report. *J Int Acad Phys Ther Res* 2018; 9(4): 1683–9
 41. Dzierżanowski M, Dzierżanowski M, Maćkowiak P et al. The influence of active exercise in low positions on the functional condition of the lumbar–sacral segment in patients with discopathy. *Adv Clin Exp Med* 2013; 22(3): 421–30.
 42. Kachanathu SJ, Alenazi AM, Seif HE et al. Comparison between kinesio taping and a traditional physical therapy program in treatment of nonspecific low back pain. *J Phys Ther Sci* 2014; 26(8): 1185–8.

43. Byström MG, Rasmussen-Barr E, Grooten WJ. Motor control exercises reduces pain and disability in chronic and recurrent low back pain: a meta-analysis. *Spine (Phila Pa 1976)* 2013; 38(6): E350–358.
44. França FR, Burke TN, Hanada ES et al. Segmental stabilization and muscular strengthening in chronic low back pain: a comparative study. *Clinics (Sao Paulo)* 2010; 65(10): 1013–7.
45. Hebert JJ, Kopenhagen SL, Magel JS et al. The relationship of transversus abdominis and lumbar multifidus activation and prognostic factors for clinical success with a stabilization exercise program: a cross-sectional study. *Arch Phys Med Rehabil* 2010; 91: 78–85.
46. Iguchi T, Kanemura A, Kasahara K, et al. Age distribution of three radiologic factors for lumbar instability: probable aging process of the instability with disc degeneration. *Spine* 2003; 28(23): 2628–33.
47. Barr KP, Griggs M, Cadby T. Lumbar stabilization: a review of core concepts and current literature, Part 2. *Am J Phys Med Rehabil* 2007; 86: 72–80.
48. Barr KP, Griggs M, Cadby T. Lumbar stabilization: core concepts and current literature, Part 1. *Am J Phys Med Rehabil* 2005; 84: 473–80.
49. Zhao F, Pollintine P, Hole BD et al. Discogenic origins of spinal instability. *Spine (Phila Pa 1976)* 2005; 30: 2621–30.
50. Hasegawa K, Shimoda H, Kitahara K et al. What are the reliable radiological indicators of lumbar segmental instability? *J Bone Joint Surg Br* 2011; 93: 650–7.
51. Ohmori K. Clinical application of a novel assessment for lumbosacral stability. *J Neurosurg Spine* 2010; 13: 276–82.
52. Fager CA. Observations on spontaneous recovery from intervertebral disc herniation. *Surg Neurol* 1994; 42(4): 282–6.
53. Komori H, Okawa A, Haro H et al. Factors predicting the prognosis of lumbar radiculopathy due to disc herniation. *J Orthop Sci* 2002; 7(1): 56–61.
54. Sari H, Akarirmak U, Karacan I et al. Computed tomographic evaluation of lumbar spinal structures during traction. *Physiother Theory Pract* 2005; 21(1): 3–11.
55. Ozturk B, Gunduz OH, Ozoran K et al. Effect of continuous lumbar traction on the size of herniated disc material in lumbar disc herniation. *Rheumatol Int* 2006; 26(7): 622–6.
56. Slavin KV, Raja A, Thornton J et al. Spontaneous regression of a large lumbar disc herniation: report of an illustrative case. *Surg Neurol* 2001; 56(5): 333–6.
57. Takada E, Takahashi M, Shimada K. Natural history of lumbar disc hernia with radicular leg pain: Spontaneous MRI changes of the herniated mass and correlation with clinical outcome. *J Orthop Surg (Hong Kong)* 2001; 9(1):1–7.
58. Benoist M. The natural history of lumbar disc herniation and radiculopathy. *Joint Bone Spine* 2002; 69(2):155–60.