


# Diversion of the mandibular canal: Is it the best predictor of inferior alveolar nerve damage during mandibular third molar surgery on panoramic radiographs?

Melek Tassoker <sup>1,\*</sup>

<sup>1</sup>Department of Oral and Maxillofacial Radiology, Faculty of Dentistry, Necmettin Erbakan University, Konya, Turkey

## ABSTRACT

**Purpose:** The aim of this study was to evaluate the relationship between the mandibular canal and impacted mandibular third molars using cone-beam computed tomography (CBCT) and to compare the CBCT findings with signs on panoramic radiographs (PRs).

**Materials and Methods:** This retrospective study consisted of 200 mandibular third molars from 200 patients who showed a close relationship between the mandibular canal and impacted third molars on PRs and were referred for a CBCT examination of the position of the mandibular canal. The sample consisted of 124 females and 76 males, with ages ranging from 18 to 47 years (mean,  $25.75 \pm 6.15$  years). PRs were evaluated for interruption of the mandibular canal wall, darkening of the roots, diversion of the mandibular canal, and narrowing of the mandibular canal. Correlations between the PR and CBCT findings were statistically analyzed.

**Results:** In total, 146 cases (73%) showed an absence of canal cortication between the mandibular canal and impacted third molar on CBCT images. A statistically significant relationship was found between CBCT and PR findings ( $P < 0.05$ ). The absence of canal cortication on CBCT images was most frequently accompanied by the PR sign of diversion of the mandibular canal (96%) and least frequently by interruption of the mandibular canal wall (65%).

**Conclusion:** CBCT examinations are highly recommended when diversion of the mandibular canal is observed on PR images to reduce the risk of mandibular nerve injury, and this sign appears to be more relevant than other PR signs. (*Imaging Sci Dent 2019; 49: 213-8*)

**KEY WORDS:** Mandibular Nerve; Tooth, Impacted; Cone-Beam Computed Tomography; Radiography, Panoramic

## Introduction

Extraction of the lower third molars (LM3s) is one of the most frequent procedures in oral surgery.<sup>1</sup> This surgical procedure may lead to damage to the inferior alveolar nerve (IAN) in 0.4%-8% of cases, resulting in complications such as hypoesthesia and dysesthesia.<sup>1,2</sup> Horizontal angulation, deep impaction, less experience of the operator, and close proximity of the inferior alveolar canal (IAC) to the LM3 have been suggested as risk factors for IAN injury.<sup>3</sup>

Complications can be predicted before surgery by careful

preoperative radiographic analysis.<sup>2</sup> Although panoramic radiographs (PRs) are the most widely used method by oral surgeons to determine the risk of IAN injury,<sup>1</sup> cone-beam computed tomography (CBCT) provides excellent localization of the IAC and LM3 in 3 dimensions without overlapping, distortion, and magnification,<sup>2,4</sup> with lower radiation exposure than medical CT.<sup>5</sup> However, CBCT has higher costs, less availability, and a higher radiation dose than PR.<sup>6</sup>

CBCT was found to be a reliable imaging modality for determining the anatomical relationships between the IAC and LM3.<sup>5</sup> Three-dimensional imaging studies revealed the following 3 reliable radiological predictors of IAN injury: the shape of the IAC, the position of IAC, and the absence of cortication between the IAC and LM3.<sup>7</sup> Moreover, it was reported that the combined use of these factors could

Received April 29, 2019; Revised July 8, 2019; Accepted July 17, 2019

\*Correspondence to : Prof. Melek Tassoker

Department of Oral and Maxillofacial Radiology, Faculty of Dentistry, Necmettin Erbakan University, Ankara Street, 42050 Konya, Turkey  
Tel) 90-332-2200025, E-mail) dishekmelek@gmail.com

Copyright © 2019 by Korean Academy of Oral and Maxillofacial Radiology

This is an Open Access article distributed under the terms of the Creative Commons Attribution Non-Commercial License (<http://creativecommons.org/licenses/by-nc/3.0>) which permits unrestricted non-commercial use, distribution, and reproduction in any medium, provided the original work is properly cited.

Imaging Science in Dentistry · pISSN 2233-7822 eISSN 2233-7830

increase the accuracy of predicting IAN injury.<sup>7</sup>

Determining risk factors before surgery is important for surgeons and patients. Some specific signs that may be observed on PRs may suggest a close relationship between the IAC and LM3.<sup>8</sup> These radiographic signs include interruption of the mandibular canal wall, darkening of the roots, diversion of the mandibular canal, and narrowing of the mandibular canal.<sup>8</sup> The present study aimed to evaluate the relationship between the IAC and impacted LM3 using CBCT and to compare the CBCT findings with signs on PR.

## Materials and Methods

### Study design and sample

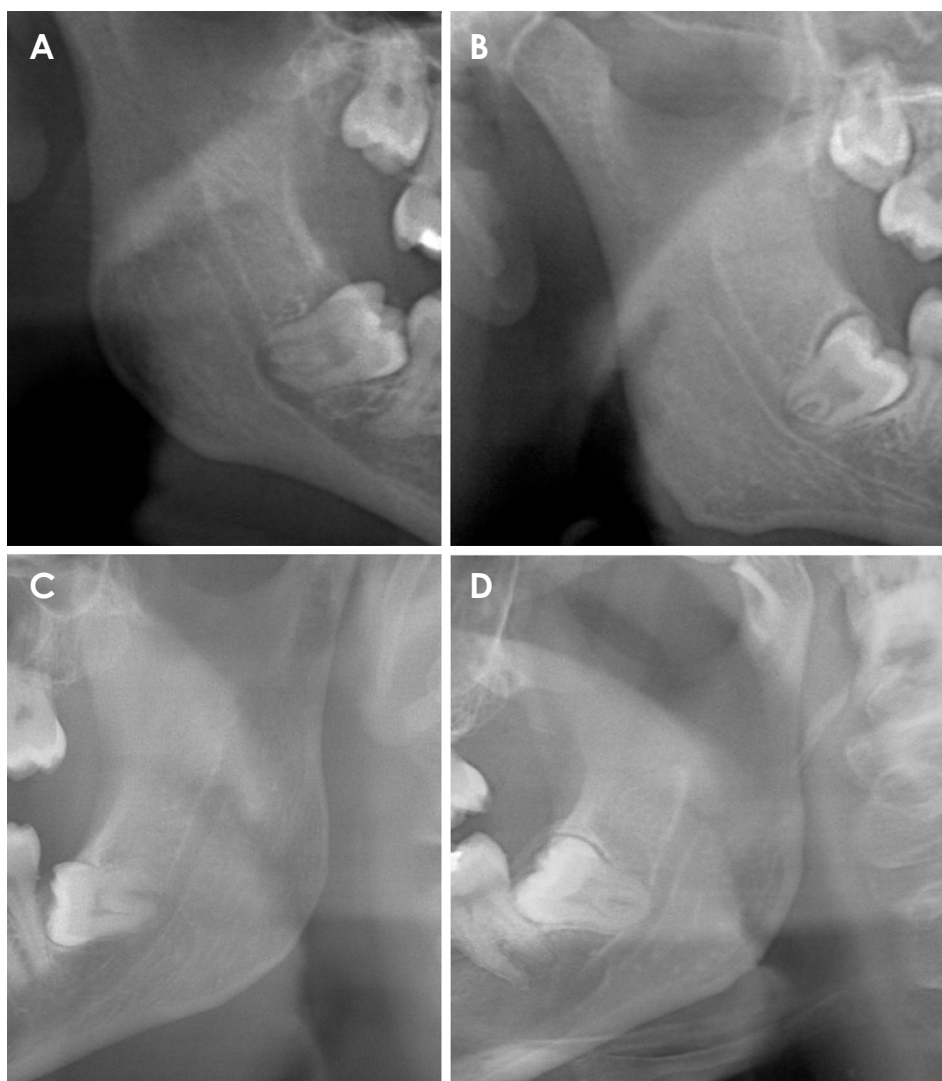
This retrospective study was approved by the Necmettin Erbakan University Research Ethics Committee and complied with the guidelines laid out in the Declaration of Helsinki (decision no: 2019/03). A total of 200 patients

were selected randomly, with a mean age of  $25.75 \pm 6.15$  years (range, 18-47 years). Of the 200 individuals, 76 (38%) were male (mean age,  $26.76 \pm 6.13$  years) and 124 (62%) were female (mean age,  $25.12 \pm 6.11$  years). Patients were referred to our radiology department to obtain PRs required for dental examinations. CBCT analysis was performed as part of their oral examination for third molar surgery when PR signs suggested a close relationship of the LM3 with the IAC.

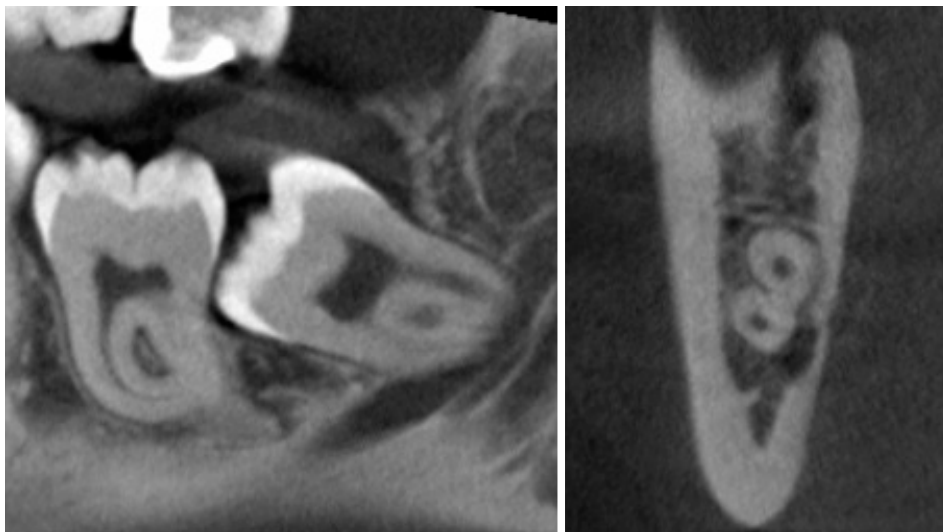
### Image assessment

200 impacted LM3s were evaluated from 200 patients presenting a close relationship between the LM3 and IAC on PR. Patients with a pathology such as tumor or cyst around the LM3 or incomplete root formation of the LM3 were excluded.

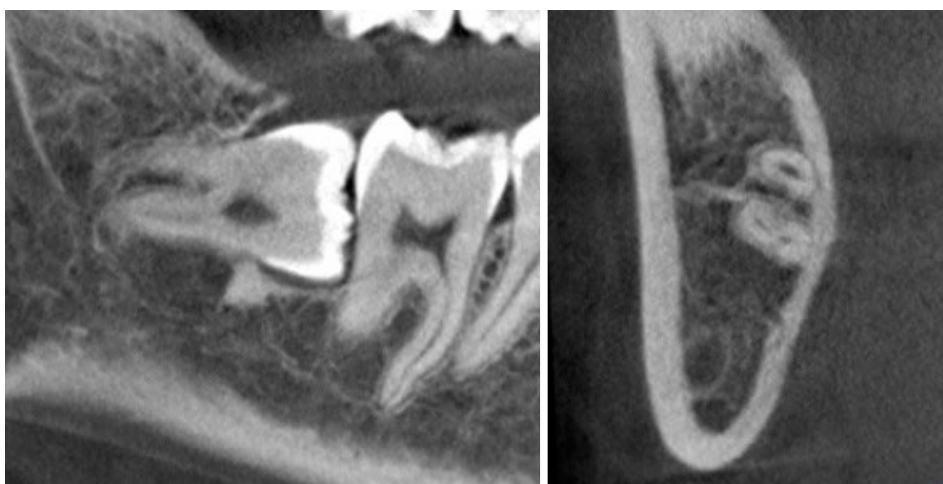Initially, the most common signs related to higher risk of IAN injury were recorded, including interruption of the



**Fig. 1.** Cropped panoramic images show darkening of the roots (A), diversion of mandibular canal (B), interruption of the mandibular canal wall (C), and narrowing of the mandibular canal (D).



**Fig. 2.** Lingually positioned inferior alveolar canal without cortication.



**Fig. 3.** Inferiorly located inferior alveolar canal with cortication.

mandibular canal wall, darkening of the roots, diversion of the mandibular canal, and narrowing of the mandibular canal (Fig. 1).<sup>9,10</sup> They were defined as follows: 1) interruption of the mandibular canal wall: loss of the cortical margin of the IAC where it crossed the LM3; 2) darkening of the roots: increased radiolucency of the root of LM3 where the IAC crossed it; 3) diversion of the mandibular canal: change in the direction of the IAC due to the root of LM3; 4) narrowing of the mandibular canal: a decrease in the width of the IAC while it crosses the LM3.

After that, the presence or absence of cortication between the LM3 and IAC was evaluated on cross-sectional CBCT slices (Figs. 2 and 3). Cross-sectional CBCT slices were preferred because these slices visualize the relationship between LM3 and adjacent anatomy most clearly.<sup>11</sup> Loss of bone tissue between LM3 root and IAC was defined as the absence of cortication.<sup>2,7,9,10,12</sup>

All observations were performed by the same maxillofacial radiologist, with at least 5 years of experience. The age and sex of the patients, region of the impacted LM3 (right-left), angulation of LM3 (mesioangular, distoangular, horizontal, or vertical), and course of the IAC relative to the roots of LM3 (buccal, lingual, inferior, or interradicular) were also recorded.

#### Scanning and screening procedures

All PRs were taken with a dental X-ray machine (Morita Veraviewepocs 3D R100-P, J Morita MFG Corp., Kyoto, Japan) at 70 kVp, 10 mA, and 10 s according to the manufacturer's recommended protocol.

CBCT images were acquired in a sitting position using a Morita 3D Accuitomo 170 device (J Morita MFG Corp., Kyoto, Japan), which was operated at 90 kVp and 5 mA, with 17.5 seconds of rotation time, a voxel size of 0.25 mm,

and a field-of-view of 100 mm, according to the manufacturer’s recommended protocol.

The PR images and CBCT slices were evaluated by the same investigator in a darkened room using a 27-inch flat panel color display with resolution of 2560 × 1600 pixels (U2711HTM; Dell, Round Rock, TX, USA). All CBCT images were evaluated using i-Dixel software (J Morita MFG Corp., Kyoto, Japan) in all 3 planes (sagittal, axial, and coronal). Cross-sectional reconstructions were also used.

### Statistical analyses

The PR and CBCT results were evaluated using the Pearson chi-square test. Logistic regression analysis was applied and odds ratios (ORs) were calculated for the PR signs. The kappa test was done to test intraobserver consistency. Statistical analysis was performed with SPSS software version 21.0 (IBM Corp, Armonk, NY, USA) with a significance level of  $P < 0.05$ .

### Results

The kappa values were excellent (between 0.82 and 0.94) for all observations. Of the 200 teeth examined on cross-sectional CBCT sections, 54 (27%) of the LM3s showed cortication and 146 (73%) of them did not. Sex, site of the LM3, and Winter’s classification were not found to be associated with cortication status. The distribution of the study parameters is given in Table 1. The majority of the cases had an IAC course inferior to the LM3 ( $n = 100$ ; 50%). There was a statistically significant relationship between IAC course and cortication status. The interradicular IAC position showed the highest percentage of absence of cortication (100%) and the buccal IAC position showed the low-

est (36%).

The most frequently observed PR sign was interruption of the mandibular canal wall. There was a statistically significant relationship between PR signs and cortication status ( $P < 0.05$ ) (Table 2). The PR sign of diversion of the mandibular canal was the only risk factor for the absence of cortication (OR = 12.41; 95% CI, 1.60 to 96.27;  $P = 0.016$ ;  $P < 0.05$ ) (Table 2).

### Discussion

The absence of cortical bone in the IAC may not be clearly evident on PR. Moreover, it is impossible to determine whether its course is buccal or lingual to the roots or between the roots.<sup>13</sup> At our dental faculty, the standard preoperative examination relies on PR. If the radiological signs on PR are suggestive of an close relationship between the LM3 and IAC, additional imaging is recommended for a further examination.<sup>8</sup> However, some surgeons routinely obtain preoperative CBCT before LM3 surgery to avoid legal issues. Although PR does not provide any information regarding the buccolingual dimension,<sup>8</sup> it can sometimes be used as the sole preoperative examination for LM3 surgery due to the lower availability of CBCT, especially in developing countries considering their socioeconomic conditions.<sup>8</sup> Turkey is a developing country and CBCT is not easy to access in every region. For this reason, the present study aimed to evaluate the relationship between the IAC and impacted LM3 using CBCT and to compare CBCT findings with signs of PR.

Sedaghatfar et al.<sup>14</sup> showed that the following 4 PR features were significantly associated with mandibular nerve exposure following third molar extraction: darkening of the

**Table 1.** Distribution of the study parameters

Variables		Presence of cortication, n (%)	Absence of cortication, n (%)	P value	Total number of cases (%)
Sex	Female	29 (23)	95 (77)	.189	124 (72)
	Male	25 (33)	51 (67)		76 (28)
Site of LM3	Right	21 (23)	72 (77)	.205	93 (46)
	Left	33 (31)	74 (69)		107 (54)
Winter’s classification	Mesioangular	20 (21)	74 (79)	.133	94 (47)
	Distoangular	2 (14)	12 (86)		14 (7)
	Horizontal	11 (33)	22 (67)		33 (17)
	Vertical	21 (36)	38 (64)		59 (29)
Position of IAC in relation to the LM3	Buccal side	23 (64)	13 (36)	<0.05	36 (18)
	Lingual side	6 (11)	49 (89)		55 (28)
	Below	25 (25)	75 (75)		100 (50)
	Interradicular	0 (0)	9 (100)		9 (4)

IAC: inferior alveolar canal, LM3: lower mandibular third molar

**Table 2.** Relationships between signs on panoramic images and cortication status

Signs on panoramic images	Presence of cortication, n (%)	Absence of cortication, n (%)	OR (95% CI)	P value	Total, n (%)
Interruption of the mandibular canal wall	30 (35)	58 (65)	1 (reference)	.079	88 (44.0)
Darkening of the root	13 (30)	31 (70)	1.23 (0.56-2.70)	.600	44 (22.0)
Diversion of the mandibular canal	1 (4)	24 (96)	12.41 (1.60-96.27)	<0.05	25 (12.5)
Narrowing of the mandibular canal	10 (24)	33 (76)	1.70 (0.74-3.92)	.209	43 (21.5)
Total	54	146			200 (100.0)

Chi-square test;  $P=0.024$ ,  $P<0.05$

root, interruption of the white line of the mandibular canal wall, diversion of the mandibular canal, and narrowing of the mandibular canal. These PR signs were analyzed in this study, and the most frequent PR sign was interruption of the mandibular canal wall, with a percentage of 44%.

In a recent study,<sup>12</sup> the cortication status between the LM3 and IAC was found to be a reliable predictor of IAN injury. In the present study, CBCT analyses were performed when PR signs suggested a close relationship of the LM3 to the IAC. In total, 54 (27%) of the LM3s showed cortication and 146 (73%) of them did not. There was a statistically significant relationship between PR signs and cortication status ( $P<0.05$ ) (Table 2). The PR sign of diversion of the mandibular canal was found to be the only risk factor for the absence of cortication (OR = 12.41; 95% CI, 1.60-96.27;  $P=0.016$ ;  $P<0.05$ ), with a roughly 12 times higher risk than other PR signs for the absence of cortication around IAN. In a clinical study after LM3 extraction, it was shown that diversion of the mandibular canal had a similar OR (10.41) to that reported in the current study. Excessive hemorrhage, a procedure-related parameter, was found to be the riskiest condition for IAN injury in that study, with a OR of 99.04. In another study,<sup>15</sup> it was also found that diversion of the mandibular canal was the best diagnostic marker, followed by darkening of the root and interruption of the mandibular canal wall. Diversion of the mandibular canal is indicative of a nerve running between the roots, or a nerve sandwiched between the root and the mandibular cortical bone.<sup>2</sup>

The best diagnostic PR sign is quite controversial in the literature. Hasani et al.<sup>2</sup> was indicated that interruption of the mandibular canal wall was the best indicator of risk for IAN injury. The variable results across previous studies might be attributed to sample variations, differences in observer experience, the use of different devices, and methodological diversity.<sup>2</sup>

IAN injury has been reported to be associated with procedure-related and radiographic factors, rather than demo-

graphic factors such as age and sex. Similarly, we found that sex was not related; however, the course of IAC was related to cortication status, which is an important predictor of IAN injury. This study revealed that the riskiest course of IAC in relation to the LM3 was interradicular. Nine IACs had a course that was identified as interradicular on cross-sectional CBCT examinations, and none of those IACs showed cortication. The majority of the IACs had an inferior course, corresponding to half of the sample (100 cases). The literature shows variable results in this regard.<sup>1</sup> In a recently reported conflicting study, lingually-positioned and dumbbell-shaped IACs were reported to pose a high risk for IAN damage. Our results showed that the site (right-left) and angulation of LM3 were also not associated with cortication status.

Panoramic imaging has inherent limitations such as distortion, magnification, and overlapping. However, it is widely accessible and has low cost and low radiation exposure compared to CBCT.<sup>16</sup> It was found that CBCT was superior to panoramic imaging in predicting neurovascular bundle exposure.<sup>10</sup> However, in a recent meta-analysis,<sup>6</sup> it was concluded that 3-dimensional imaging neither reduces patients' risk of experiencing IAN injuries nor affects their prognosis. It might only be useful for the diagnosis and surgical plan of LM3s.

As a limitation, this was a cross-sectional radiological study. Although diversion of the mandibular canal and an interradicular position of the IAC were found to be related with absence of cortication, there was no clinical correlation after LM3 surgery.

In conclusion, considering the frequent absence of cortication (73%) detected on cross-sectional CBCT slices, surgeons should pay attention during LM3 surgery regardless of whether a CBCT scan is obtained. The PR sign of diversion of the mandibular canal, which is related to a 12-fold higher risk of absence of cortication should be considered as a potential predictive parameter of IAN injury. When this specific PR sign is observed, 3-dimensional im-

aging is highly recommended. If this radiological finding is recognized on PR and there is no possibility of a CBCT examination, the surgeon may be advised to plan alternative low-risk procedures such as coronectomy. Due to the fact that an interradicular course of the IAC was found to be related with the absence of cortication, surgeons should be cautious regarding possible IAN damage when this IAC position is observed.

## References

1. Hasegawa T, Ri S, Shigeta T, Akashi M, Imai Y, Kakei Y, et al. Risk factors associated with inferior alveolar nerve injury after extraction of the mandibular third molar - a comparative study of preoperative images by panoramic radiography and computed tomography. *Int J Oral Maxillofac Surg* 2013; 42: 843-51.
2. Hasani A, Ahmadi Moshtaghin F, Roohi P, Rakhshan V. Diagnostic value of cone beam computed tomography and panoramic radiography in predicting mandibular nerve exposure during third molar surgery. *Int J Oral Maxillofac Surg* 2017; 46: 230-5.
3. Szalma J, Lempel E, Jeges S, Szabó G, Olasz L. The prognostic value of panoramic radiography of inferior alveolar nerve damage after mandibular third molar removal: retrospective study of 400 cases. *Oral Surg Oral Med Oral Pathol Oral Radiol Endod* 2010; 109: 294-302.
4. Ghai S, Choudhury S. Role of panoramic imaging and cone beam CT for assessment of inferior alveolar nerve exposure and subsequent paresthesia following removal of impacted mandibular third molar. *J Maxillofac Oral Surg* 2018; 17: 242-7.
5. Korkmaz YT, Kayıpmaz S, Senel FC, Atasoy KT, Gumrukcu Z. Does additional cone beam computed tomography decrease the risk of inferior alveolar nerve injury in high-risk cases undergoing third molar surgery? Does CBCT decrease the risk of IAN injury? *Int J Oral Maxillofac Surg* 2017; 46: 628-35.
6. Clé-Ovejero A, Sánchez-Torres A, Camps-Font O, Gay-Escoda C, Figueiredo R, Valmaseda-Castellón E. Does 3-dimensional imaging of the third molar reduce the risk of experiencing inferior alveolar nerve injury owing to extraction?: A meta-analysis. *J Am Dent Assoc* 2017; 148: 575-83.
7. Tachinami H, Tomihara K, Fujiwara K, Nakamori K, Noguchi M. Combined preoperative measurement of three inferior alveolar canal factors using computed tomography predicts the risk of inferior alveolar nerve injury during lower third molar extraction. *Int J Oral Maxillofac Surg* 2017; 46: 1479-83.
8. Elkhateeb SM, Awad SS. Accuracy of panoramic radiographic predictor signs in the assessment of proximity of impacted third molars with the mandibular canal. *J Taibah Univ Med Sci* 2018; 13: 254-61.
9. Neves FS, Souza TC, Almeida SM, Haiter-Neto F, Freitas DQ, Bóscolo FN. Correlation of panoramic radiography and cone beam CT findings in the assessment of the relationship between impacted mandibular third molars and the mandibular canal. *Dentomaxillofac Radiol* 2012; 41: 553-7.
10. Tantanapornkul W, Okouchi K, Fujiwara Y, Yamashiro M, Maruoka Y, Ohbayashi N, et al. A comparative study of cone-beam computed tomography and conventional panoramic radiography in assessing the topographic relationship between the mandibular canal and impacted third molars. *Oral Surg Oral Med Oral Pathol Oral Radiol Endod* 2007; 103: 253-9.
11. Şekerci AE, Şişman Y. Comparison between panoramic radiography and cone-beam computed tomography findings for assessment of the relationship between impacted mandibular third molars and the mandibular canal. *Oral Radiol* 2014; 30: 170-8.
12. Shiratori K, Nakamori K, Ueda M, Sonoda T, Dehari H. Assessment of the shape of the inferior alveolar canal as a marker for increased risk of injury to the inferior alveolar nerve at third molar surgery: a prospective study. *J Oral Maxillofac Surg* 2013; 71: 2012-9.
13. Jung YH, Nah KS, Cho BH. Correlation of panoramic radiographs and cone beam computed tomography in the assessment of a superimposed relationship between the mandibular canal and impacted third molars. *Imaging Sci Dent* 2012; 42: 121-7.
14. Sedaghatfar M, August MA, Dodson TB. Panoramic radiographic findings as predictors of inferior alveolar nerve exposure following third molar extraction. *J Oral Maxillofac Surg* 2005; 63: 3-7.
15. Ghaemina H, Meijer GJ, Soehardi A, Borstlap WA, Mulder J, Bergé SJ. Position of the impacted third molar in relation to the mandibular canal. Diagnostic accuracy of cone beam computed tomography compared with panoramic radiography. *Int J Oral Maxillofac Surg* 2009; 38: 964-71.
16. Xu GZ, Yang C, Fan XD, Yu CQ, Cai XY, Wang Y, et al. Anatomic relationship between impacted third mandibular molar and the mandibular canal as the risk factor of inferior alveolar nerve injury. *Br J Oral Maxillofac Surg* 2013; 51: e215-9.