

Research Article



OPEN ACCESS

Received: Feb 26, 2019
Revised: Jun 13, 2019
Accepted: Jun 27, 2019

Shokouhinejad N, Razmi H, Farbod M,
Alikhasi M, Camilleri J

*Correspondence to

Josette Camilleri

School of Dentistry, Institute of Clinical
Sciences, College of Medical and Dental
Sciences, University of Birmingham, 5 Mill Pool
Way, Edgbaston, Birmingham B5 7EG, UK.
E-mail: J.Camilleri@bham.ac.uk

Copyright © 2019. The Korean Academy of
Conservative Dentistry

This is an Open Access article distributed
under the terms of the Creative Commons
Attribution Non-Commercial License (<https://creativecommons.org/licenses/by-nc/4.0/>)
which permits unrestricted non-commercial
use, distribution, and reproduction in any
medium, provided the original work is properly
cited.

Funding

This study was funded by Tehran University of
Medical Sciences (grant No. 35610).

Conflict of Interest

No potential conflict of interest relevant to this
article was reported.

Author Contributions

Conceptualization: Shokouhinejad N, Razmi
H, Alikhasi M, Farbod M, Camilleri J; Data
curation: Shokouhinejad N, Farbod M;
Formal analysis: Alikhasi M; Investigation:
Shokouhinejad N, Farbod M, Alikhasi M;
Methodology: Shokouhinejad N, Razmi H,
Alikhasi M; Supervision: Shokouhinejad N,

Coronal tooth discoloration induced by regenerative endodontic treatment using different scaffolds and intracanal coronal barriers: a 6-month *ex vivo* study

Noushin Shokouhinejad ,^{1,2} Hassan Razmi ,¹ Maryam Farbod ,¹
Marzieh Alikhasi ,^{2,3,4} Josette Camilleri ^{5*}

¹Department of Endodontics, School of Dentistry, Tehran University of Medical Sciences, Tehran, Iran
²Dental Research Center, Dentistry Research Institute, Tehran University of Medical Sciences, Tehran, Iran
³Dental Implant Research Center, Dentistry Research Institute, Tehran University of Medical Sciences, Tehran, Iran
⁴Department of Prosthodontics, School of Dentistry, Tehran University of Medical Sciences, Tehran, Iran
⁵School of Dentistry, Institute of Clinical Sciences, College of Medical and Dental Sciences, University of Birmingham, Edgbaston, Birmingham, UK

ABSTRACT

Objective: The aim of this study was to evaluate discoloration of teeth undergoing regenerative endodontic procedures (REPs) using blood clot or platelet-rich fibrin (PRF) as the scaffolds and different calcium silicate-based materials as the intracanal coronal barriers in an *ex vivo* model.

Materials and Methods: Forty-eight bovine incisors were prepared and disinfected using 1 mg/mL double antibiotic paste (DAP). The specimens were then randomly divided into 2 groups ($n = 24$) according to the scaffolds (blood or PRF). After placement of scaffolds each group was divided into 2 subgroups ($n = 12$) according to the intracanal coronal barriers (ProRoot MTA or Biodentine). The pulp chamber walls were sealed with dentin bonding agent before placement of DAP and before placement of scaffolds. The color changes (ΔE) were measured at different steps. The data were analyzed using 2-way analysis of variance.




Results: Coronal discoloration induced by DAP was not clinically perceptible ($\Delta E \leq 3.3$). Regarding the type of the scaffold, coronal discoloration was significantly higher in blood groups compared with PRF groups at the end of REP and after 1 month ($p < 0.05$). However, no significant difference was found between PRF and blood clot after 6 months ($p > 0.05$). Considering the type of intracanal coronal barrier, no significant difference existed between ProRoot MTA and Biodentine ($p > 0.05$).

Conclusions: With sealing the dentinal tubules of pulp chamber with a dentin bonding agent and application of DAP as an intracanal medicament, coronal color change of the teeth following the use of PRF and blood sealed with either ProRoot MTA or Biodentine was not different at 6-month follow-up.

Keywords: Calcium silicate; Mineral trioxide aggregate; Scaffold

Razmi H, Camilleri J; Writing - original draft:
Farbod M, Alikhasi M; Writing - review &
editing: Shokouhinejad N, Camilleri J.

ORCID iDs

Noushin Shokouhinejad 
<https://orcid.org/0000-0002-4307-438X>
Hassan Razmi 
<https://orcid.org/0000-0001-6124-105X>
Maryam Farbodc
<https://orcid.org/0000-0002-2388-262X>
Marzieh Alikhasi 
<https://orcid.org/0000-0002-2527-728X>
Josette Camilleric
<https://orcid.org/0000-0003-3556-6365>

INTRODUCTION

Endodontic management of immature permanent necrotic teeth is a challenging clinical procedure [1]. It has been shown that regenerative endodontic procedures (REPs) result in healing of apical periodontitis, continued radiographic root development, increasing fracture resistance and improved tooth survival in immature necrotic teeth [2,3]. However, it may contribute to tooth discoloration which is an unfavorable outcome [4,5].

Despite the increase in the number of cases reported in the literature and studies related to REPs, there is no established standardized protocol for REPs because of the lack of high levels of evidence for the outcome of regenerative treatment. REPs involve disinfection of the root canal system followed by introduction of a scaffold which is subsequently sealed with hydraulic silicate cements such as mineral trioxide aggregate (MTA) [6-8].

There are various types of intracanal medicaments used in REPs for disinfection of the root canal system. Triple antibiotic paste (TAP) consisting of ciprofloxacin, metronidazole, and minocycline is the most commonly used medicament in REPs [9]. However, tooth discoloration caused by TAP is well documented [4,10-13]. It has been shown that minocycline is the major cause of discoloration [4,13]. The efficacy of dentin bonding agent (DBA) for sealing the dentinal tubules of pulp chamber to decrease tooth discoloration caused by TAP has been supported by some articles [4,11,12], but it is not completely effective [12]. Therefore, it is suggested to use double antibiotic paste containing ciprofloxacin and metronidazole [10] or calcium hydroxide [7] instead of TAP, as well as to substitute minocycline with other antibiotics [10,14].

In several reports in REPs, evoked bleeding technique has been used to produce a blood clot scaffold [8], which promotes proliferation and differentiation of progenitor/stem cells [1]. Recent studies have used alternative scaffolds such as platelet-rich fibrin (PRF) and platelet-rich plasma (PRP) in regenerative endodontic treatment [15-17]. It has been stated that PRF is an ideal purely autologous scaffold for regeneration, which constitutes key growth factors for promoting the proliferation and differentiation of progenitor/stem cells [3,18].

After introduction of scaffolds to the root canal, it should be sealed coronally. It has been shown that MTA was the most popular intracanal barrier [8]. However, several studies have revealed the tooth discoloration potential of MTA, especially when it is in contact to blood [19,20]. To overcome tooth discoloration induced by MTA, it has been suggested to select other calcium silicate-based cements with lower potential of crown discoloration in teeth where there is an aesthetic concern [6].

To the best of our knowledge, there is no information regarding the discoloration ability of calcium silicate-based materials in contact to PRF as a scaffold in REPs. Therefore, the aim of this study was to evaluate coronal discoloration of teeth undergoing REPs using blood clot or PRF as the scaffolds, and ProRoot MTA (Dentsply Tulsa Dental Products, Tulsa, OK, USA) or Biodentine (Septodont, Saint Maur des Fosses, France) as the intracanal coronal barrier in an *ex vivo* model of regenerative endodontic procedure.

MATERIALS AND METHODS

Forty-eight bovine mandibular incisors from animals of nearly the same age and with almost similar crown and root size were selected. After disinfection by immersion in 0.5% chloramine T solution for 48 hours, teeth were stored in normal saline solution until use.

Preparation of specimens

The apical part of each specimen was resected perpendicular to its long axis to create a standardized root length of 15 mm below the labial cemento-enamel junction (CEJ). The apical 4 mm of the root canals was sealed with a composite resin material (Grandio; Voco GmbH, Cuxhaven, Germany) according to the manufacturer's instructions. Endodontic access cavities were then prepared and the root canals were shaped using #3 to #6 Gates Glidden drills, and irrigated with 20 mL 1.5% NaOCl followed by 20 mL 17% ethylenediaminetetraacetic acid (EDTA) each for 5 minutes [6,7]. Afterwards, the internal walls of the pulp chamber were sealed with a DBA according to the manufacturer's instructions as follows: after the inner surfaces of the pulp chamber was etched for 15 seconds with 35% phosphoric acid (Vococid; Voco GmbH), the dentin bonding agent (Solobond M; Voco GmbH) was applied to the etched surfaces and cured for 20 seconds.

Double antibiotic mixture was prepared by mixing equal proportions of ciprofloxacin and metronidazole (1:1) with sterile water to a final concentration of 1 mg/mL. Antibiotic mixture was inserted into the canal with a syringe to ensure that the solution remained below the labial CEJ. Access cavities were then filled with a temporary filling material (Zonalin; Kemdent, Swindon, UK). The specimens were incubated at 37°C in fully saturated humidity for 4 weeks. The access cavities were reopened and the root canals were irrigated with 20 mL 17% EDTA for 5 minutes and dried with paper points. For dealing with the possibility of damaged previous DBA layer during temporary filling material removal, DBA was reapplied on the access cavity walls in the same manner described for the first application of DBA. After that, it was attempted to perform the random sampling allocation stratified by the initial color of specimens or to one of these two groups as follows:

Group 1: the root canals were filled with human blood using a syringe up to 4 mm below the facial CEJ and it was allowed to form a blood clot for 15 minutes.

Group 2: the root canals were filled with PRF as a scaffold up to 4 mm below the facial CEJ. For the PRF preparation, human blood was collected in sterile tubes from the cubital vein. The tubes were centrifuged for 8 minutes with a speed of 1,300 rpm (DUO Quattro Centrifuge, Nice, France). Three layers were formed inside each test tube: a base layer containing erythrocytes, an intermediate layer of PRF, and a surface layer of platelet poor plasma. The PRF was separated from the other layers.

The whole fresh human blood used in this study was collected from healthy consented volunteers by a trained individual, and approved by a panel from the Tehran University of Medical Sciences Ethical Committee (Ethics code: IR.TUMS.VCR.REC. 1396.2977).

The specimens in each group were randomly divided into two experimental subgroups ($n = 12$) and labeled according to the applied intracanal coronal barrier. ProRoot MTA and Biodentine was prepared according to the manufacturers' instructions, and a 3-mm layer

of material was placed on the top of the scaffold. A wet cotton pellet with saline was placed over the endodontic materials and the cavity was temporarily sealed with Coltosol (Coltene, Altstätten, Switzerland). The specimens were incubated at 37°C in fully saturated humidity for 72 hours. Subsequently, after confirming the setting of coronal barriers, the access cavities were filled with composite resin material, A1 shade (Grandio; Voco GmbH). The shade of the composite was matched to the coronal tooth structure measured with a spectrophotometer (Vita Easyshad; VITA Zahnfabrik, Bad Säckingen, Germany).

The specimens were incubated at 37 °C in fully saturated humidity between the steps until the end of the study.

Tooth color assessment

For reproducible color assessment, a rectangular window measuring 3 × 3 mm was created at the cervical third of the crown using a needle-shaped diamond bur. A spectrophotometer (Vita Easyshad; VITA Zahnfabrik) was used to measure the L*, a*, and b* values. L* indicates the value of lightness-darkness, a* indicates greenness-redness, and b* indicates blueness-yellowness. The device was calibrated before use for each specimen. Color measurements were performed at the following 5 steps:

1. Initial: prior to application of antibiotic mixture as the baseline color
2. After DAP therapy: 4 weeks after placement of antibiotic mixture
3. After REP: after placement of scaffolds, intracanal coronal barriers and coronal restoration
4. At 1-month follow-up
5. At 6-month follow-up

The color measurements were taken 3 times inside the marked window. The mean value of 3 measurements was calculated at each time interval. The color change (ΔE) between the initial step and the other steps was calculated using the following formula:

$$\Delta E = \{(\Delta L)^2 + (\Delta a)^2 + (\Delta b)^2\}^{1/2}$$

Photographs were taken of the specimens at each treatment step using a digital camera for informal visual comparison.

Data were evaluated using SPSS software (PASW Statistics 18; SPSS Inc, Chicago, IL, USA). To evaluate the effect of the type of intracanal coronal barrier and scaffold on color change, the data were analyzed using 2-way analysis of variance. The level of statistically significant difference was set at $p < 0.05$.

RESULTS

The mean values for the color changes in each subgroup are shown in **Figures 1** and **2**. The findings showed that coronal discoloration after 4-week DAP therapy was under clinically perceptible threshold ($\Delta E \leq 3.3$). The results revealed that considering the type of the scaffold, crown discoloration was significantly higher in blood clot groups compared with PRF groups at the end of REP, and also 1 month later ($p < 0.05$). However, at the 6-month follow-up, no significant difference existed between PRF and blood clot groups ($p > 0.05$). Regarding the

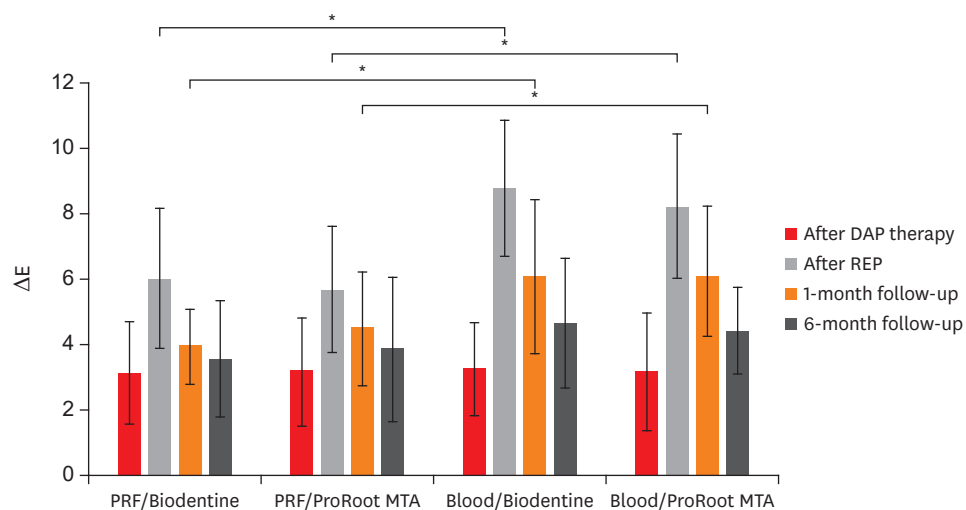


Figure 1. ΔE values (mean and standard deviation) of the experimental groups at the different steps. Significant difference between scaffolds (blood and platelet-rich fibrin [PRF]) was shown at the end of regenerative endodontic procedure (REP) and 1-month follow-up. DAP, double antibiotic paste; MTA, mineral trioxide aggregate. * $p < 0.05$.

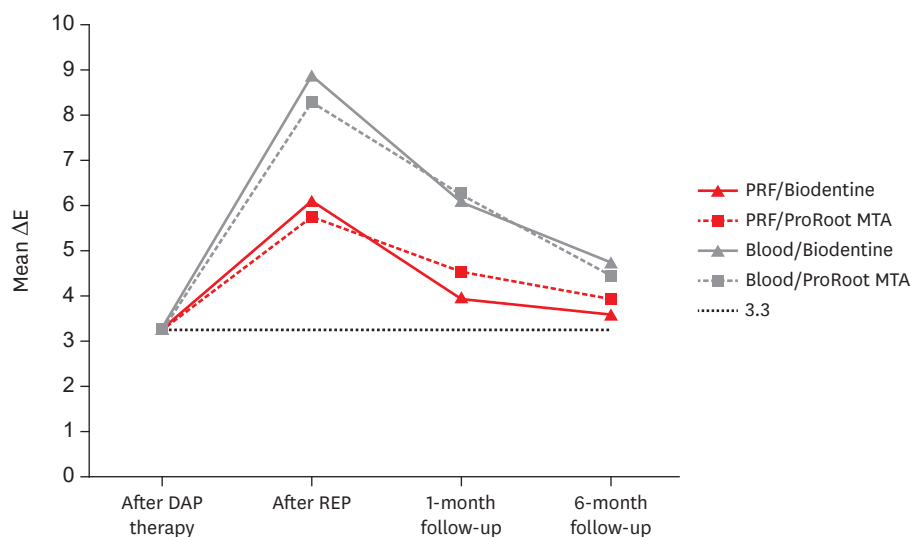


Figure 2. The color changes at each treatment step. The dotted line represents clinically perceptible discoloration of $\Delta E \geq 3.3$. DAP, double antibiotic paste; MTA, mineral trioxide aggregate; PRF, platelet-rich fibrin; REP, regenerative endodontic procedure.

type of intracanal coronal barrier, the results showed that the type of coronal barrier (ProRoot MTA or Biodentine) had no significant effect on coronal discoloration ($p > 0.05$).

Photos of a specimen from each group are shown in **Figure 3**.

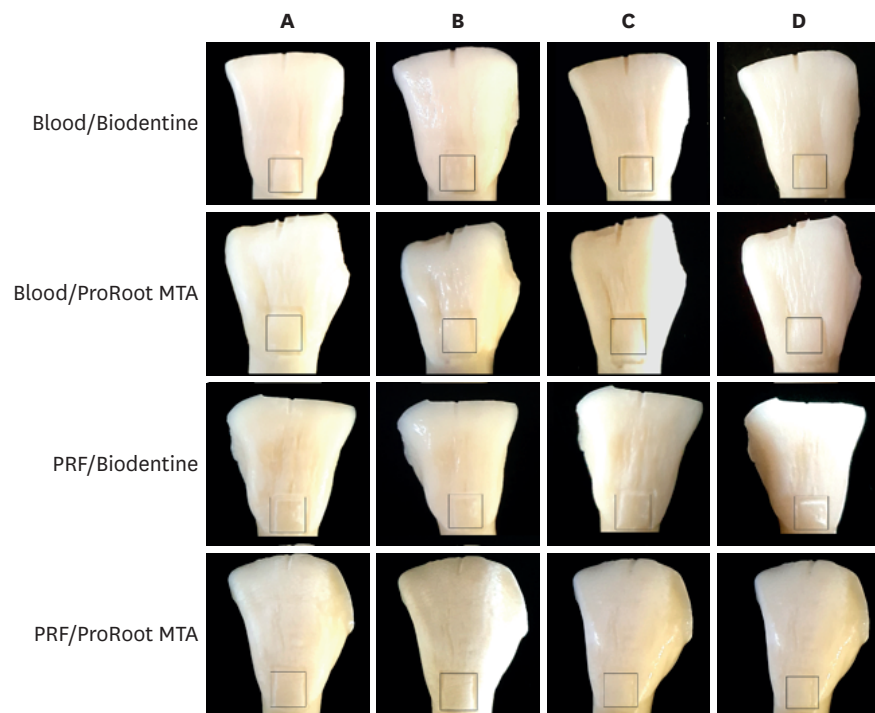


Figure 3. Photographs of teeth in each group. (A) At the end of 4-week antibiotic therapy. (B) At the end of endodontic regenerative procedure. (C) At 1-month follow-up. (D) At 6-month follow-up. The color changes were measured within the defined area. MTA, mineral trioxide aggregate; PRF, platelet-rich fibrin.

DISCUSSION

Crown discoloration is a commonly reported complication of the current clinical protocols of REPs. This is the first study to evaluate and compare the crown discoloration potential of two different scaffolds sealed by 2 different calcium silicate-based materials using an *ex vivo* model for regeneration. Studies have shown many advantages in using bovine teeth instead of human ones [10,21,22], including a sufficient flat surface in large numbers without any restorations, caries [21], and no concern about ethical issues [23]. However, the number of tubules is higher in bovine specimens compared with human dentin [23], which might influence the penetration of the materials in the dentin.

In the study, DAP was used as intracanal medicament. The most common medicament used in REPs is TAP containing minocycline and it has been applied as intracanal medicament in 80% of the clinical articles [9]. However, it poses disadvantage of severe tooth discoloration even in low concentrations [4,10,12]. It has been shown that coronal discoloration caused by TAP could not be prevented even with sealing the dentinal tubules of pulp chamber walls [12]. Although the European Society of Endodontology (ESE) position statement advocates a nondiscoloring calcium hydroxide as an intracanal medicament [7], antibiotic mixtures are still recommended by the American Association of Endodontists [6]. Double antibiotic paste has been recommended to prevent discoloration caused by minocycline in TAP [6], and was successfully used in endodontic regeneration [24,25]. The precise preparation method of TAP and DAP is not mentioned in most of the studies and case reports. It has been shown that residual antibacterial effect of TAP or DAP at a concentration of 1 mg/mL was comparable with those concentrations currently used in REPs (1,000 mg/mL) [26]. Therefore, 1 mg/mL

DAP was used in this study which may also have less cytotoxicity in clinical conditions due to lower concentration [27].

A ΔE value greater than 3.3 is considered to be perceivable color change [28]. In this study, coronal discoloration after a 4-week antibiotic therapy period was less than the clinically perceptible value ($\Delta E \leq 3.3$). This finding is in accordance with Akcay *et al.* [10] which showed that using DAP for 3 weeks did not cause any noticeable coronal discoloration unlike TAP.

This study revealed that application of PRF instead of blood clot as a scaffold resulted in significant decreased crown discoloration at the end of REPs and 1 month later. Several studies have shown tooth discoloration potential of blood [20,29], possibly due to the penetration of erythrocytes into the tooth structure [20], and accumulation of hemoglobin and hemein molecules in dentinal tubules after hemolysis of erythrocytes [30]. In current study, greater discoloration in the blood groups does not seem to be related to the penetration of erythrocytes into the coronal tooth structure as the dental walls of the pulp chamber had been sealed using DBA. Furthermore, it was attempted to deliver blood into the canals without contamination of the pulp chamber. However, the proximity of blood contaminated cervical root dentin to the cervical third of the crown where assessment of discoloration was evaluated can be a reason for this finding. Moreover, absorption of blood into the fresh unset calcium silicate-based materials which were located in the cervical area of the root might be another reason for more discoloration in blood groups. Ferrous (Fe^{2+}) ion in the center of heme group of blood which possesses a red color becomes ferric (Fe^{3+}) which has a dark brown color due to a natural redox reaction that may result in discoloration of materials [20, 31]. It has been shown that blood contamination exacerbated discoloration induced by calcium silicate-based materials containing bismuth oxide or other radiopacifiers [19,29,31]. Therefore, the higher tooth discoloration in blood groups at the end of regenerative endodontic procedure and 1-m later could be attributed to color changes of intracanal coronal barriers exposed to blood. The lower discoloration induced by PRF at mentioned steps might be associated with the lack of erythrocytes in platelet derivatives.

It is suggested to use alternatives to ProRoot MTA such as Biodentine to seal the scaffolds where there is an esthetic concern [6]. In a systematic review, Możyńska *et al.* [32] reported that ProRoot MTA showed a strong potential for staining compared to Biodentine. However, the results of the present study showed no significant difference between discoloration potential of Biodentine and ProRoot MTA. This result is in accordance with the findings of our previous study [12] which did not reveal significant difference between tooth color change induced by ProRoot MTA and Biodentine placed over the blood clot when the pulp chamber walls were sealed with DBA. However, in studies that showed more coronal discoloration associated with ProRoot MTA, MTA-dentin interface was not sealed [28,33]. The amino acids in dentin collagen seem to destabilize bismuth oxide molecule in MTA, resulting in eventual change in color to black [34]. Tooth discoloration has been shown to be caused by movement of discolored bismuth from the material to the tooth structure by ion exchange [35]. Thus, less color change seen following the use of ProRoot MTA in the present study might be related to the sealing of the pulp chamber dentinal walls with DBA, leading to prevention of bismuth migration to the tooth structure.

Despite the more significant crown discoloration found in the blood groups at the end of regenerative endodontic procedure and 1-month follow-up, no significant difference existed at 6-month follow-up among blood and PRF groups. At 6-month follow-up, regenerative

protocols used in the current study resulted in color change values which were slightly more than the clinically perceptible ones.

In the present study, color change was not incremental, and reverted from the end of REP to 6-month follow-up. Furthermore, reduction of color changes was more evident in blood groups compared with PRF groups. This finding might be related to the alteration of erythrocytes via physiological degradation over time, thus resulting in the change of optical properties of materials and dental tissues [20]. This finding should be further investigated.

Although there is little information on color stability of calcium silicate-based materials exposed to PRF, the protocol used in this study, including covering the dentinal tubules of pulp chamber with DBA and application of DAP as the intracanal medicament seems promising to decrease the coronal color change in teeth undergoing REPs even after introduction of blood into the root canals and sealing the scaffolds using bismuth oxide containing calcium silicate based materials.

It is worth to mention that in this study, both scaffold materials were not in contact to neither bone fluids nor blood from the normal human body stream. Further clinical studies are needed to evaluate the outcome of this protocol in REPs.

CONCLUSIONS

Under the conditions of this study, the use of a low concentration of DAP (1 mg/mL) following covering dentinal walls of the pulp chamber led to slight coronal color change which was less than the clinically noticeable value. No significant difference was found between the crown color change following the application of ProRoot MTA and Biodentine placed below the labial CEJ for sealing the scaffolds at any time intervals.

ACKNOWLEDGEMENTS

The authors wish to thank Dr. MJ. Kharrazifard for his assistance in statistical analysis. The authors deny any conflicts of interest related to this study.

REFERENCES

1. Nosrat A, Homayounfar N, Oloomi K. Drawbacks and unfavorable outcomes of regenerative endodontic treatments of necrotic immature teeth: a literature review and report of a case. *J Endod* 2012;38:1428-1434. [PUBMED](#) | [CROSSREF](#)
2. Hargreaves KM, Diogenes A, Teixeira FB. Treatment options: biological basis of regenerative endodontic procedures. *J Endod* 2013;39:S30-S43. [PUBMED](#) | [CROSSREF](#)
3. Hargreaves KM, Giesler T, Henry M, Wang Y. Regeneration potential of the young permanent tooth: what does the future hold? *J Endod* 2008;34:S51-S56. [PUBMED](#) | [CROSSREF](#)
4. Kim JH, Kim Y, Shin SJ, Park JW, Jung IY. Tooth discoloration of immature permanent incisor associated with triple antibiotic therapy: a case report. *J Endod* 2010;36:1086-1091. [PUBMED](#) | [CROSSREF](#)

5. Park HB, Lee BN, Hwang YC, Hwang IN, Oh WM, Chang HS. Treatment of non-vital immature teeth with amoxicillin-containing triple antibiotic paste resulting in apexification. *Restor Dent Endod* 2015;40:322-327.
[PUBMED](#) | [CROSSREF](#)
6. American Association of Endodontists. AAE clinical considerations for a regenerative procedure. Revised 6-8-16 [Internet]. Chicago (IL): American Association of Endodontists; 2017 [cited 2017 Jul 30]. Available from: <https://www.aae.org/specialty/wp-content/uploads/sites/2/2017/06/currentregenerative-endodonticconsiderations.pdf>.
7. Galler KM, Krastl G, Simon S, Van Gorp G, Meschi N, Vahedi B, Lambrechts P. European Society of Endodontology position statement: revitalization procedures. *Int Endod J* 2016;49:717-723.
[PUBMED](#) | [CROSSREF](#)
8. Lee BN, Moon JW, Chang HS, Hwang IN, Oh WM, Hwang YC. A review of the regenerative endodontic treatment procedure. *Restor Dent Endod* 2015;40:179-187.
[PUBMED](#) | [CROSSREF](#)
9. Kontakiotis EG, Filippatos CG, Tzanetakakis GN, Agrafioti A. Regenerative endodontic therapy: a data analysis of clinical protocols. *J Endod* 2015;41:146-154.
[PUBMED](#) | [CROSSREF](#)
10. Akcay M, Arslan H, Yasa B, Kavruk F, Yasa E. Spectrophotometric analysis of crown discoloration induced by various antibiotic pastes used in revascularization. *J Endod* 2014;40:845-848.
[PUBMED](#) | [CROSSREF](#)
11. Reynolds K, Johnson JD, Cohenca N. Pulp revascularization of necrotic bilateral bicuspid using a modified novel technique to eliminate potential coronal discoloration: a case report. *Int Endod J* 2009;42:84-92.
[PUBMED](#) | [CROSSREF](#)
12. Shokouhinejad N, Khoshkhounejad M, Alikhasi M, Bagheri P, Camilleri J. Prevention of coronal discoloration induced by regenerative endodontic treatment in an *ex vivo* model. *Clin Oral Investig* 2018;22:1725-1731.
[PUBMED](#) | [CROSSREF](#)
13. Porter ML, Münchow EA, Albuquerque MT, Spolnik KJ, Hara AT, Bottino MC. Effects of novel 3-dimensional antibiotic-containing electrospun scaffolds on dentin discoloration. *J Endod* 2016;42:106-112.
[PUBMED](#) | [CROSSREF](#)
14. Kahler B, Mistry S, Moule A, Ringsmuth AK, Case P, Thomson A, Holcombe T. Revascularization outcomes: a prospective analysis of 16 consecutive cases. *J Endod* 2014;40:333-338.
[PUBMED](#) | [CROSSREF](#)
15. Torabinejad M, Faras H. A clinical and histological report of a tooth with an open apex treated with regenerative endodontics using platelet-rich plasma. *J Endod* 2012;38:864-868.
[PUBMED](#) | [CROSSREF](#)
16. Güven Polat G, Yıldırım C, Akgün OM, Altun C, Dinçer D, Ozkan CK. The use of platelet rich plasma in the treatment of immature tooth with periapical lesion: a case report. *Restor Dent Endod* 2014;39:230-234.
[PUBMED](#) | [CROSSREF](#)
17. Shivashankar VY, Johns DA, Maroli RK, Sekar M, Chandrasekaran R, Karthikeyan S, Renganathan SK. Comparison of the effect of PRP, PRF and induced bleeding in the revascularization of teeth with necrotic pulp and open apex: a triple blind randomized clinical trial. *J Clin Diagn Res* 2017;11:ZC34-ZC39.
[PUBMED](#) | [CROSSREF](#)
18. Huang FM, Yang SF, Zhao JH, Chang YC. Platelet-rich fibrin increases proliferation and differentiation of human dental pulp cells. *J Endod* 2010;36:1628-1632.
[PUBMED](#) | [CROSSREF](#)
19. Shokouhinejad N, Nekoofar MH, Pirmoazen S, Shamshiri AR, Dummer PM. Evaluation and comparison of occurrence of tooth discoloration after the application of various calcium silicate-based cements: an *ex vivo* study. *J Endod* 2016;42:140-144.
[PUBMED](#) | [CROSSREF](#)
20. Felman D, Parashos P. Coronal tooth discoloration and white mineral trioxide aggregate. *J Endod* 2013;39:484-487.
[PUBMED](#) | [CROSSREF](#)
21. Schilke R, Lisson JA, Bauss O, Geurtsen W. Comparison of the number and diameter of dentinal tubules in human and bovine dentine by scanning electron microscopic investigation. *Arch Oral Biol* 2000;45:355-361.
[PUBMED](#) | [CROSSREF](#)
22. Kato MT, Hannas AR, Leite AL, Bolanho A, Zarella BL, Santos J, Carrilho M, Tjäderhane L, Buzalaf MA. Activity of matrix metalloproteinases in bovine versus human dentine. *Caries Res* 2011;45:429-434.
[PUBMED](#) | [CROSSREF](#)

23. Camargo MA, Marques MM, de Cara AA. Morphological analysis of human and bovine dentine by scanning electron microscope investigation. *Arch Oral Biol* 2008;53:105-108.
[PUBMED](#) | [CROSSREF](#)
24. Fahmy SH, Hassanien EE, Nagy MM, El Batouty KM, Mekhemar M, Fawzy El Sayed K, Hassanein EH, Wiltfang J, Dörfer C. Investigation of the regenerative potential of necrotic mature teeth following different revascularisation protocols. *Aust Endod J* 2017;43:73-82.
[PUBMED](#) | [CROSSREF](#)
25. Iwaya SI, Ikawa M, Kubota M. Revascularization of an immature permanent tooth with apical periodontitis and sinus tract. *Dent Traumatol* 2001;17:185-187.
[PUBMED](#) | [CROSSREF](#)
26. Sabrah AH, Yassen GH, Spolnik KJ, Hara AT, Platt JA, Gregory RL. Evaluation of residual antibacterial effect of human radicular dentin treated with triple and double antibiotic pastes. *J Endod* 2015;41:1081-1084.
[PUBMED](#) | [CROSSREF](#)
27. Ruparel NB, Teixeira FB, Ferraz CC, Diogenes A. Direct effect of intracanal medicaments on survival of stem cells of the apical papilla. *J Endod* 2012;38:1372-1375.
[PUBMED](#) | [CROSSREF](#)
28. Marconyak LJ Jr, Kirkpatrick TC, Roberts HW, Roberts MD, Aparicio A, Himel VT, Sabey KA. A comparison of coronal tooth discoloration elicited by various endodontic reparative materials. *J Endod* 2016;42:470-473.
[PUBMED](#) | [CROSSREF](#)
29. Lenherr P, Allgayer N, Weiger R, Filippi A, Attin T, Krastl G. Tooth discoloration induced by endodontic materials: a laboratory study. *Int Endod J* 2012;45:942-949.
[PUBMED](#) | [CROSSREF](#)
30. Marin PD, Heithersay GS, Bridges TE. A quantitative comparison of traditional and non-peroxide bleaching agents. *Endod Dent Traumatol* 1998;14:64-67.
[PUBMED](#) | [CROSSREF](#)
31. Guimarães BM, Tartari T, Marciano MA, Vivan RR, Mondeli RF, Camilleri J, Duarte MA. Color stability, radiopacity, and chemical characteristics of white mineral trioxide aggregate associated with 2 different vehicles in contact with blood. *J Endod* 2015;41:947-952.
[PUBMED](#) | [CROSSREF](#)
32. Możyńska J, Metlerski M, Lipski M, Nowicka A. Tooth discoloration induced by different calcium silicate-based cements: a systematic review of *in vitro* studies. *J Endod* 2017;43:1593-1601.
[PUBMED](#) | [CROSSREF](#)
33. Vallés M, Roig M, Duran-Sindreu F, Martínez S, Mercadé M. Color stability of teeth restored with biodentine: a 6-month *in vitro* study. *J Endod* 2015;41:1157-1160.
[PUBMED](#) | [CROSSREF](#)
34. Marciano MA, Costa RM, Camilleri J, Mondelli RF, Guimarães BM, Duarte MA. Assessment of color stability of white mineral trioxide aggregate angelus and bismuth oxide in contact with tooth structure. *J Endod* 2014;40:1235-1240.
[PUBMED](#) | [CROSSREF](#)
35. Marciano MA, Duarte MA, Camilleri J. Dental discoloration caused by bismuth oxide in MTA in the presence of sodium hypochlorite. *Clin Oral Investig* 2015;19:2201-2209.
[PUBMED](#) | [CROSSREF](#)