

Bone Marrow Toxicity Caused by Estrogen Toxicity in a Yorkshire Terrier with Leydig Cell Tumor

Yoon-Hee Kim, Kyu-Ryeon Ko*, Mi-Young No**, Jae-Hoon Kim* and Ul-Soo Choi¹

College of Veterinary Medicine, Chonbuk National University, Iksan-si 54596, Korea

**College of Veterinary Medicine, Jeju National University, Jeju-si, Jeju Special Self-Governing Province 63243, Korea*

***Deokso Animal Hospital, Namyangju-si, Gyeonggi-do 12215, Korea*

(Received: February 20, 2019 / Accepted: March 18, 2019)

Abstract : A 15-year-old intact Yorkshire terrier was presented with anorexia, lethargy, and a pale mucous membrane. A physical examination one year ago revealed right testis mass and subcutaneous petechia. Blood work revealed severe thrombocytopenia and mild anemia, and no abnormalities were found in serum chemistry or ultrasonography. The preoperative serum estrogen concentration was moderately elevated. The enlarged testis was surgically removed. A well-encapsulated mass composed of polyhedral or round with abundant eosinophilic cytoplasm containing fine granular or vacuolation were found in a histological examination of the removed tissue. The nuclei of tumor cells were round, and mitotic figures were low but neoplastic cells showed a mild invasive tendency to adjacent tissues with contained neoplastic cell emboli in one lymphatic lumen. A diagnosis of a malignant Leydig cell tumor was made. The patient recovered from surgery uneventfully, but his condition worsened despite repeated transfusions and supportive therapy, and he was euthanized according to the owner's decision. Leydig cell tumor should be included in estrogen toxicity associated with testicular mass.

Key words : Leydig cell tumor, thrombocytopenia, anemia, dog.

Introduction

Testicular tumors in dogs are common, and three types of tumors are Sertoli cell tumors, seminomas, and Leydig cells tumor (4). Other testicular tumors included hemangiosarcoma, granulosa cell tumor, teratoma, sarcoma, embryonal carcinoma, gonadoblastoma, lymphoma, and rete testis mucinous adenocarcinoma (10). The presence of cryptorchidism accounts for the fact that testicular tumors occur more frequently in the right testicle. The right testicle arises more cranially than the left one and has a longer distance to move in order to reach the scrotum (9). Risk factors are age, breed, and exposure to environmental carcinogens. The prevalence of testicular tumors in dogs seems to increase from the age of 10 years on, but a report was published asserting that age is of no relevance in the development of testicular tumors (1). Breeds frequently documented with this health issue include boxer, German shepherd, Afghan hound, Weimaraner, Shetland sheepdog (1). Metastasis occurs in is less than 15% of cases and is found primarily in peripheral lymph nodes, liver, lung parenchyma, kidney, spleen, adrenal gland, pancreas, skin, eye, and central nerve system.

Hyperestrogenism may occasionally be caused by Sertoli cell tumors in dogs with cryptorchidism, but it is rarely caused by seminoma (5) or Leydig cell tumor (13). Signs of feminization by hyperestrogenism include bilaterally sym-

metric alopecia, hyperpigmentation, pendulous prepuce, gynecomastia, galactorrhea, atrophic penis, and squamous metaplasia of the prostate (13). In dogs with signs of feminization, the diagnosis of hyperestrogenism secondary to primary testicular tumors may be aided by the measurement of plasma estradiol-17 beta or androgen/estrogen ratio (7).

Here we describe the clinical and histological features of an uncommon Leydig cell tumor with pancytopenia induced by hyperestrogenism in a 15-year-old male Yorkshire terrier dog.

Case

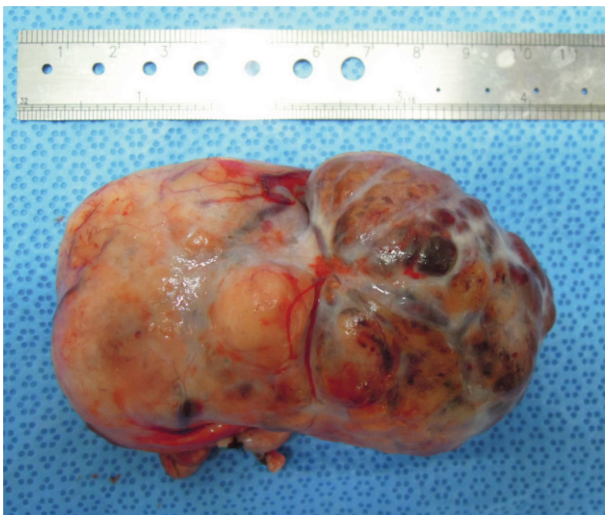
A 15-year-old intact male Yorkshire terrier was presented with anorexia and lethargy. A year earlier, an examination of the patient had revealed right testis hyperplasia. When the dog was admitted to a local hospital, his mucous membrane was very pale, and subcutaneous petechia was noted all throughout the body. Serum chemistry results were all within reference limits. CBC results revealed severe anemia (HCT 12.6%; reference range 37.0-55.0%), hemoglobin concentration (4.3 g/dL; reference range 12.0-18.0 g/dL), and thrombocytopenia (7000/ μ L; reference range $175-500 \times 10^3/\mu$ L) (Table 1). Neither radiology nor ultrasonography revealed any evidence of distant metastasis. The patient was immediately put on IV fluid therapy and antibiotics. In addition, whole blood transfusion was performed for the improvement of anemia and thrombocytopenia. Before surgery, serum estrogen concentration was moderately elevated (66 pg/ml; reference range 0-10 pg/ml) (Neodin Vetlab, Seoul, Korea). The testic-

¹Corresponding author.
E-mail : uschoi@jbnu.ac.kr

Table 1. Results of complete blood cell count and serum chemistry on 1st visit and 2nd visit

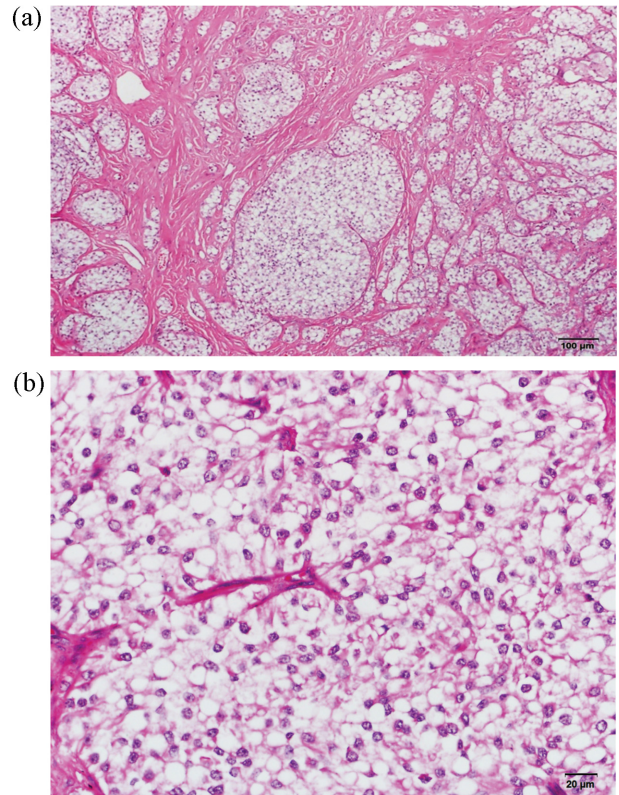
	1st visit	Reference interval
HCT (PCV)	12.6	37.0-55.0%
HGB	4.3	12.0-18.0 g/dL
MCHC	34.1	30.0-36.9 g/dL
WBC	9.1	$6.0-16.9 \times 10^3$
GRANS	8.1	$3.3-12.0 \times 10^3$
%GRANS	89	
L/M	1.0	$1.1-6.3 \times 10^3$
% L/M	11	
PLT	7	$175-400 \times 10^3$
RETICS	1.4	

	1st visit	Reference Interval
ALKP	56	23-212 U/L
TBIL	0.1	0.0-0.9 mg/dl
BUN	26	7-27 mg/dl
TP	6.7	5.2-8.2 g/dl
GLOB	4.1	2.5-4.5 g/dl
Ca	9.3	7.9-12.0 mg/dl
PHOS	3.8	2.5-6.8 mg/dl
ALT	42	10-100 U/L
CHOL	252	110-320 mg/dl
CREA	1.1	0.5-1.8 mg/dl
ALB	2.7	2.2-3.9 g/dl
GLU	102	70-143 mg/dl
AMYL	936	500-1500 U/L

**Fig 1.** Gross photograph of the surgically removed enlarged right testicle.

ular mass was completely removed surgically (Fig 1). The resected mass was fixed in 10% neutral buffered formalin and submitted to Veterinary histopathological laboratory at Jeju University.

Microscopic examination of the tissue revealed a neoplastic mass that was well-encapsulated in dense connective tissue (Fig 2). Most normal seminiferous tubules were replaced by neoplastic mass. Tumor cells were distributed in a solid

**Fig 2.** Right testicular mass. (a) Encapsulated dense connective tissue with mixed solid and cystic-vascular (acinar) pattern. H&E for malignant Leydig cell tumor ($\times 100$). (b) Polyhedral or round with abundant eosinophilic cytoplasm containing fine granular or vacuolation (small to large). H&E for malignant Leydig cell tumor ($\times 400$).

pattern, separated by fibro-vascular structures or a small acinar pattern. In the center of this pattern were large amounts of RBC, fibrin, and eosinophilic protein fluids. The tumor cells were polyhedral or round with abundant eosinophilic cytoplasm contain fine granular or vacuolation (small to large). The nucleus of the tumor cell was dark and round, and mitotic figures were low but these neoplastic cells showed a mild invasive tendency to adjacent tissues, with one lymphatic contained neoplastic cell emboli in its lumen. These characteristic histopathologic features were consistent with the presence of a malignant Leydig cell tumor.

This dog's clinical signs included anemia and thrombocytopenia. These improved and then maintained status for the next two weeks. But on a second visit, fifteen days after the surgery, severe thrombocytopenia (8×10^3 ; reference range $175-500 \times 10^3/\mu\text{L}$) and leukopenia (4.5×10^3 ; reference range $6.0-16.9 \times 10^3/\mu\text{L}$) were noted. The patient was transfused with whole blood again and discharged. When we checked the CBC one week later, the anemia was still severe (HCT 32.6%; reference range 37.0-55.0%), as were hemoglobin (11.6 g/dL; reference range 12.0-18.0 g/dL), leukopenia (WBC $3.8 \times 10^3/\mu\text{L}$; reference range $6.0-16.9 \times 10^3/\mu\text{L}$), and thrombocytopenia (14×10^3 , reference range $175-500 \times 10^3/\mu\text{L}$). Although estrogen concentration fell to within the normal range (5 pg/ml; reference range 0-10 pg/ml) after surgery, this patient's pancytopenia did not improved, despite repeated

blood transfusions and the institution of antibiotics and other supportive therapy. The dog was euthanized 30 days after surgery at the owner's request.

Discussion

Hyperestrogenism in testicular tumor patients can cause bone marrow suppression. This was reported in eight dogs with Sertoli cell tumors (12), a German shepherd with an interstitial cell tumor in 1992 (13), and a cryptochidic Yorkshire terrier with seminoma. In this case, a Leydig cell tumor that arose from a non-cryptochidic testis in the small breed dog, induced thrombocytopenia, leukocytopenia, and anemia.

Leydig cells release a class of hormones called androgens (19-carbon steroids). When stimulated by the pituitary hormone luteinizing hormone (LH), they secrete testosterone, androstenedione, and dehydroepiandrosterone (DHEA). Also, prolactin (PRL) increases the response of Leydig cells to LH by increasing the number of LH receptors expressed on Leydig cells. In male dogs, estrogen is synthesized in the form of estradiol from testosterone by aromatase in testicular Leydig cells. On the other hand, Sertoli cells have been known to be involved in the synthesis of estrogen at developmental stages. The entire Leydig cell tumor did not cause feminization and bone marrow suppression by hyperestrogenism, and it was known that the testosterone/estradiol ratio might be more associated with clinical signs (7). Both inhibin-like immunoreactivity and the expression of IGF-R and IGFBP4 are prominent in patients with Leydig cell tumors (11), so it is estimated that changes of gene expression affect the degree of tumor pathogenesis and clinical symptoms (11).

Bone marrow suppression and subsequent leukopenia, non-regenerative anemia, and thrombocytopenia are the primary side-effects of hyperestrogenism. Pancytopenia may persist despite removal of the estrogen source (8). Sensitivity to the myelotoxic effects of estrogen is dependent on the age and physical condition of the animal and on the source of the estrogen (6,8).

Treatments for estrogen toxicity include whole blood or platelet-rich transfusions, broad-spectrum antibiotics, steroids, and bone marrow stimulants such as testosterone/nandrolon. Lithium carbonate has been known to stimulate neutrophil production, and this has been used with success for canine cyclic hematopoiesis (3). Lithium stimulates the division of pluripotential stem cells by an unknown mechanism. The use of lithium carbonate at 11 mg/kg orally twice daily for 6 weeks has been shown to reverse stilboestrol-induced bone marrow suppression (2). In the case reported here, these drugs were unavailable at the time of the diagnosis, and only symptomatic therapy was instituted. Despite repeated transfusions, the condition of the patient worsened.

Orchitectomy is the treatment of choice for a dog with a testicular tumor without metastasis, and it is curative. But bone marrow hypoplasia secondary to hyperestrogenism might be induced a guarded prognosis associated with either secondary infection or bleeding problem. According to Sherding RG, two dogs recovered after castration, but five other similarly treated dogs died of hemopoietic disorder. One dog was euthanized (12). Kim reported that a dog with semi-

noma survived after orchitectomy without complications (5). The exposure to prolonged high estrogen concentrations caused irreversible damage to the bone marrow. The dog with the Leydig cell tumor in this report showed sustained thrombocytopenia, even after repeated transfusions and supportive therapy, and he was euthanized a month later.

In conclusion, this report documented a rare Leydig cell tumor causing hyperestrogenism in a dog with intractable clinical signs. Leydig cell tumor should be included in a testicular mass in a dog with hyperestrogenism.

Conflict of Interest

We have no conflict of interest related to this work.

References

- Grieco V, Riccardi E, Greppi GF, Teruzzi F, Iermanò V, Finazzi M. Canine testicular tumours: a study on 232 dogs. *J Comp Path* 2008; 138: 86-89.
- Hall EJ. Use of lithium for treatment of estrogen-induced bone marrow hypoplasia in a dog. *J Am Vet Med Assoc* 1992; 200: 814-816.
- Hammond WP, Dale DC. Lithium therapy of canine cyclic hematopoiesis. *Blood* 1981; 55: 26-28.
- Kennedy PC, Cullen JM, Edwards JF, Goldschmidt MH, Larsen S, Munson L, Nielsen S. Histological classifications of tumors of the genital system of domestic animals. In: World Health Organization International Histological Classification of Tumors of Domestic Animals, Vol. IV, 1998.
- Kim O, Kim KS. Seminoma with hyperestrogenemia in a Yorkshire terrier. *J Vet Med Sci* 2005; 67: 121-123.
- Maddux JM, Shaw WE. Possible beneficial effect of lithium therapy in a case of estrogen induced bone marrow hypoplasia in a dog: A case report. *J of Am Ani Hosp Assoc* 1983; 19: 242-245.
- Mischke R, Meurer D, Hoppen HO, Ueberschär S, Hewicker-Trautwein M. Blood plasma concentrations of oestradiol-17beta, testosterone and testosterone/oestradiol ratio in dogs with neoplastic and degenerative testicular diseases. *Res Vet Sci* 2002; 73: 267-272.
- Morgan RV. Blood dyscrasias associated with testicular tumors in the dog. *J of Am Ani Hosp Assoc* 1982; 18: 970-975.
- Nielson SW, Kennedy PC. In: Tumors in domestic Animals (Moulton, J.E., ed.), University of California Press, Berkeley 1990; 479-517.
- Patnaik AK, Mostofi FK. A clinicopathologic, histologic, and immunohistochemical study of mixed germ cell-stromal tumors for the testis in 16 dogs. *Vet Pathol* 1993; 30: 287-295.
- Peters MA, Mol JA, van Wolferen ME, Oosterlaken-Dijksterhuis MA, Teerds KJ, van Sluijs FJ. Expression of the insulin-like growth factor (IGF) system and steroidogenic enzymes in canine testis tumors. *Reprod Biol Endocrinol* 2003; 1: 22.
- Sherding RG, Wilson GP 3rd, Kociba GJ. Bone marrow hypoplasia in eight dogs with Sertoli cell tumor. *J Am Vet Med Assoc*. 1981; 178: 497-501.
- Suess RP Jr, Barr SC, Sacre BJ, French TW. Bone marrow hypoplasia in a feminized dog with an interstitial cell tumor. *J Am Vet Med Assoc* 1992; 200: 1346-1348.