

# Late Reoperation Following Ligation of the Left Main Coronary Artery in a Patient with Infective Endocarditis

Dong Woog Yoon, M.D., Sang On Lee, M.D., Pyo Won Park, M.D., Ph.D.

*Department of Thoracic and Cardiovascular Surgery, Samsung Medical Center,  
Sungkyunkwan University School of Medicine, Seoul, Korea*

We report the case of a female patient who underwent late reoperation following endocarditis surgery. The patient first underwent surgery at 22 years of age for endocarditis with aortic and tricuspid insufficiency. She underwent aortic root replacement with a homograft and tricuspid valve replacement with a tissue valve. Coronary artery bypass using the internal thoracic artery and ligation of the left main coronary artery were performed. Ten years later, failure of the homograft and the tricuspid valve developed. In the second operation, the patient underwent a successful Bentall operation and tricuspid valve replacement with a mechanical valve under deep hypothermia and retrograde cold cardioplegia without drainage.

*Key words:* 1. Endocarditis  
2. Coronary artery bypass  
3. Reoperation

## Case report

A 22-year-old woman was admitted to Samsung Medical Center with fever and dyspnea with New York Heart Association (NYHA) class IV heart failure in 2002. She had a history of acupuncture in her right ankle 10 days prior to admission. A transesophageal echocardiogram demonstrated oscillatory echogenic materials (0.8 cm and 0.7 cm) on the patient's aortic and tricuspid valve, with severe aortic and tricuspid insufficiency. The echocardiogram also showed an aortic annular abscess and a perimembranous-type ventricular septal defect (VSD) measuring 0.5 cm. A neurologic examination of the patient yielded normal results, but computed tomography demonstrated focal ischemic lesions in the left basal ganglia, kidney, and spleen, which were compatible with established infarcts. Blood cultures were pos-

itive for viridans streptococci, and urgent surgery was recommended to avoid further circulative embolism and worsening of the patient's heart failure.

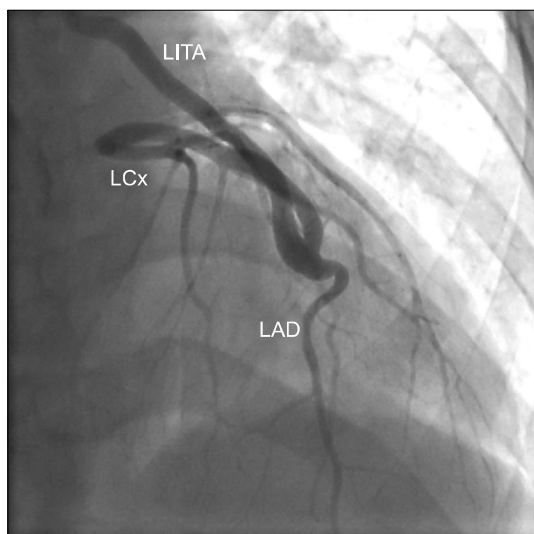
The operation was performed using standard cardiopulmonary bypass (CPB) with cold blood cardioplegic solution. Friable vegetations were found on all aortic cusps, and an abscess was also found in the posterior aortic annulus. Destruction of the left coronary ostium (LCO) with damaged endothelium precluded coronary reimplantation. Therefore, external ligation of the left main coronary artery and a coronary artery bypass graft using the left internal thoracic artery (LITA) to the proximal left anterior descending (LAD) coronary artery were performed. The right coronary button was anastomosed in a routine fashion. The patient also underwent VSD closure with double-layered bovine pericardium, aortic root replacement with a 22-mm cryopreserved aortic

*Received: August 16, 2018, Revised: November 8, 2018, Accepted: November 8, 2018, Published online: April 5, 2019*

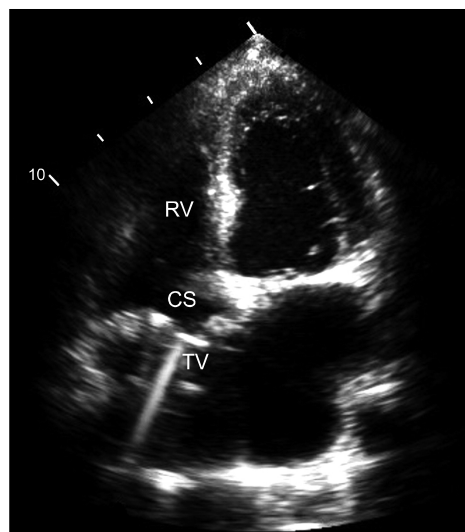
*Corresponding author: Pyo Won Park, Department of Thoracic and Cardiovascular Surgery, Samsung Medical Center, Sungkyunkwan University School of Medicine, 81 Irwon-ro, Gangnam-gu, Seoul 06351, Korea  
(Tel) 82-2-3410-3481 (Fax) 82-2-3410-0089 (E-mail) pwpark@skku.edu*

© The Korean Society for Thoracic and Cardiovascular Surgery. 2019. All right reserved.

© This is an open access article distributed under the terms of the Creative Commons Attribution Non-Commercial License (<http://creativecommons.org/licenses/by-nc/4.0>) which permits unrestricted non-commercial use, distribution, and reproduction in any medium, provided the original work is properly cited.



**Fig. 1.** Coronary angiography showed dilatation of the internal thoracic artery and proximal LAD. LITA, left internal thoracic artery; LAD, left anterior descending artery; LCx, left circumflex artery.



**Fig. 2.** The most recent echocardiogram showed the prosthetic TV at the supra-coronary sinus position. RV, right ventricle; CS, coronary sinus; TV, tricuspid valve.

homograft, and tricuspid valve replacement with a 31-mm Carpentier-Edwards tissue valve (Edwards Lifesciences, Irvine, CA, USA) at the supra-coronary sinus position. On postoperative day (POD) 1, the patient showed aphasia and right hemiplegia with hemorrhagic changes in septic emboli. Nevertheless, the patient was discharged without any neurologic sequelae on POD 60, following 6 weeks of culture-directed antibiotic therapy.

Seven years later, in 2009, the patient gave birth without any complications, following termination of aspirin use for 10 months. In 2012, the patient presented to an outpatient clinic because of dyspnea with NYHA class II heart failure. Transthoracic echocardiography showed severe aortic and tricuspid stenosis and moderate insufficiency in both valves. Transthoracic echocardiography also demonstrated mild left ventricle systolic dysfunction with an ejection fraction of 40%–45%. Coronary angiography showed a hugely dilated LITA with a diameter of 6 mm and an intact proximal LAD coronary artery (Fig. 1).

The second operation, a Bentall operation with a 23-mm St. Jude aortic valved graft (St. Jude Medical, Little Canada, MN, USA) and tricuspid valve replacement with a 31-mm St. Jude mechanical mitral valve (St. Jude Medical) at the supra-coronary sinus position, was performed using standard CPB under conditions of deep hypothermia. While lowering the pa-

tient's body temperature, we opened the right atrium and removed the tissue valve cusps of the previously implanted tricuspid valve. After clamping the ascending aorta and the proximal LITA, retrograde cold blood cardioplegic solution was infused into the coronary sinus without drainage of the left coronary artery. The lowest rectal temperature was 22°C. The total CPB time and aortic cross-clamping time were 241 minutes and 138 minutes, respectively. The conventional and modified hemofiltration amounts were 4,000 mL and 600 mL, respectively. Follow-up echocardiography on POD 10 showed well-functioning prosthetic valves, and the patient was discharged on POD 12 without any complications. To date, the patient has been doing well, with a left ventricular ejection fraction of 57% (Fig. 2).

## Discussion

Destruction of the LCO due to a periannular abscess in cases of infective endocarditis is a potentially fatal situation. Not only is aortic root abscess a disease with high rates of morbidity and mortality [1], but septic coronary embolism is a life-threatening scenario [2]. In cases of LCO destruction, various techniques have been suggested, including the Cabrol technique, the hemi-Cabrol technique using a saphenous vein graft [3], the translocation technique

[4], and local repair with pericardium [1].

In this case, a cryopreserved aortic homograft was used for aortic root replacement, and coronary artery grafting of the LITA to the proximal LAD with external ligation of the LCO was performed concomitantly. We selected an aortic homograft for the aortic position due to severe root inflammation and the patient's desire for a future pregnancy. In fact, she delivered a baby after the first operation.

A tricuspid valve was implanted in the supra-annular position with placement of the coronary sinus on the right ventricular side. Ohata et al. [5] described the good long-term durability of this technique, as well as the absence of fatal arrhythmias and pulmonary thromboembolism.

In the second operation, myocardial protection was a concern. There were various options, including antegrade cardioplegia infusion via the dilated LITA and retrograde cardioplegia infusion with or without LITA drainage [6]. We chose intermittent retrograde cold blood cardioplegia infusion via the coronary sinus, without drainage through the LITA, under conditions of deep hypothermia.

In conclusion, in this patient who underwent ligation of the left main coronary artery, prolonged procedures under deep hypothermia and retrograde infusion of cold cardioplegia without drainage were performed without myocardial damage.

### Conflict of interest

No potential conflict of interest relevant to this article was reported.

### ORCID

Dong Woog Yoon: <https://orcid.org/0000-0003-3845-9151>

Sang On Lee: <https://orcid.org/0000-0002-3361-1946>

Pyo Won Park: <https://orcid.org/0000-0002-0892-4107>

### References

1. Leontyev S, Borger MA, Modi P, et al. *Surgical management of aortic root abscess: a 13-year experience in 172 patients with 100% follow-up.* J Thorac Cardiovasc Surg 2012;143:332-7.
2. Zeller L, Flusser D, Shaco-Levy R, Giladi H, Merkin MS, Liel-Cohen N. *A rare complication of infective endocarditis: left main coronary artery embolization resulting in sudden death.* J Heart Valve Dis 2010;19:225-7.
3. Dimarakis I, Wooldridge WJ, Kadir I. *Homograft aortic root replacement with saphenous vein graft hemi-Cabrol for prosthetic aortic valve endocarditis.* Aorta (Stamford) 2015;3:81-5.
4. Smail H, Saxena P, Zimmet AD, McGiffin DC. *Reconstruction and replacement of the aortic root in destructive endocarditis.* Oper Tech Thorac Cardiovasc Surg 2015;20: 336-54.
5. Ohata T, Kigawa I, Yamashita Y, Wanibuchi Y. *Surgical strategy for severe tricuspid valve regurgitation complicated by advanced mitral valve disease: long-term outcome of tricuspid valve supra-annular implantation in eighty-eight cases.* J Thorac Cardiovasc Surg 2000;120: 280-3.
6. Byrne JG, Karavas AN, Filsoufi F, et al. *Aortic valve surgery after previous coronary artery bypass grafting with functioning internal mammary artery grafts.* Ann Thorac Surg 2002;73:779-84.