

# Acute Pulmonary Thromboembolism: 14 Years of Surgical Experience

Jiye Park, M.D., Sang-Hyun Lim, M.D., Ph.D., You Sun Hong, M.D.,  
Soojin Park, M.D., Cheol Joo Lee, M.D., Ph.D., Seung Ook Lee, M.D.

*Department of Thoracic and Cardiovascular Surgery, Ajou University School of Medicine, Suwon, Korea*

**Background:** Pulmonary thromboembolism (PTE) is a life-threatening disease with high mortality. This study aimed to assess the outcomes of surgical embolectomy and to clarify the sustained long-term effects of surgery by comparing preoperative, postoperative, and long-term follow-up echocardiography outcomes. Of 22 survivors, 21 were followed up for a mean (median) period of 6.8±5.4 years (4.2 years). **Methods:** We retrospectively reviewed 27 surgical embolectomy cases for massive or submassive acute PTE from 2003 to 2016. Immediate and long-term follow-up outcomes of surgical embolectomy were assessed on the basis of 30-day mortality, long-term mortality, postoperative complications, right ventricular systolic pressure, and tricuspid regurgitation grade. **Results:** The 30-day and long-term mortality rates were 14.8% (4 of 27) and 4.3% (1 of 23), respectively. Three patients had major postoperative complications, including hypoxic brain damage, acute kidney injury, and endobronchial bleeding, respectively (3.7% each). Right ventricular systolic pressure (median [range], mm Hg) decreased from 62.0 (45.5–78.5) to 31.0 (25.7–37.0,  $p < 0.001$ ). The tricuspid valve regurgitation grade (median [range]) decreased from 1.5 (0.63–2.00) to 0.50 (0.50–1.00,  $p < 0.05$ ). The improvement lasted until the last echocardiographic follow-up. **Conclusion:** Surgical embolectomy revealed favorable mortality and morbidity rates in patients with acute massive or submassive PTE, with sustained long-term improvements in cardiac function.

*Key words:* 1. Pulmonary embolism  
2. Outcomes  
3. Surgery, complications  
4. Cardiopulmonary bypass  
5. Echocardiography

## Introduction

Pulmonary thromboembolism (PTE) is the third most common cause of death among cardiovascular diseases in the United States; its fatality rate is higher than that of acute myocardial infarction [1]. PTE has traditionally been divided into high-risk, inter-

mediate risk, and low-risk. The choice of treatment is based on risk stratification, ranging from anticoagulation alone to thrombolysis, surgical embolectomy, and catheter embolectomy. Surgical embolectomy has generally been used as the last treatment choice for acute PTE with significant right ventricular (RV) dysfunction. The European Society of Cardiology

<sup>†</sup>This study was presented at 49th Fall Meeting of Korean Society for Thoracic and Cardiovascular Surgery.

Received: July 16, 2018, Revised: November 9, 2018, Accepted: November 12, 2018, Published online: April 5, 2019

Corresponding author: Sang-Hyun Lim, Department of Thoracic and Cardiovascular Surgery, Ajou University Hospital, Ajou University School of Medicine, 164 World cup-ro, Yeongtong-gu, Suwon 16499, Korea (Tel) 82-62-464-4615 (Fax) 82-31-219-5215 (E-mail) [dbricasa@aumc.ac.kr](mailto:dbricasa@aumc.ac.kr)

© The Korean Society for Thoracic and Cardiovascular Surgery. 2019. All right reserved.

© This is an open access article distributed under the terms of the Creative Commons Attribution Non-Commercial License (<http://creativecommons.org/licenses/by-nc/4.0>) which permits unrestricted non-commercial use, distribution, and reproduction in any medium, provided the original work is properly cited.

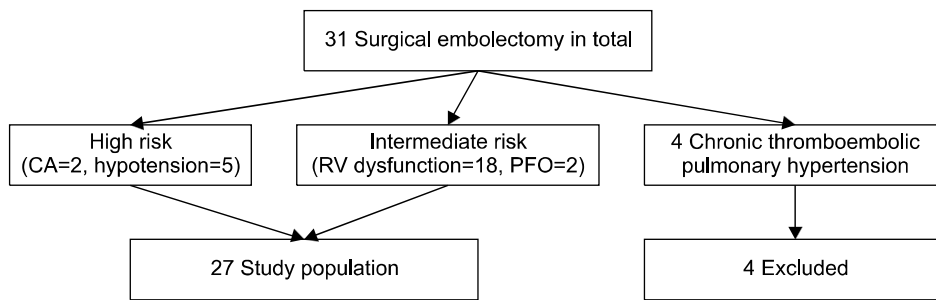


Fig. 1. Algorithm of inclusion and exclusion of the study population. CA, cardiac arrest; RV, right ventricle; PFO, patent foramen ovale.

guideline and other widely used guidelines suggest that surgical embolectomy is indicated when a patient has conditions such as patent foramen ovale (PFO) or intracardiac thrombus, if thrombolysis is contraindicated, or if thrombolysis has failed [2]. In light of the increasing number of papers reporting successful results, the idea of early surgical intervention for PTE patients with signs of shock or RV dysfunction is now being more positively considered and attempted. Most studies have been conducted in North America or Europe, and few reports have been published regarding surgical embolectomy in Korea. Cho et al. [3] found that surgery showed good results in comparison with thrombolysis. The aim of this study was to confirm our hypothesis that surgery in PTE patients with cardiopulmonary collapse or signs of RV dysfunction can have favorable outcomes and to assess their long-term results using transthoracic echocardiography (TTE).

## Methods

### 1) Patients

All patients who underwent surgical pulmonary embolectomy for acute PTE between January 2003 and December 2016 were evaluated. From 2003 to 2016, 7 patients underwent surgery at Sinchon and Gangnam Severance Hospital in Seoul, and 20 other patients underwent surgery in 2007 at Ajou University Hospital, Suwon (IRB approval no., AJIRB-MED-MDB-18-313). Informed consent was waived. All operations were performed by a single surgeon (S.H.L.). Patients who had been diagnosed with chronic PTE were excluded. Ten patients received elective surgery, whereas emergent operations were performed in 17 patients (Fig. 1). Long-term survival was evaluated by referring to data from the National Healthcare Insurance Service.

### 2) Preoperative examination

All 27 patients underwent pulmonary angiographic computed tomography (CT) or chest CT with contrast, and 21 patients underwent echocardiography before surgery. The left ventricular ejection fraction, RV pressure, and valve function were documented. Portable Doppler ultrasonography was performed to detect deep vein thrombosis (DVT). Six patients were diagnosed as having DVT before surgery. The patients who underwent emergent operations received Doppler ultrasonography after surgery.

### 3) Surgical intervention

The surgical indication was thromboembolism involving the unilateral or bilateral main pulmonary artery confirmed using pulmonary angiographic CT or echocardiography, simultaneously satisfying 1 of the following criteria: (1) cardiopulmonary collapse; (2) RV systolic pressure (RVSP) of  $>45$  mm Hg and/or echocardiographic evidence of RV dysfunction; (3) systolic blood pressure (SBP) of  $<90$  mm Hg or a decrease of 40 mm Hg from the baseline SBP for more than 15 minutes; or (4) intraoperative transesophageal echocardiography (TEE) allowing cardiac anesthesiologists to confirm the thrombosis in the main pulmonary arteries and RV dysfunction on the basis of wall motion abnormality or ventricle size despite not being able to measure the numerical RV pressure or tricuspid regurgitation (TR) pressure gradient. Among the 27 patients, 24 satisfied the above indications, 2 had intermediate-risk PTE with PFO, and 1 had hepatocellular carcinoma with inferior vena cava (IVC) invasion, right atrium thrombi, and PTE. That patient underwent combined pulmonary embolectomy and hepatectomy performed by 2 surgeons. The 2014 European guideline recommends not to perform aortic cross-clamping during pulmonary embolectomy [2]. However, the surgeon se-

lectively performed aortic cross-clamping to obtain a satisfactory visual field after opening the pulmonary artery. In some cases, when trying to remove a thrombus in the segmental arteries, when the lumen of the segmental arteries was difficult to visualize, short-duration deep hypothermic circulatory arrest (DHCA) was performed with a target temperature of 20°C. All patients received cardiopulmonary bypass (CPB), but the CPB time was not documented in 9 patients from 2003 to 2005. The mean CPB time of the 18 documented patients was 140.9±41.2 minutes. All operations were performed with bicaval cannulation, and the cardioplegic solution used during aortic cross-clamping was Custodiol (histidine-tryptophan-ketoglutarate; Zenithpharm, Daegu, Korea). DHCA was applied in 10 patients, with a mean DHCA time of 28.3±18.6 minutes. Intravenous heparinization was restarted 6 to 12 hours after surgery when no active bleeding was observed, and none of the cases required reopening of the pulmonary artery due to hemorrhage.

#### 4) Postoperative follow-up

Postoperative echocardiography was first performed in 22 patients on postoperative day 0–19. Of the 5 patients who could not undergo echocardiography, 3 died after 30 days and the other 2 were discharged without any complications and were followed up on an outpatient basis for 6 months. The mean echocardiography follow-up period was 6.8±5.4 years (median, 4.2 years).

#### 5) Statistical analyses

All analyses used SPSS ver. 12.0 (SPSS Inc., Chicago, IL, USA). Continuous variables are presented as mean±standard deviation or median with interquartile range. When comparing the RVSP and TR across 3 groups which are preoperative, postoperative, and last follow-up TTE data, preoperative, postoperative, and last follow-up TTE data were analyzed using the Kruskal-Wallis test. For the analysis, trivial TR was converted to a numerical value as a TR grade of 0.5. All p-values of <0.05 were considered to indicate statistical significance. Values are presented as mean±standard deviation, number (%), or median (interquartile range).

## Results

Twelve patients were male and 15 were female, with ages ranging from 20 to 77 years. Fifteen patients were diagnosed as having DVT before or after surgery. Six of the patients received IVC filter insertion preoperatively and 9 had a postoperative filter inserted. Of those 9 patients, 3 had underlying atrial fibrillation, 3 showed antiphospholipid syndrome (confirmed by antibody positivity) during the perioperative evaluation, and 3 had recently undergone orthopedic surgery or splint placement. The other comorbidities were PFO, a distant history of a cerebrovascular accident with bedridden status, intracranial hemorrhage (ICH) with right hemiplegia, chronic kidney disease, schizophrenia, major depressive disorder, and hepatocellular carcinoma with IVC invasion (Table 1). Two patients received veno-arterial extracorporeal membrane oxygenation (V-A ECMO) before surgery because of cardiac arrest, of whom 1 had a status of 1 day postpartum after a cesarean section. A 75-year-old female patient underwent emergency surgical embolectomy for an acute massive PTE the day after undergoing an off-pump coronary artery bypass operation. Massive PTE involving the bilateral main pulmonary trunk was first diagnosed using portable TTE that was performed because of persistent hypotension, hypoxia, and metabolic acidosis after surgery. She was admitted to the operating room with a high dose of inotropics, discharged from the operating room with ECMO, and died on postoperative day 3 because of intractable right heart failure.

The 30-day mortality rate was 14.8% (4 of 27), and the in-hospital mortality rate was 4.3% (1 of 23). The most common cause of death was right heart failure; 3 patients died of multiorgan failure because of intractable heart failure, and the other patient died of acute lung injury. A 34-year-old female patient died 2 months after surgery because of hypoxic brain damage. The mean ventilator time was 120.9±180.2 hours and the mean length of intensive care unit stay was 8.2±8.4 days.

The postoperative complications were adult respiratory distress syndrome, acute kidney injury, mediastinitis, vocal cord palsy, and chorea. Two patients were diagnosed as having severe hypoxic brain damage postoperatively, both of whom were brought to

Table 1. Preoperative and perioperative patient characteristics

No.	Age (yr)/sex	DVT	IVC filter insertion	Priority	Condition	Risk factors	Mortality	F/U period (day)
1	48/M	Y	Preoperative	EL	RV dysfunction	APS	None	4,974
2	47/F	N	Preoperative	EM	Shock (SBP < 90 mm Hg)		None	4,420
3	45/F	Y	Preoperative	EL	RV dysfunction		None	2,520
4	33/M	Y	Postoperative	EM	RA thrombi, PFO		None	4,771
5	30/F	Y	Postoperative	EL		APS	None	4,935
6	50/F	Y	Postoperative	EL	RV dysfunction		None	4,930
7	63/F	N	Postoperative	EL	RV dysfunction	APS, old age	None	4,893
8	75/F	N	-	EM	CA, ECMO	OPCAB POD 1	POD 1	
9	77/F	Y	Preoperative	EL	RV dysfunction	CHF, old age	None	3,242
10	50/F		-	EL	IVC invasion	HCC	None	181
11	24/M	N	Postoperative	EM	RHF, atrial fibrillation		None	1,375
12	55/M	N	Postoperative	EM	RHF, atrial fibrillation		None	2,660
13	51/F	N	Postoperative	EM	RV dysfunction	ICH, bedridden	None	1,931
14	58/M	N	-	EM	RV dysfunction	CVA, bedridden		F/U loss
15	48/M	Y	Postoperative	EM		Trauma, multiple fracture	None	1,510
16	51/F	Y	Postoperative	EL	PFO	TA, tibia fracture	None	1,260
17	65/F	N	-	EL		MDD <sup>a)</sup> , old age	None	1,198
18	30/M	N	-	EL	RV dysfunction		None	1,170
19	26/M	Y	Postoperative	EM		MDD, schizophrenia <sup>a)</sup>	None	1,180
20	20/F	Y	Preoperative	EM	RV dysfunction		None	770
21	47/F	Y	Postoperative	EM	RV dysfunction	Schizophrenia	None	710
22	48/M	N	-	EM	Shock (SBP < 90 mm Hg)		POD 4	
23	42/F	N	-	EM	CA, ECMO	Cesarean section POD 1	None	467
24	67/M	N	-	EM	Shock (SBP < 90 mm Hg)	HCC, old age	POD 1	
25	50/M	Y	Postoperative	EM	RV dysfunction		None	474
26	34/F	Y	Preoperative	EM	Shock (SBP < 90 mm Hg)		POD 63	
27	44/F	Y	-	EM	Shock, ECMO		POD 5	
Total mean	F=15, M=12, 47.3±14.7	14 (52)	20 (74)	EM=17 (63)	CA, shock=7 (26)	13 (48)	5 (18.5)	6.8±5.4 yr

Values are presented as mean±standard deviation or number (%).

DVT, deep vein thrombosis; IVC, inferior vena cava (filter insertion); F/U, follow-up; M, male; F, female; Y, yes; N, no; EL, elective; EM, emergency; RV, right ventricle; APS, anti-phospholipid syndrome (antibody-positive); SBP, systolic blood pressure; RA, right atrium; PFO, patent foramen ovale; CA, cardiac arrest; ECMO, extracorporeal membrane oxygenation; OPCAB, off-pump coronary artery bypass surgery; POD, postoperative day; CHF, congestive heart failure; HCC, hepatocellular carcinoma; RHF, right heart failure; ICH, intracranial hemorrhage; CVA, cerebrovascular accident; TA, traffic accident; MDD, major depressive disorder.

<sup>a)</sup>MDD and schizophrenia are not risk factors of PTE, so they were not counted as comorbidities. But we included this information because of the possibility that medication to treat these conditions could lead to adverse drug reactions with a thrombogenic effect.

the operating room after cardiac arrest and cardiopulmonary resuscitation (CPR). One of them was a 42-year-old female patient who had undergone a cesarean section 1 day previously and received V-A ECMO before surgical embolectomy. The CPB time was 193 minutes, and no DHCA was applied, only mild hypothermia. The latter case was previously mentioned as an instance of long-term mortality; it

involved a 34-year-old female patient who developed DVT and PTE 1 month after left leg splint placement due to trauma, received CPR from paramedics in the ambulance, and was resuscitated on arrival. Neither of the patients received a brain evaluation before the operation, so whether hypoxic brain damage occurred preoperatively was unclear, although it was strongly suspected in the former case.

**Table 2. Transthoracic echocardiogram results**

Variable	Preoperative	Postoperative	Last follow-up	p-value
Right ventricular systolic pressure (mm Hg)	62.0 (45.5–78.5) (n=21)	31.0 (25.6–37.2) (n=21)	25.9 (23.0–32.5) (n=14)	<0.001
Tricuspid regurgitation (grade)	1.50 (0.63–2.00) (n=20)	0.50 (0.50–1.00) (n=22)	0.50 (0.13, 0.50) (n=12)	<0.05

Values are presented as median (interquartile range), unless otherwise stated.

The median preoperative RVSP was 62.0 mm Hg (45.5–78.5 mm Hg), and the median first and last postoperative follow-up RVSPs were 31.0 mm Hg (25.6–37.2 mm Hg) and 25.9 mm Hg (23.0–32.5 mm Hg), respectively (Table 2). The median preoperative TR grade was 1.50 (0.63–2.00), which decreased to 0.50 (0.50–1.00) postoperatively and improved to 0.50 (0.13–0.50) on the last follow-up echocardiography. We assigned trivial TR a TR grade of 0.5.

## Discussion

### 1) Surgical indications

PTE is usually categorized as high-, intermediate-, and low-risk [2]. The traditional criterion of a CT finding of massive thrombosis in the main pulmonary artery or more than 2 lobar arteries has been changed to a clinical criterion [2]. Recent studies have shown that mortality is more closely related to systolic arterial hypotension or RV dysfunction in normotensive patients than to anatomical obstructiveness [1]. Recent guidelines have suggested using the categorization of high-risk PTE, rather than massive PTE, for the same reason [2]. High-risk or massive PTE patients show SBPs of <90 mm Hg or a decrease in SBP of at least 40 mm Hg for >15 minutes, circulatory collapse, or cardiac arrest. Patients with submassive PTE are usually normotensive but show signs of RV dysfunction on TTE, TEE, or echocardiography, sometimes with elevated pro-brain natriuretic peptide and troponin I levels. A combination of RV pressure overload and dilation due to PTE eventually leads to a decrease in stroke volume and cardiac output [4]. As RV dysfunction is a significant prognostic factor related to 3-month mortality, invasive treatments such as thrombolysis, surgical embolectomy, or catheter embolectomy are commonly recommended in patients with RV dysfunction [1,5]. Thus, echocardiographic findings are important for selecting treatment options.

### 2) Assessment of right ventricular dysfunction

Various criteria and signs have been used for diagnosing RV dysfunction with echocardiography. The most commonly used indicative findings include the ratio of the RV end-diastolic diameter (RVEDD) to the LV end-diastolic diameter (LVEDD) (>0.9 or >1.0), septal dyskinesia, RV hypokinesia, and a tricuspid valve pressure gradient of >30 mm Hg; most commonly, 2 or more criteria are used to diagnose RV dysfunction [6]. A prospective study suggested a tricuspid regurgitant jet velocity of >2.7 m/sec, which showed a high positive predictive value when coupled with other echocardiographic findings [7]. As a limitation of a retrospective study, however, we could not obtain information on any of these parameters. Thus, it was necessary to use other criteria to define RV dysfunction. We considered RV dysfunction to be present when 2 cardiologists confirmed RV hypokinesia, a fractional area change of <30%, or a RVEDD/LVEDD ratio of >0.9. TR was suggested as a sign of RV dysfunction, although trivial TR should be changed into a numerical grade to obtain a mean value and compare its values across groups. We defined trivial TR as grade 0.5, and the decrease in postoperative TR grade was so significant that it did not seem to make a statistically meaningful difference.

RVSP can also be a useful criterion to assess the severity of PTE, as PTE usually causes moderate to severe dyspnea on exertion. Therefore, RVSP is an important diagnostic value for acute PTE and chronic thromboembolic pulmonary hypertension (CTEPH) [8]. The RVSP is equal to the pulmonary artery pressure, so it is used to estimate the pressure inside the artery that supplies the lung with blood.

The median RVSP decreased from 62.0 mm Hg (45.5–78.5 mm Hg) to 31.0 mm Hg (25.6–37.5 mm Hg), which was found to be statistically meaningful by the Kruskal-Wallis test.

### 3) Long-term follow-up results

We hypothesized that the effect of surgery would be maintained with a low recurrence rate and low progression rate to CTEPH because surgical embolectomy can directly remove thrombosis at the segmental artery level and the remnant thrombus on the endothelium would be minimal. With the same hypothesis, many research groups reported positive long- and mid-term results after surgical pulmonary embolectomy. For example, Kneeling et al. reported favorable results at mid-term follow-up after surgical embolectomy [9]. In this study, the mean follow-up period of the 21 patients was  $6.8 \pm 5.4$  years (median, 4.2 years). None of the patients experienced recurrence. The median last follow-up RVSP was 25.9 mm Hg (23.0–32.5 mm Hg), which was a significant decrease from the preoperative mean RVSP ( $p < 0.001$ ).

### 4) Comparison of thrombolysis and surgical embolectomy

Current guidelines recommend thrombolysis as the first-line therapy and surgical embolectomy when thrombolysis is contraindicated or has failed. However, in light of reports of successful results of catheter and surgical embolectomy, some of the latest guidelines suggest choosing an appropriate treatment option depending on the local condition of patients with massive or submassive PTE [10]. In our study, surgical embolectomy was indicated or fibrinolysis was contraindicated in 2 patients with PFO, 1 patient with a history of ICH, and 2 patients with a postoperative status, but not in the others.

Owing to the risk of major bleeding, especially ICH, many physicians hesitate to start fibrinolysis and PTE patients with cardiopulmonary collapse often fail to receive early appropriate treatment. This is a reasonable fear because the International Cooperative Pulmonary Embolism Registry reported that the risk of ICH may be as high as 3% [1] and another study reported that the overall major bleeding rate of fibrinolysis for acute PTE may approach 20% [11].

On the contrary, increasingly many studies have reported successful results of surgical pulmonary embolectomy for acute PTE, especially in patients with cardiopulmonary collapse or RV dysfunction. Likewise, our study showed favorable results in terms of short- and long-term outcomes. We suggest that a more active surgical approach should be used in patients

with massive PTE with RV dysfunction.

### 5) Study limitations

This study was conducted retrospectively, and some medical records were missing, such as CPB time and postoperative echocardiography. In all patients, the surgical intervention was performed by a single surgeon, which could simultaneously serve as a control for the surgical technique and be a limitation of the study. The patients' perioperative characteristics were heterogeneous, and some did not have sufficient perioperative and postoperative clinical information. All echocardiograms were reviewed by 2 cardiologists.

In conclusion, we report favorable immediate postoperative and long-term follow-up results of surgical embolectomy for acute PTE patients with cardiopulmonary collapse or signs of RV dysfunction. In light of other recent successful reports of the surgical approach in high-risk PTE patients, we suggest surgical embolectomy as the treatment of choice for carefully selected patients.

### Conflict of interest

No potential conflict of interest relevant to this article was reported.

### Acknowledgments

This study was supported by a Grant of the Samsung Vein Clinic Network (Daejeon, Anyang, Cheongju, Cheonan; Fund no. KTCS04-116).

### ORCID

Jiye Park: <https://orcid.org/0000-0001-9289-2760>  
Sang-Hyun Lim: <https://orcid.org/0000-0002-2722-3007>  
You Sun Hong: <https://orcid.org/0000-0003-4933-5111>  
Soojin Park: <https://orcid.org/0000-0002-6268-5231>  
Cheol Joo Lee: <https://orcid.org/0000-0001-9117-1291>  
Seung Ook Lee: <https://orcid.org/0000-0003-1616-3595>

### References

1. Goldhaber SZ, Visani L, De Rosa M. *Acute pulmonary embolism: clinical outcomes in the International Cooperative Pulmonary Embolism Registry (ICOPER)*. *Lancet* 1999;353:

- 1386-9.
2. Konstantinides SV, Torbicki A, Agnelli G, et al. *2014 ESC guidelines on the diagnosis and management of acute pulmonary embolism*. Eur Heart J 2014;35:3033-69.
  3. Cho YH, Sung K, Kim WS, et al. *Management of acute massive pulmonary embolism: is surgical embolectomy inferior to thrombolysis?* Int J Cardiol 2016;203:579-83.
  4. Goldhaber SZ. *Pulmonary embolism*. Lancet 2004;363:1295-305.
  5. Kearon C, Kahn SR, Agnelli G, Goldhaber S, Raskob GE, Comerota AJ. *Antithrombotic therapy for venous thromboembolic disease: American College of Chest Physicians Evidence-Based Clinical Practice Guidelines (8th edition)*. Chest 2008;133(6 Suppl):454S-545S.
  6. Stawicki SP, Seamon MJ, Meredith DM, et al. *Transthoracic echocardiography for suspected pulmonary embolism in the intensive care unit: unjustly underused or rightfully ignored?* J Clin Ultrasound 2008;36:291-302.
  7. Miniati M, Monti S, Pratali L, et al. *Value of transthoracic echocardiography in the diagnosis of pulmonary embolism: results of a prospective study in unselected patients*. Am J Med 2001;110:528-35.
  8. Park JS, Ahn J, Choi JH, et al. *The predictive value of echocardiography for chronic thromboembolic pulmonary hypertension after acute pulmonary embolism in Korea*. Korean J Intern Med 2017;32:85-94.
  9. Keeling WB, Leshnower BG, Lasajanak Y, et al. *Midterm benefits of surgical pulmonary embolectomy for acute pulmonary embolus on right ventricular function*. J Thorac Cardiovasc Surg 2016;152:872-8.
  10. Deakin CD, Nolan JP, Soar J, et al. *European Resuscitation Council guidelines for resuscitation 2010: section 4. adult advanced life support*. Resuscitation 2010;81:1305-52.
  11. Fiumara K, Kucher N, Fanikos J, Goldhaber SZ. *Predictors of major hemorrhage following fibrinolysis for acute pulmonary embolism*. Am J Cardiol 2006;97:127-9.