Journal of the Korea Academia-Industrial cooperation Society
Vol. 19, No. 6 pp. 427-431, 2018

https://doi.org/10.5762/KAIS.2018.19.6.427
ISSN 1975-4701 / eISSN 2288-4688

Klebsiella Pneumonia-Necrotizing Fasciitis followed by Liver Abscess

Seung Hyun Lee[1], Jeong Woo Choi[2], Myeung Su Lee[3*]
[1]**Department of Pediatrics, Wonkwang University School of Medicine**
[2]**Department of Emergency Medicine, Wonkwang University School of Medicine**
[3]**Department of Internal Medicine, Wonkwang University School of Medicine**

폐렴 간균-괴사성 근막염에 이어 발생한 간농양

이승현[1], 최정우[2], 이명수[3*]
[1]원광대학교 의과대학 소아과학교실, [2]원광대학교 의과대학 응급의학교실,
[3]원광대학교 의과대학 내과학교실

Abstract We report a case of a patient with necrotizing fasciitis followed by liver abscess. A 51-year-old man was admitted to our hospital with a 5-day history of fever and chills with painful swelling of the right thigh. A magnetic resonance imaging (MRI) scan showed fluid collection with numerous dark signal intensities considered as air-bubbles between the posteromedial and posterolateral groups of the right thigh, resulting in presumptive diagnosis of necrotizing fasciitis. At the time of admission, an ultrasonograph of the abdomen showed increased parenchymal echogenicity of both kidneys and no liver abscess. Ten days after fasciotomy, an abdominal computed tomography (CT) scan showed intrahepatic abscess. Sonography-guided percutaneous drainage was performed. Both cultures of pus specimens from the liver abscess and right thigh yielded Klebsiella pneumoniae (K. pneumoniae). The patient was treated with fasciotomy several times and parenteral antibiotics, after which he began to improve. After 5 weeks, liver abscess size was reduced, and after 10 weeks, liver abscess disappeared. To the best of our knowledge, this is the first case of K. pneumoniae-necrotizing fasciitis followed by liver abscess.

요 약 본 저자들은 괴사성 근막염 환자에서 간농양이 발생한 사례가 있어 보고하고자 한다. 5일 동안 지속되는 우측 대퇴부의 통증을 동반한 부종, 발열, 오한을 주소로 51세 남자 환자가 본원에 내원하였다. 내원 당시 시행한 MRI 검사 상 우측 대퇴부의 후내측과 후외측 부분에 공기 방울로 보이는 다량의 어두운 음영과 액체 군집이 있어 괴사성 근막염으로 추정 진단하였다. 입원 당시 시행한 복부 초음파 검사 상 양측 신장의 실질 에코는 증가하였지만 간 내 농양은 보이지 않았다. 근막 절개 10일 후에 시행한 복부 컴퓨터 단층촬영 검사 상 간 내 농양이 보여, 초음파 검사를 통한 경피적 배액술을 시행하였다. 우측 대퇴부와 간농양에서 배약된 농 검체 모두 폐렴 간균이 배양되었다. 환자는 몇 차례 근막 절개술을 시행 받았고 비경구 항생제로 치료한 결과 점차 호전이 되기 시작했다. 치료 시작 5주 후 간농양의 크기는 감소하였고, 10주 후 간농양은 사라졌다. 우리가 아는 한 폐렴 간균 괴사성 근막염에서 간농양이 발생한 첫 사례이기에 보고하는 바이다.

Keywords : Fasciotomy, Klebsiella Pneumonia, Liver Abscess, Necrotizing Fasciitis, Percutaneous Drainge.

This paper was supported by Wonkwang University in 2017.
*Corresponding Author : Myeung Su Lee(Wonkwang Univ.)
Tel: +82-63-859-2661 email: ckhlms@hanmail.net
Received March 16, 2018 Revised (1st March 30, 2018, 2nd April 6, 2018)
Accepted June 1, 2018 Published June 30, 2018

1. Introduction

Necrotizing fasciitis(NF) is life-threatening disease characterized by its spread along the fascial planes, resulting in adjacent tissue necrosis and secondary gangrene[1]. There were some reports of necrotizing fasciitis with *K. pneumonia* liver abscess[2-3].

However, necrotizing fasciitis followed by liver abscess has not been reported. Here, we report a case of a patient with *Klebsiella pneumonia*-necrotizing fasciitis(KP-NF) followed by liver abscess. To our knowledge, this is the first report on *K. pneumonia* liver abscess originated from necrotizing fasciitis.

2. Case Report

A 51-year-old man presented with a 5-day history of fever, chills, and myalgia. He had been treated at a local clinic for 1 week, but his symptom had been worsened and he had developed acute renal failure and right leg swelling with erythema 2 days before admission. He had no past history and was not currently on any regular medication. His vital signs were as follows: blood pressure, 120/70 mmHg; pulse rate, 102 /min; respiration rate, 20 /min; and body temperature, 38.5℃. Physical examination showed an acutely ill man and no direct tenderness on abdomen. His right thigh had marked swelling with induration and severe tenderness. Laboratory studies disclosed the following: Hemoglobin level, 12.0 g/dL; initial WBC count, 13,390 /uL; platelet count, 190,000 /uL; serum glucose level, 347 mg/dL; Hb A1c, 13.7%; serum albumin level, 2.6 g/dL; total bilirubin level, 1.0 mg/dL; AST/ALT, 101/72 IU/L; BUN, 70 mg/dL; Creatinine level, 5.71 mg/dL; alkaline phosphatase level, 1266 IU/L; Lactose dehydrogenase level, 485 IU/L; erythrocyte sedimentation rate, 120 mm/Hr and C-reactive protein level, 249.2 mg/L. An abdominal sonography showed mild dilatation of cystic duct without definite stone and increased renal parenchymal echogenicity in both kidneys. A MRI scan of the right thigh showed fluid collection with numerous dark signal intensity considered as air-bubble along the intermuscular septum between posteromedial and posterolateral group of right thigh(Fig.1). A presumptive diagnosis of necrotizing fasciitis with diabetes mellitus(DM) was made and extensive lateral fasciotomy and drainage were performed; necrotizing fasciitis was observed, and areas of necrosis were debrided. Culture of the material repeatidly yielded only *K. pneumoniae*. Therapy with parenteral carbapenem and clindamycin was administered with tight blood sugar control.

Fig. 1. MRI showing multiple very small low signal intensities along the intermuscular septum of right thigh suggesting gas bubble(arrow).

10 days after fasciotomy, he still had fever and right upper quadrant abdominal tenderness with elevated liver enzyme. A CT scan of the abdomen showed a 7x6 cm sized intrahepatic abscess and bilateral pleural effusion(Fig.2). Sonography-guided percutaneous drainage was performed. Cultures of pus specimens from the liver abscess and right thigh both yielded *K. pneumoniae*. After antibiotics therapy was continued, patient was discharged 80 days after admission. He remained free of liver abscess for 1 year of follow-up.

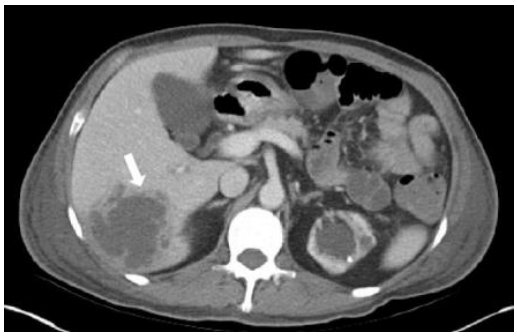

Fig. 2. Post-contrast CT showing a large low attenuated mass-like lesion(arrow) in right lobe of liver suggesting liver abscess.

3. Discussion

NF typically begins as a slightly inflamed area of soft tissue that suddenly and dramatically progresses to overt fasciitis with systemic toxicity[4]. However, it rarely spreads to the internal organ. To our knowledge, this is the first time that necrotizing fasciitis followed by liver abscess has been reported.

Bacteria of the Streptococcus species seem to be the most common single causative organism[5]. In the recent report, the relatively high frequency of *K. pneumoniae* made it one of the predominant pathogens that caused monomicrobial NF[6].

The clinical features of necrotizing fasciitis caused by *Klebsiella spp.* are similar to those of necrotizing fasciitis caused by other organisms, i.e., severe sepsis, a propensity for multi-organ failure and high mortality[7]. However, the potential for multifocal infection is unique to necrotizing fasciitis caused by *Klebsiella spp.* Some cases were noted to had one or more distant foci of infection including the brain, liver, lung, kidney and/or abdomen, including endogenous endophthalmitis[2]. In our case, it was thought that necrotizing fasciitis with *Klebsiella bacteremia* may spread to liver, since an abdominal sonography at admission showed no liver abscess and cultures from right thigh fascia and liver abscess have identified the same result. There were many cases reports on necrotizing fasciitis from internal organ such liver abscess and opthalmitis but it was the first time that liver abscess was originated from necrotizing fasciitis.

More than half of the patients developing NF have preexisting medical conditions, 35% at least two[8]. The most common predisposing risk factors include DM(30%), immune suppression(17%), end-stage renal failure, liver cirrhosis, pulmonary diseases(6%), malignancy(5%), and use of injection drugs. Especially, Monomicrobial *K. pneumoniae* NF(KP-NF) typically occurred in patients with underlying immunocompromising conditions, such as DM or liver cirrhosis[9]. But, the presence of DM and adequacy of glycemic control has, so far, not been shown to be associated with increased mortality or occurrence of metastatic infections[10]. Our patient also had diabetes that acts as a risk factor of NF, but he had not known and had not taken any medication.

NF is a surgical emergency, and early debridement is life-saving. Patients with NF due to *Klebsiella spp.* who develop cutaneous signs of soft tissue infections, such as erythema, swelling and tenderness, should be treated with caution and a high index of suspicion. A high index of suspicion and awareness are important, since early diagnosis and surgical debridement have been shown to improve survival[7].

The antimicrobial susceptibility patterns of the *Klebsiella* strains causing necrotizing fasciitis showed resistance to ampicillin but susceptibility to other antibiotics, including all cephalosporins and aminoglycosides tested. Multiple antimicrobial resistances were not detected[11]. But, there is the rationale for use of extended-spectrum cephalosporins or a carbapenem based on their better ability to penetrate the central nervous system, eye, and prostate, and the possibility that they may prevent metastatic infections[6]. The antimicrobial regimen chosen to treat our patients therefore included parenteral carbapenem in combination with a clindamycin. The parenteral antimicrobial agents were continued until 12 weeks depending on clinical response.

4. Conclusion

In conclusion, rarely NF can cause abscess of internal organ like our patient. Because of the potential for multifocal infection of *K. pneumoniae*, physicians should try to find out other metastatic foci with careful examination and try to treat combined lesion promptly when a patient with NF is not improved despite of proper treatment especially in the case of *K. pneumoniae* infection.

References

[1] Green RJ, Dafoe DC, Raffin TA, "Necrotizing fasciitis", Chest, vol. 110, no. 1, pp. 219-229, 1996.
DOI: https://doi.org/10.1378/chest.110.1.219

[2] Dylewski JS, Dylewski I, "Necrotizing fasciitis with *Klebsiella* liver abscess", Clin Infect Dis, vol. 27, no. 2, pp. 1561-1562, 1998.
DOI: https://doi.org/10.1086/517760

[3] Hu BS, Lau YJ, Shi ZY, Lin YH, "Necrotizing fasciitis associated with *Klebsiella pneumoniae* liver abscess", Clin Infect Dis, vol. 29, no. 5, pp. 1360-1361, 1999.
DOI: https://doi.org/10.1086/313471

[4] Imanishi N, Nakajima H, Aiso S, "Anatomic study of the venous drainage architecture of the forearm skin and subcutaneous tissue", Plast Reconstr Surg, vol. 106, no. 6, pp. 1287-1294, 2000.
DOI: https://doi.org/10.1097/00006534-200011000-00008

[5] Lancerotto L, Tocco I, Salmaso R, Vindigni V, Bassetto F, "Necrotizing fasciitis: classification, diagnosis, and management", The journal of trauma and acute care surgery, vol. 72, no. 3, pp. 560-566, 2012.
DOI: https://doi.org/10.1097/TA.0b013e318232a6b3

[6] Lee SS, "*Klebsiella pneumoniae* is an Emerging Major Pathogen in Necrotizing Fasciitis", Clin Infect Dis, vol. 55, no. 7, pp. 940-942, 2012.
DOI: https://doi.org/10.1093/cid/cis571

[7] Wong CH, Chang HC, Pasupathy S, Khin LW, Tan JL, Low CO, "Necrotizing fasciitis: clinical presentation, microbiology, and determinants of mortality", J Bone Joint Surg Am, vol. 85-A, no. 8, pp. 1454-1460, 2003.
DOI: https://doi.org/10.2106/00004623-200308000-00005

[8] O'Loughlin RE, Roberson A, Cieslak PR, Lynfield R, Gershman K, et al, "The epidemiology of invasive group A streptococcal infection and potential vaccine implications: United States, 2000-2004", Clin Infect Dis, vol. 45, no. 7, pp. 853-862, 2007.
DOI: https://doi.org/10.1086/521264

[9] Cheng NC, Yu YC, Tai HC, Hsueh PR, Chang SC, et al, "Recent Trend of Necrotizing Fasciitis in Taiwan: Focus on Monomicrobial *Klebsiella pneumoniae* Necrotizing Fasciitis", Clin Infect Dis, vol. 55, no. 7, pp. 930-939, 2007.
DOI: https://doi.org/10.1093/cid/cis565

[10] Lee SS, Chen YS, Tsai HC, Wann SR, Lin HH, et al, "Predictors of septic metastatic infection and mortality among patients with *Klebsiella pneumoniae* liver abscess", Clin Infect Dis, vol. 47, pp. 642-650, 2008.
DOI: https://doi.org/10.1086/590932

[11] Wang JH LY, Lee SS, Yen MY, Chen YS, Wang JH, Wann SR, Lin HH, "Primary liver abscess due to *Klebsiella pneumoniae* in Taiwan", Clin Infect Dis, vol. 26, no. 6, pp. 1434-1438, 1998.
DOI: https://doi.org/10.1086/516369

Seung Hyun Lee [Regular member]



- Jun. 2016 ~ current : Department of Pediatrics, Wonkwang University School of Medicine, Professor

<Research Interests>
Neonatology, Pediatrics, Clinical Medicine

Jeong Woo Choi [Lifetime member]

- Jun. 2016 ~ current : Department of Emergency Medicine, Wonkwang University School of Medicine, Professor

<Research Interests>
Emergency Medicine, Emergency Medical System, Clinical Medicine

Myeung Su Lee [Regular member]



- Sep. 2012 ~ current : Department of Internal Medicine, Wonkwang University School of Medicine, Professor

<Research Interests>
Rheumatology, Internal Medicine, Clinical Medicine