

## Atypical Bile Peritonitis Associated with White Bile in a Dog with Ruptured Gallbladder

Hyo-Min Kang, Hye-Jin Jang, Ji-Houn Kang, Gonhyung Kim, Dongwoo Chang and Ki-Jeong Na<sup>1</sup>

*Veterinary Medical Center and College of Veterinary Medicine, Chungbuk National University,  
Cheongju, Chungbuk 28644, Republic of Korea*

(Received: January 24, 2018 / Accepted: February 21, 2018)

**Abstract :** A 12-year-old spayed female Cocker Spaniel was presented with vomiting, diarrhea, depression, and hyporexia of 3-day duration. Microscopic examination of the abdominal fluid from a dog showed basophilic, amorphous to fibrillar materials without bile pigments or crystals. Total bilirubin concentration of the fluid was 19 times higher than the serum bilirubin concentration and exploratory laparotomy revealed a ruptured gallbladder and mucoceles in the abdominal cavity. Rupture of gallbladder mucoceles may cause atypical bile peritonitis in which mucinous material is observed instead of bile pigment.

**Key words :** white bile, dog, peritonitis, gallbladder, mucocele.

### Introduction

Gallbladder mucocele is an extrahepatic biliary disease. It has a high probability to induce a gallbladder rupture in the dog. Abdominal ultrasonography had high specificity (91.7%) and poor sensitivity (56.1%) (4). The gold standard for gallbladder rupture assessment in human is an ultrasonography (7). Also, it is accepted in small animal practice. Low sensitivity of imaging diagnosis in gallbladder rupture is covered with laboratory examination findings. Increased alkaline phosphatase (ALP) activity, bilirubin concentration, gamma-glutamyl transferase (GGT) activity, alanine aminotransferase (ALT) activity, and aspartate aminotransferase (AST) activity are significant changes in clinical biochemistry (5). Furthermore, cytology and clinical biochemistry give important findings in the abdominal fluid of gallbladder ruptured dog. Bile pigments are common in cytology of abdominal fluid. Although it showed a high possibility of diagnosis gallbladder rupture, to examine a bile acid is inevitable in case of without mucinous material and/or bile pigment in abdominal fluid.

### Case

A 12-year-old spayed female Cocker Spaniel was presented with vomiting, diarrhea, depression, and hyporexia of 3-day duration. The patient lived indoor and received a routine vaccination. Physical examination showed hyperthermia (39.2°C) and systolic heart murmur on the left apex. The result of CBC revealed leukocytosis (39,800/ $\mu$ L, reference interval [RI] 5,050-16,760/ $\mu$ L), neutrophilia (33,989/ $\mu$ L, RI 2,950-11,640/ $\mu$ L) and monocytosis (3,343/ $\mu$ L, RI 1,120/ $\mu$ L).

The serum chemistry profile showed increased activities of ALP (1,386 IU/L, RI 29-97 IU/L), ALT (210 IU/L, RI 21-102 IU/L) and GGT (34 IU/L, RI 1-10 IU/L) and increased bile acid concentration ( $> 30 \mu$ mol/L, RI 0-25  $\mu$ mol/L). A total protein was 6.3 g/dL (RI 5.4-7.1 g/dL). On abdominal ultrasonography, a space-occupying mass was found in the abdominal cavity which was craniodorsal to the urinary bladder and free fluid and edematous abdominal fat were observed. The peritoneal fluid (Fig 1) was obtained and submitted for fluid analysis. Total nuclear cell count of the peritoneal effusion was 15,880/ $\mu$ L, RBC count was 370,000/ $\mu$ L and total protein concentration was 4.2 g/dL. Smears from the concentrated fluid with centrifugation were made and stained with Wright-Giemsa solution (Fig 2).

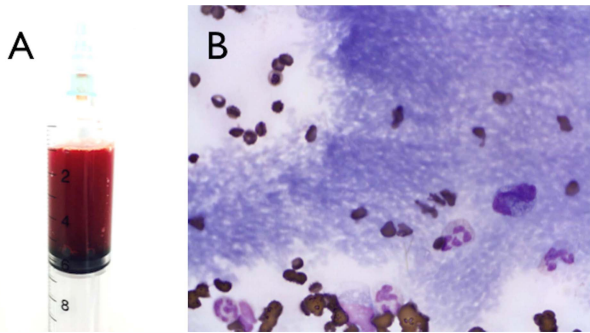
Microscopic examination on abdominal fluid revealed macrophages, degenerative neutrophils and basophilic amorphous to fibrillar materials without bile pigments or crystals. Total bilirubin concentration of the fluid was measured as 3.8 mg/dL which was 19 times higher than the serum bilirubin concentration. No bacteria was found on microscopic examination and culture test. Presence of mucinous material, absence of bile pigment and higher bilirubin concentration in peritoneal fluid than serum suggested peritonitis associated with white bile. Exploratory laparotomy revealed a ruptured gallbladder (Fig 2(A)) and the masses of mucocele (Fig 2(B)) were found in the middle of abdominal cavity apart from the gallbladder.

They were removed and abdominal cavity was lavaged with warmed sterile saline. Total bilirubin concentration of abdominal fluid on the day after surgery was 0.1 mg/dL and the patient was discharged 10 days after surgery.

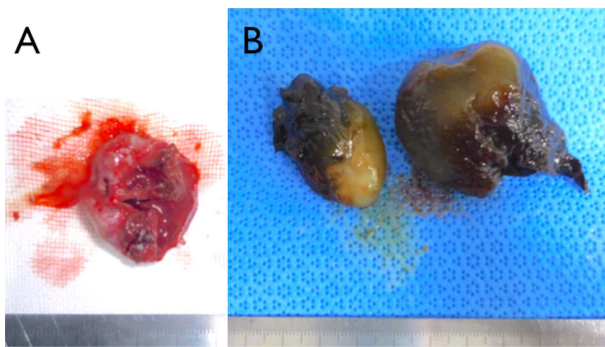
### Discussion

Bile peritonitis is an inflammatory condition of peritoneal

<sup>1</sup>Corresponding author.  
E-mail : sigol@cbnu.ac.kr



**Fig 1.** (A) Appearance of abdominal fluid. (B) Microscopic appearance of concentrated peritoneal fluid. Diff-Quik.  $\times 100$  objective.



**Fig 2.** (A) Ruptured gallbladder (B) Masses of mucocele.

cavity resulted from leakage of bile from damaged bile duct or gallbladder (2). Damage of biliary tract may be derived from abdominal trauma, surgical procedure, necrotizing cholecystitis, cholelithiasis, neoplasia, or gallbladder mucoceles (2). The spilled bile is severe chemical irritant which induces pyogranulomatous inflammation in abdominal cavity (8). The typical characteristic of bilious effusion on cytology is gold or green to blue-black bile material in the cytoplasm or background (2,8). However, exception of this finding in bile peritonitis has been reported as “white bile” (6).

White bile is defined as colorless fluid, which is occasionally associated with obstruction of biliary tract and itself has low bilirubin concentration and no bile pigments (3). It is produced when the gallbladder is excluded from obstructed biliary tract or the gallbladder has dysfunction (3). Rupture of gallbladder mucocele may cause atypical bile peritonitis in which mucinous material is observed instead of bile pigment (8).

Observation of mucinous material on cytology of peritoneal effusion is uncommon. Causes of mucinous material in abdominal cavity include white bile peritonitis (6) and pseudomyxoma peritonei (1). Since the latter condition is rare in

dogs, if mucin-producing tumors are ruled out, white bile peritonitis should be considered as differential diagnosis when basophilic mucinous material is found on cytology of peritoneal fluid.

## Conclusions

In conclusion, it is assumed that presence of mucinous material and pyogranulomatous inflammation on effusion cytology and elevated serum ALP and GGT suggest bile peritonitis in spite of absence of bile pigment. In this situation, higher bilirubin concentration in peritoneal fluid more than twice compared with serum confirms diagnosis of bile peritonitis and indicates prompt surgical intervention although rare cases showed not high bilirubin concentration.

## Acknowledgements

This work was supported by the National Research Foundation of Korea (NRF) grant funded by the Korea government (NRF-2016R1D1A1B03932312).

## References

- Bertazzolo W, Roccabianca P, Crippa L, Caniatti M. Clinicopathological evidence of pseudomyxoma peritonei in a dog with intestinal mucinous adenocarcinoma. *J Am Anim Hosp Assoc* 2003; 39: 72-75.
- Center SA. Fluid accumulation disorders. In: *Small Animal Clinical Diagnosis by Laboratory Methods*. 5th ed. St. Louis, Missouri: Elsevier Saunders. 2012: 226-259.
- Hashmonai M, Kam I, Schramek A. The etiology of “white bile” in the biliary tree. *J Surg Res* 1984; 37: 479-486.
- Jaffey JA, Graham A, VanEerde E, Hostnik E, Alvarez W, Arango J, Jacobs C, DeClue AE. Gallbladder mucocele: Variables associated with outcome and the utility of ultrasonography to identify gallbladder rupture in 219 dogs (2007-2016). *J Vet Intern Med* 2018; 32: 195-200.
- Crews LJ, Feeney DA, Jessen CR, Rose ND, Matise I. Clinical, ultrasonographic, and laboratory findings associated with gallbladder disease and rupture in dogs: 45 cases (1997-2007). *J Am Vet Med Assoc* 2009; 234: 359-366.
- Owens SD, Gossett R, McElhaney MR, Christopher MM, Shelly SM. Three cases of canine bile peritonitis with mucinous material in abdominal fluid as the prominent cytologic finding. *Vet Clin Pathol* 2003; 32: 114-120.
- Sood BP, Kalra N, Gupta S, Sidhu R, Gulati M, Khandelwal N, Suri S. Role of sonography in the diagnosis of gallbladder perforation. *J Clin Ultrasound* 2002; 30: 270-274.
- Valenciano AC, Arndt AP, Rizzi TE. Effusions: Abdominal, thoracic, and pericardial. In: *Diagnostic Cytology and Hematology of the Dog and Cat*. 4th ed. St. Louis, MO: Elsevier Mosby. 2014: 244-265.