

IMAGES

Complete coverage of a tissue expander by a musculofascial pocket including the sternalis muscle during breast reconstruction

Naohiro Ishii¹, Yusuke Shimizu², Jiro Ando³,
Michiko Harao³, Masaru Takemae³, Kazuo Kishi⁴

¹Department of Plastic and Reconstructive Surgery, Tochigi Cancer Center, Tochigi; ²Department of Plastic and Reconstructive Surgery, University of the Ryukyus Hospital, Okinawa; ³Department of Breast Surgery, Tochigi Cancer Center, Tochigi; ⁴Department of Plastic and Reconstructive Surgery, Keio University, Tokyo, Japan

Correspondence: Naohiro Ishii
Department of Plastic and Reconstructive Surgery, Tochigi Cancer Center,
4-9-13, Yohann, Utsunomiya City, Tochigi 320-0834, Japan
Tel: +81-28-658-5151, Fax: +81-28-658-5669
E-mail: ishinao0916@gmail.com

Received: 31 Dec 2016 • Revised: 24 Apr 2017 • Accepted: 2 May 2017
pISSN: 2234-6163 • eISSN: 2234-6171
<https://doi.org/10.5999/aps.2017.00017>
Arch Plast Surg 2018;45:89-90



Copyright © 2018 The Korean Society of Plastic and Reconstructive Surgeons
This is an Open Access article distributed under the terms of the Creative Commons Attribution Non-Commercial License (<http://creativecommons.org/licenses/by-nc/4.0/>) which permits unrestricted non-commercial use, distribution, and reproduction in any medium, provided the original work is properly cited.

The sternalis muscle is a vestigial muscle that is vertically long with a rectangular shape, courses parallel or oblique to the long axis of the medial sternocostal part of the pectoralis major, and presents in rare cases (1.3%) [1,2]. It often has a major effect on the insertion of a tissue expander during breast reconstruction; however, there has only been a single report of the sternalis muscle and the pectoralis major muscle being elevated as a lower mastectomy flap, and no reports have been published about repairing intraoperative trauma [3].

A 66-year-old woman underwent immediate breast reconstruction using a tissue expander after total mastectomy. She had a left-sided sternalis muscle that was 3.5 cm wide and 12.0 cm long (Figs. 1, 2). In a musculofascial pocket that included the muscle, a loose adipose connection between the sternalis muscle and the pectoralis major muscle collapsed due to the textured surface of the tissue expander to form a caudal lesion that was 5.0 cm long. However, this was successfully repaired using an untied suture technique (Fig. 3).

Many plastic surgeons may be unfamiliar with the

sternalis muscle; however, they should investigate whether it is present preoperatively via imaging. The merits of the untied suture technique include the certain and safe suturing of both the sternalis muscle,

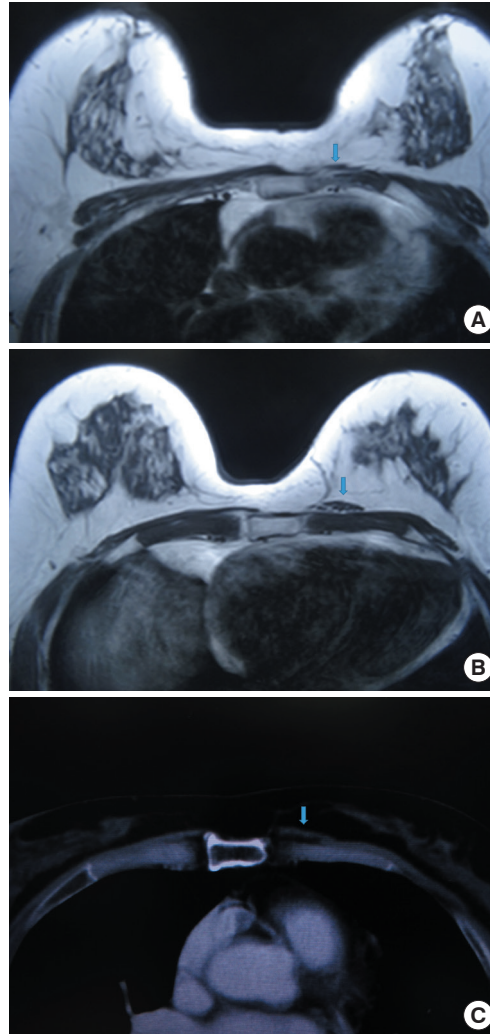


Fig. 1. Imaging analysis of the sternalis muscle. (A) Image obtained 6.0 cm distal from the origin in T1-weighted magnetic resonance imaging. (B) Image obtained 9.0 cm distal from the origin in T1-weighted magnetic resonance imaging. (C) Image obtained 8.0 cm distal from the origin in computed tomography. The blue arrow indicates the sternalis muscle.

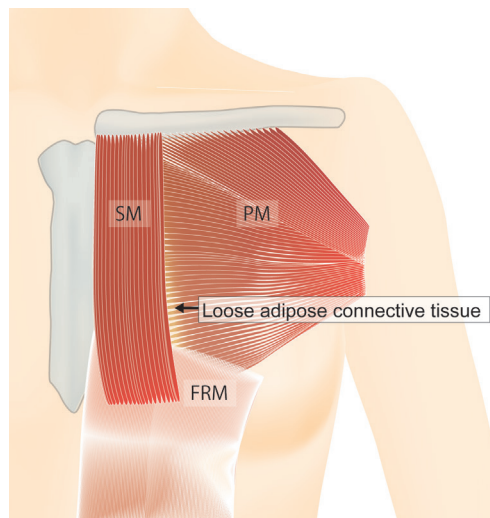


Fig. 2. Schematic depiction of the sternalis muscle. The sternalis muscle was 3.5 cm wide and 12.0 cm long, coursed adjacent to the sternum and longitudinally for 8.5 cm of its length, and then coursed slightly obliquely, running lateral to the fascia of the rectus abdominis muscle. It connected to the medial portion of the pectoralis major muscle via loose adipose connective tissue. SM, sternalis muscle; PM, pectoralis major muscle; FRM, fascia of rectus abdominis muscle.

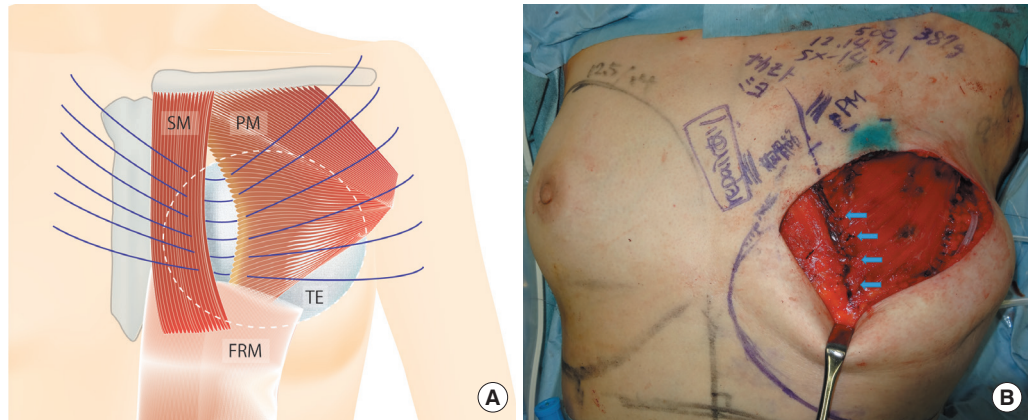


Fig. 3.

(A) Repair of the loose adipose connection. The textured surface of the tissue expander filled with saline caused the collapse of the loose adipose connection between the sternalis muscle and pectoralis major muscle, resulting in a caudal lesion that was 5.0 cm long. The tissue expander was subsequently removed and 6 untied sutures were inserted in these muscles. The SV-14 tissue expander (volume, 500 mL; height, 12 cm; width, 14 cm; projection, 7.1 cm) was made by Allergan Inc. (Santa Barbara, CA, USA). (B) Insertion of the tissue expander in the musculofascial pocket. Untied sutures were ligated carefully and both the pectoralis major muscle and the fascia of the serratus anterior muscle were sutured. The tissue expander was subsequently inserted into the musculofascial pocket. The blue arrows indicates the ligated untied sutures. SM, sternalis muscle; PM, pectoralis major muscle; FRM, fascia of rectus abdominalis muscle; TE, tissue expander.

which is often thin, and the pectoralis major muscle without damaging the tissue expander, preventing the recurrence of collapse in this area of connective tissue when inserting it after the ligation of sutures during repair. This technique may be improved by combining it with horizontal mattress sutures.

Conflict of Interest

No potential conflict of interest relevant to this article was reported.

Patient Consent

The patient provided written informed consent for the publication and the use of their images.

References

- Schulman MR, Chun JK. The conjoined sternalis-pectoralis muscle flap in immediate tissue expander reconstruction after mastectomy. *Ann Plast Surg* 2005;55:672-5.
- Barlow RN. The sternalis muscle in American whites and Negroes. *Anat Rec* 1934;61:416-26.
- Alani HA, Balalaa N. Complete tissue expander coverage by musculo-fascial flaps in immediate breast mound reconstruction after mastectomy. *J Plast Surg Hand Surg* 2013;47:399-404.

Double-sided folded internal pudendal artery perforator flap for the repair of a recurrent rectovaginal fistula

Sang Keon Lee, Yong Seok Lee, Seung Yong Song, Won Jai Lee, Dong Won Lee

Institute for Human Tissue Restoration, Department of Plastic and Reconstructive Surgery, Severance Hospital, Yonsei University College of Medicine, Seoul, Korea

Correspondence: Dong Won Lee
Department of Plastic and Reconstructive Surgery, Yonsei University College of Medicine, 50-1 Yonsei-ro, Seodaemun-gu, Seoul 03722, Korea
Tel: +82-2-2228-2215, Fax: +82-2-393-6947
E-mail: xyphoss@yuhs.ac

The authors would like to thank Dong-Su Jang, a medical illustrator in the Medical Research Support section of Yonsei University College of Medicine, Seoul, Korea, for assistance with the illustration.

Received: 7 Feb 2017 • Revised: 14 Sep 2017 • Accepted: 19 Sep 2017
pISSN: 2234-6163 • eISSN: 2234-6171
<https://doi.org/10.5999/aps.2017.00269>
Arch Plast Surg 2018;45:90-92



Copyright © 2018 The Korean Society of Plastic and Reconstructive Surgeons
This is an Open Access article distributed under the terms of the Creative Commons Attribution Non-Commercial License (<http://creativecommons.org/licenses/by-nc/4.0/>) which permits unrestricted non-commercial use, distribution, and reproduction in any medium, provided the original work is properly cited.

A 53-year-old woman underwent 3 fistulectomies performed by a colorectal surgeon due to a recurrent rectovaginal fistula (RVF), which developed 2 years after complicated labor dystocia with an episiotomy.