

A Life-Threatening Bronchogenic Cyst

Sung Joon Han, M.D., Hyun Jin Cho, M.D., Ph.D., Min-Woong Kang, M.D., Ph.D.,
Jae Hyeon Yu, M.D., Ph.D., Myung Hoon Na, M.D., Ph.D., Shin Kwang Kang, M.D., Ph.D.

Department of Thoracic and Cardiovascular Surgery, Chungnam National University School of Medicine

A bronchogenic cyst causing cardiac tamponade is a rare condition. We report an unusual case of a bronchogenic cyst that caused cardiac tamponade. A 49-year-old female patient presented at our emergency room with complaints of palpitations and shortness of breath that had lasted for 5 days preceding the visit. Echocardiography revealed a very large cystic mass compressing the left atrium posteriorly, and a large amount of pericardial effusion caused the diastolic collapse of the ventricles. Atrial fibrillation and aggravated dyspnea were observed, and the patient's vital signs were unstable after admission. We therefore performed an emergency operation. The bronchogenic cyst was resected by thoracotomy and the patient was discharged 12 days after the operation without any complications over 5 years of follow-up.

Key words: 1. Cysts
2. Cardiac tamponade

Case report

A 49-year-old female patient was referred to Chungnam National University Hospital with anterior chest pain, palpitations, and shortness of breath that had lasted for 5 days prior to her visit. The patient had no specific medical history. The results of a complete blood count, a blood chemistry panel, and electrolyte testing were within the normal limits, and no sign of infection was observed. An electrocardiogram showed a normal sinus rhythm, and a chest X-ray showed an enlarged cardiac silhouette and mild bilateral pleural effusion. Echocardiography showed a very large cystic mass compressing the posterior wall of the left atrium, and a large amount of pericardial effusion caused a diastolic collapse of the ventricles that was consistent with cardiac tamponade. A computed tomography scan of the chest revealed a 9-cm, round, homogeneous cystic mass with well-defined

margins in the subcarinal area. The cyst compressed the left atrium, left main bronchus, and pulmonary veins, and displaced the pulmonary veins (Fig. 1A, B). An emergency right-sided thoracotomy was performed because of the sudden onset of atrial fibrillation, low blood pressure, and aggravated dyspnea. The cystic mass was located in the subcarinal area and compressed the left atrium anteriorly. After pericardiectomy and aspiration of the content of the cyst, the atrial fibrillation ceased, and the patient's blood pressure increased. The cyst was radically resected, but a part of the cyst wall remained that was densely attached to the left atrium and major vessels. There was no connection between the cyst and the pericardial cavity. The pericardial effusion was transudate, but no microorganisms were identified in the fluid. Pathological analysis showed that the mass was a bronchogenic cyst. The patient did not have any complications and was discharged 12 days following

Received: May 8, 2017, Revised: June 13, 2017, Accepted: June 13, 2017, Published online: February 5, 2018

Corresponding author: Shin Kwang Kang, Department of Thoracic and Cardiovascular Surgery, Chungnam National University Hospital, Chungnam National University School of Medicine, 282 Munhwa-ro, Jung-gu, Daejeon 35015, Korea (Tel) 82-42-280-8379 (Fax) 82-42-280-7373 (E-mail) cskkwang@gmail.com

© The Korean Society for Thoracic and Cardiovascular Surgery. 2018. All right reserved.

© This is an open access article distributed under the terms of the Creative Commons Attribution Non-Commercial License (<http://creativecommons.org/licenses/by-nc/4.0>) which permits unrestricted non-commercial use, distribution, and reproduction in any medium, provided the original work is properly cited.

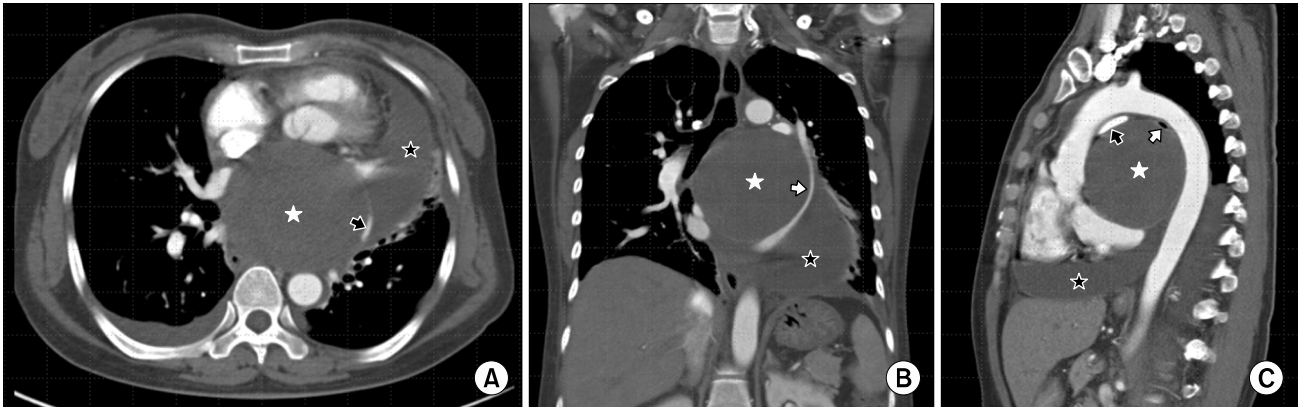


Fig. 1. (A) Computed tomography of the chest shows a very large bronchogenic cyst (white asterisk) compressing the heart and a large amount of pericardial effusion (black asterisk). The left superior pulmonary vein was compressed by a bronchogenic cyst and the distended pericardium (black arrow). (B) A coronal image shows a better view of the compressed left superior pulmonary vein (white arrow). (C) The right pulmonary artery (black arrow) and left main bronchus (white arrow) were compressed by a bronchogenic cyst and the aorta.

the operation. She had no recurrence of symptoms such as palpitations or dyspnea, and there was no recurrence of the cyst or pericardial effusion during 5 years of follow-up visits.

Discussion

Bronchogenic cysts are rare malformations that usually develop in the tracheal branches of the mediastinum or the pulmonary parenchyma. The mediastinum is the most common site of bronchogenic cysts. Most bronchogenic cysts are diagnosed incidentally because patients do not show symptoms [1]. However, they sometimes bring about life-threatening complications associated with infections, rupture, hemorrhage, and compression of the surrounding structures. Bronchogenic cysts causing cardiac tamponade are extremely rare, and most such cases occurred due to rupture of the bronchogenic cyst into the pericardium [2]. The present case showed a huge bronchogenic cyst causing compression of the left atrium and pulmonary veins, and a large amount of pericardial effusion. However, unlike previous reports, the origin of pericardial effusion was not from the ruptured bronchogenic cyst. There was no communication between the bronchogenic cyst and the pericardium, and the serous pericardial effusion was distinguished from the fluid in the cyst. We hypothesized that the pericardial effusion might have been due to hemodynamic changes caused by compression

of the left atrium and pulmonary veins.

The choice of treatment of bronchogenic cysts is surgical resection [3]. There are various surgical options, such as mediastinoscopy, video-assisted thoracoscopic surgery (VATS), or thoracotomy according to the condition of the patient [4]. A huge cyst can safely be excised by VATS after mediastinoscopic drainage [5]. In the present case, our strategy was to perform a right-sided thoracotomy because of the sudden onset of atrial fibrillation, hypotension, and the possibility of an unexpected hazardous condition. VATS can be a good surgical option for decompression and excision of the cyst because it enables a quick approach to the mass, even in a patient with a compromised cardiovascular condition. However, the surgical approach was carefully considered because of general limitations as well as considerations specific to this case, such as a thickened cystic wall, severe adhesion to the surrounding structures, and the possibility of unexpected hazardous conditions that could be caused by the pericardial effusion remaining in the cavity.

A huge bronchogenic cyst causing compression of the surrounding structures can develop into a life-threatening condition such as cardiac tamponade. Early surgical resection is a good treatment option, and the surgical approach should be determined based on a consideration of the condition of the patient, the characteristics of the mass, and the possibility of other unexpected conditions.

Conflict of interest

No potential conflict of interest relevant to this article was reported.

References

1. Kim JB, Park CK, Kum DY, Lee DH, Jung HR. *Bronchogenic cyst of the right hemidiaphragm presenting with pleural effusion*. Korean J Thorac Cardiovasc Surg 2011;44:86-8.
2. Aggarwal N, Rai A, Sedgh S, et al. *Bronchogenic cyst causing cardiac tamponade*. Am J Respir Crit Care Med 2015; 191:A3191.
3. Maturu VN, Dhooria S, Agarwal R. *Efficacy and safety of transbronchial needle aspiration in diagnosis and treatment of mediastinal bronchogenic cysts: systematic review of case reports*. J Bronchology Interv Pulmonol 2015; 22:195-203.
4. Toker A, Ayalp K, Grusina-Ujumaza J, Kaba E. *Resection of a bronchogenic cyst in the first decade of life with robotic surgery*. Interact Cardiovasc Thorac Surg 2014;19:321-3.
5. Smail H, Baste JM, Melki J, Peillon C. *Mediastinal bronchogenic cyst with acute cardiac dysfunction: two-stage surgical approach*. Ann Thorac Surg 2015;100:e79-80.