

Case Report

Colonic Angioectasia in an Adolescent Boy with Hoyeraal-Hreidarsson on Long-Term Anabolic Steroid Therapy

Racha Khalaf and Carmen Cuffari*

*Department of Pediatrics, Johns Hopkins All Children's Hospital, The Johns Hopkins University School of Medicine, St. Petersburg, FL, *Division of Pediatric Gastroenterology, The Johns Hopkins Hospital, Baltimore, MD, USA*

Androgen therapy has proven efficacy in treating patients with bone marrow failure who are not candidates for bone marrow transplantation. Herein, we report on a case of colonic angioectasia secondary to oxymetholone use in an adolescent patient with Hoyeraal-Hreidarsson syndrome (HHS). A 13-year-old Caucasian male with HHS characterized by cerebellar hypoplasia, developmental delay, microcephaly, esophageal strictures and myelodysplasia presented with severe hematochezia from colonic angioectasia secondary to long-term oxymetholone therapy. These vascular lesions resolved spontaneously once this anabolic steroid was discontinued. While androgen therapy is often recommended for certain anemias and myelodysplastic syndromes, clinicians should be aware of the potential complication in developing these perceived uncommon colonic angioectasias. Moreover, pediatric gastroenterologists should familiarize themselves in identifying these vascular lesions by colonoscopy, especially among the high risk groups on long-term anabolic steroid therapy.

Key Words: Hoyeraal-Hreidarsson syndrome, Colon, Angioectasia, Testosterone congeners

INTRODUCTION

Hoyeraal-Hreidarsson syndrome (HHS), is a rare severe variant of dyskeratosis congenita (DKC) characterized by cerebellar hypoplasia, microcephaly, myelodysplasia and immunodeficiency [1,2]. The multi-systemic nature of this genetic disorder often precludes the application of hematopoietic stem cell transplantation among those patients with bone marrow failure. In these patients, androgen therapy

has provided an evidenced base therapeutic option [3-5].

Oxymetholone is a synthetic anabolic steroid that stimulates erythropoiesis through the increased production and secretion of erythropoietin. It has proven efficacy in treating patients with myelodysplastic syndromes, including Fanconi's anemia [5]. Other studies have described a 70% success rate of oxymetholone therapy in patients with DKC [3]. Adverse effects associated with use of oxymetholone

Received : June 16, 2017, Revised : July 11, 2017, Accepted : July 15, 2017

Corresponding author: Racha Khalaf, Department of Pediatrics, Johns Hopkins All Children's Hospital, 601 Fifth Street South, Suite 608, St. Petersburg, FL 33701, USA. Tel: +1-727-767-4106, Fax: +1-727-767-8804, E-mail: rkhalaf1@jhmi.edu

Copyright © 2018 by The Korean Society of Pediatric Gastroenterology, Hepatology and Nutrition

This is an open-access article distributed under the terms of the Creative Commons Attribution Non-Commercial License (<http://creativecommons.org/licenses/by-nc/4.0/>) which permits unrestricted non-commercial use, distribution, and reproduction in any medium, provided the original work is properly cited.

include: hepatotoxicity, cholestatic jaundice which is dose and duration dependent, pelosis hepatitis, and benign and malignant hepatic tumors [6]. Oxymetholone has also been linked to decreased anticoagulant tolerance and hyperlipidemia. Other common side effects associated with the long-term use of anabolic steroids include: virilization in females, gynecomastia, amenorrhea, changes in libido and impaired thyroid function [4,6]. To our knowledge, this is the first case report in the literature attributing colonic angioectasia secondary to oxymetholone in a pediatric patient with HHS. Written informed consent was obtained from the patient for publication of this case report and accompanying images.

CASE REPORT

Our patient is a 13-year-old Caucasian male with cerebellar hypoplasia, skin dyskeratosis with hyperpigmentation, nail atrophy, esophageal strictures, urethral meatal stricture, developmental delay, and bone marrow failure who presented with hematochezia. He was initially diagnosed with developmental delay and failure to thrive as an infant. Features of DKC, and ultimate diagnosis with HHS was not made until he was about 8 years old when he presented with notable anemia, mild thrombocytopenia, and mild leukopenia. He was diagnosed with HHS based on his classical clinical features. Genetic testing was negative for mutations associated with DKC but revealed a telomere length less than the first percentile. When he was diagnosed with bone marrow failure syndrome, he was placed on a trial of androgens that notably improved his counts so that he was transfusion independent.

At age 11 years, a national shortage of androgens led to an interruption in oxymetholone therapy lasting two years. When the treatment course was resumed with 50 mg of daily oxymetholone, the patient failed to respond to therapy, at which point he was evaluated for bone marrow transplantation. He presented to an outlying facility with low grade fever, neutropenia and severe hematochezia. A flexible

sigmoidoscopy showed friable colonic tissue, and two small rectal ulcers with an overlying eschar. No biopsies were obtained secondary to the elevated risk of bleeding. In addition, no esophagogastroduodenoscopy was performed due to an esophageal stricture. Stool cultures were negative for all infectious causes of hemorrhagic colitis, including cytomegalovirus. The suspicion for inflammatory bowel disease was low.

One week thereafter, the patient developed another episode of bright red blood per rectum associated with neutropenia and fever. Upon admission to Johns Hopkins All Children's Hospital, the patient had a platelet count of $22/\mu\text{L}$, hemoglobin was 8.1 g/dL, white blood cell count was $0.72 \times 10^3/\mu\text{L}$, and the international normalized ratio was 1.2. Physical examination of the abdomen was benign. Once again, an infectious workup, including stool adenovirus, cytomegalovirus, norovirus, enterovirus, cryptosporidium, giardia, clostridium difficile, *Escherichia coli* and other bacterial stool pathogens were negative. The patient continued to have profuse hematochezia that required multiple transfusions of packed red blood cells. Bleeding was bright red would suggesting a colonic source for the bleeding.

An abdominal ultrasonography and doppler was normal. A sedated abdominal and pelvic magnetic resonance enterography was unremarkable. On colonoscopy, several large angioectasias were identified at the hepatic flexure and cecum (Fig. 1). No lesions were actively bleeding and biopsies were not obtained due to the high risk of re-bleeding. In addition, the patient had no evidence of liver cirrhosis.

Since the patient had been evaluated for bone marrow transplantation, the oxymetholone was discontinued. Interestingly, the hematochezia spontaneously resolved and the neutropenia improved. The patient was then discharged home. A follow-up colonoscopy, performed 40 days post colonoscopy showed complete resolution of the colonic angioectasias. The planned laser ablation of these angioectasias was thus aborted. Alternative therapeutic options to laser ablation include placement of endoscopic hemoclips and thermal therapy. The patient did not have any

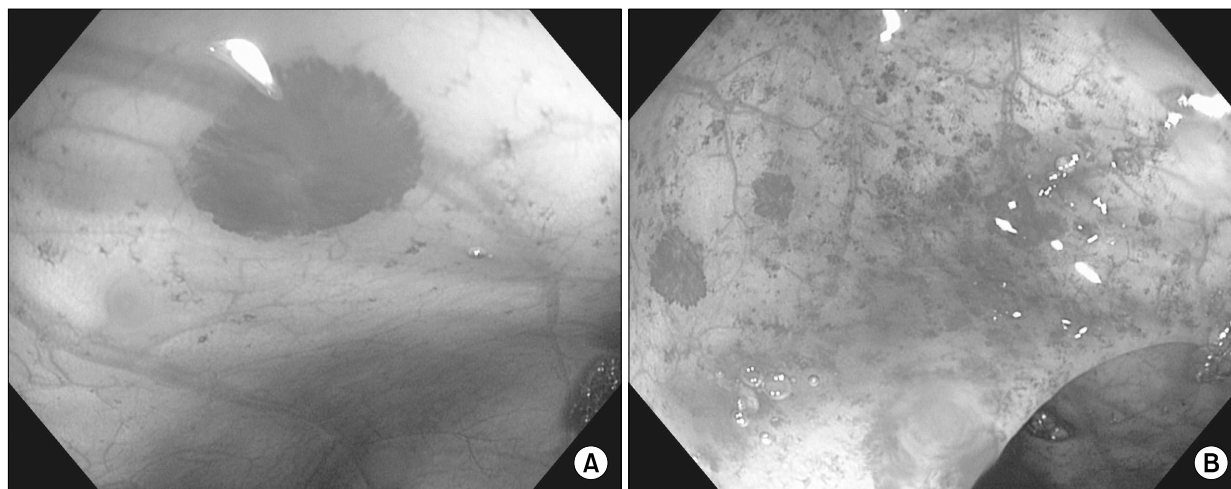


Fig. 1. (A) Angioectasia at the hepatic flexure, (B) diffuse angioectasias of the ascending colon.

further episode of hematochezia and no further intervention was indicated.

DISCUSSION

To the best of our knowledge, this is the first report of a case of colonic angioectasia secondary to oxymetholone in a pediatric patient with HHS. This genetic syndrome is unlikely to be the source of these abnormalities since the lesions disappeared spontaneously once the anabolic steroid was discontinued. A review of the literature revealed one case of colitis associated with DKC. In this case, the patient was reported to have idiopathic colitis, and portal hypertension [7]. No similar cases have been identified in patients with HHS. In our patient, the abdominal ultrasonography with Doppler did not show portal hypertension.

One study described an association between the androgen danazol and hemorrhagic cystitis. In this case series of 69 patients with angioneurotic edema, 13 had developed hematuria while on danazol therapy. In these patients, cystoscopic evaluation showed a nonspecific pattern of erythema, submucosal telangiectasia and neovascularity. Interestingly, as in our patient, these vascular lesions also spontaneously resolved once the anabolic steroid was discontinued [8]. Using the Naranjo adverse drug re-

action probability scale, the yield shows a score of 7 which is indicative of a probable association between oxymetholone and the development of angioectasia.

With the increased use of anabolic steroids to treat patients with bone marrow failure, the potential risk in developing angioectasias must be underscored. Moreover, pediatric gastroenterologists should also familiarize themselves with these vascular lesions since they are perceived as uncommon causes of intestinal bleeding in children. Further studies are needed to elucidate the pathogenesis of anabolic steroid induced angioectasia.

REFERENCES

1. Glousker G, Touzot F, Revy P, Tzfati Y, Savage SA. Unraveling the pathogenesis of Hoyeraal-Hreidarsson syndrome, a complex telomere biology disorder. *Br J Haematol* 2015;170:457-71.
2. Ohga S, Kai T, Honda K, Nakayama H, Inamitsu T, Ueda K. What are the essential symptoms in the Hoyeraal-Hreidarsson syndrome? *Eur J Pediatr* 1997; 156:80-1.
3. Islam A, Rafiq S, Kirwan M, Walne A, Cavenagh J, Vulliamy T, et al. Haematological recovery in dyskeratosis congenita patients treated with danazol. *Br J Haematol* 2013;162:854-6.
4. Khincha PP, Wentzensen IM, Giri N, Alter BP, Savage SA. Response to androgen therapy in patients with dyskeratosis congenita. *Br J Haematol* 2014;165:349-57.

5. Shimamura A, Alter BP. Pathophysiology and management of inherited bone marrow failure syndromes. *Blood Rev* 2010;24:101-22.
6. Pavlatos AM, Fultz O, Monberg MJ, Vootkur A, Pharmd. Review of oxymetholone: a 17alpha-alkylated anabolic-androgenic steroid. *Clin Ther* 2001;23:789-801; discussion 771.
7. Brown KE, Kelly TE, Myers BM. Gastrointestinal involvement in a woman with dyskeratosis congenita. *Dig Dis Sci* 1993;38:181-4.
8. Andriole GL, Brickman C, Lack EE, Sesterhenn IA, Javadpour N, Linehan WM, et al. Danazol-induced cystitis: an undescribed source of hematuria in patients with hereditary angioneurotic edema. *J Urol* 1986; 135:44-6.