

## Applications of digital subtraction angiography in the management of penetrating injuries of the maxillofacial region: A case report

Vitor José Fonseca<sup>1</sup>, Roberta Rayra Martins Chaves<sup>1</sup>, Felipe Eduardo Baires Campos<sup>1</sup>,  
Luiz Felipe Lehman<sup>1</sup>, Gustavo Meyer Moraes<sup>2</sup>, Wagner Henriques Castro<sup>1,\*</sup>

<sup>1</sup>Department of Oral and Maxillofacial Surgery, School of Dentistry, Federal University of Minas Gerais, Belo Horizonte, Minas Gerais, Brazil

<sup>2</sup>Department of Head and Neck Surgery, School of Medicine, Federal University of Minas Gerais, Belo Horizonte, Minas Gerais, Brazil

### ABSTRACT

This report presents a clinical case of trauma due to assault with a knife, and describes the importance of using the correct imaging modality in cases of facial penetrating trauma involving the superficial and deep anatomical planes. Penetrating wounds in the maxillofacial region are rare and poorly reported, but can result in serious complications that are difficult to resolve and may compromise the patient's quality of life, especially when large blood vessels or other vital structures are involved. Thus, it is essential to determine the extent of the affected blood vessels and the proximity of the retained object to the anatomical structures. In this case, digital subtraction angiography was the imaging modality chosen. The use of appropriate imaging examinations allows a proper map of the surgical field, reducing the chances of vascular damage during the surgical procedure. (*Imaging Sci Dent* 2018; 48: 295-300)

**KEY WORDS:** Wounds, Penetrating; Angiography, Digital Subtraction; Maxillofacial Injuries

Penetrating wounds in the maxillofacial region are rare and poorly reported.<sup>1,2</sup> However, they can result in serious complications that are difficult to resolve and may compromise the patient's quality of life, especially when large blood vessels or other vital structures are involved.<sup>2,4</sup>

Injuries to blood vessels may occur at the time of the trauma or during the surgical procedure to remove the penetrating foreign body, which commonly remains entrapped inside the tissue, meaning that the removal process should be planned carefully. Thus, it is essential to determine the extent of the affected blood vessels and the proximity of the retained object to the anatomical structures of the involved region.<sup>5</sup>

For these purposes, various imaging exams are useful, including computed tomography, X-ray angiography, digital subtraction angiography (DSA), computed tomography angiography (angiotomography), magnetic resonance

imaging angiography (angioresonance), and color Doppler ultrasonography.<sup>5-7</sup>

This report describes the usefulness of DSA analysis in a case of facial penetrating trauma that involved the superficial and deep anatomical planes.

### Case Report

A 47-year-old male patient presented to the Division of Maxillofacial and Traumatology Surgery of the Federal University of Minas Gerais with a history of a knife attack 3 months previously. He complained of pain in the left temporomandibular joint and limited mouth opening. His current medical condition and medical history included rheumatoid arthritis and hepatitis during childhood. Upon physical examination, a scar was observed in the left pre-auricular region, and significant limitation of the buccal opening was noted, with an interincisal distance of 13 mm. An intraoral evaluation revealed no changes in the hard or soft tissues. Computed tomography revealed the presence of a large knife fragment in the infratemporal fossa. A perforation path was observed, extending from the pre-auric-

Received June 29, 2018; Revised August 10, 2018; Accepted August 24, 2018

\*Correspondence to : Dr. Wagner Henriques Castro

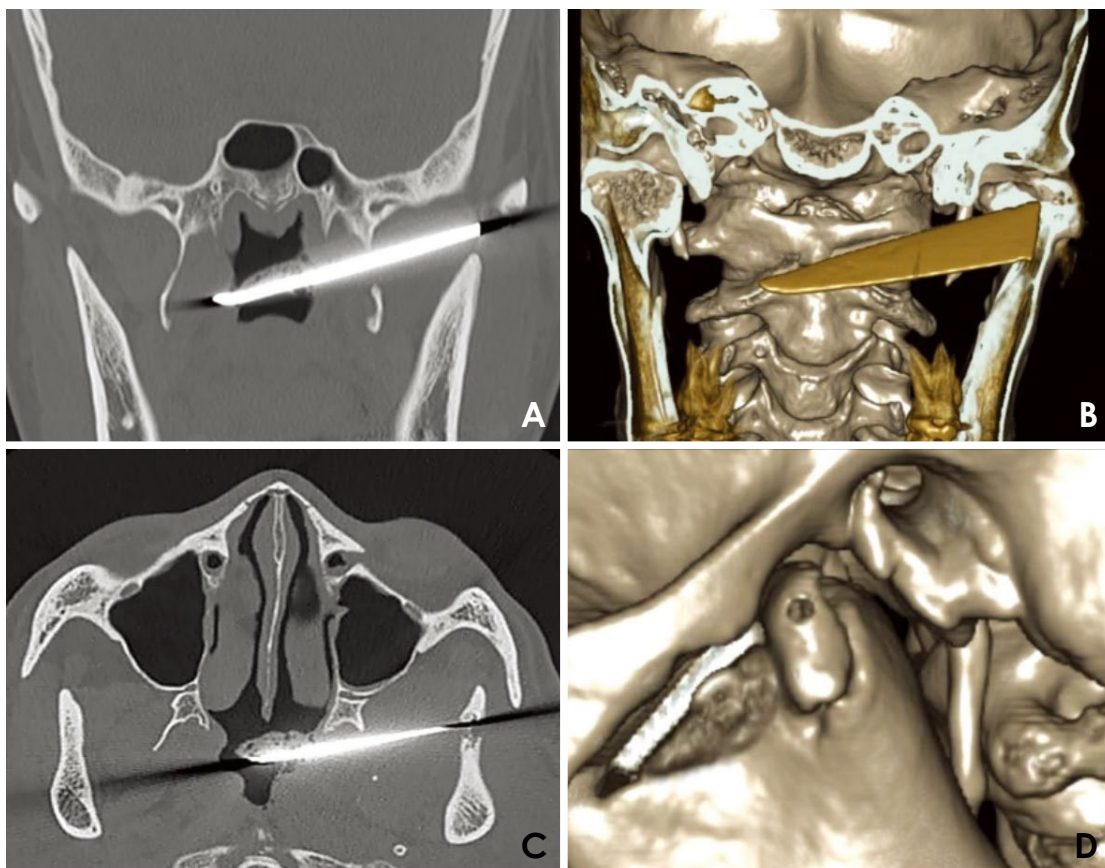
School of Dentistry, Federal University of Minas Gerais, Avenida Presidente Antônio Carlos, 6627, Belo Horizonte, Minas Gerais 31270-901, Brazil

Tel) 55-31-34092400, Fax) 55-31-34095000, E-mail) wagnerhcastro@hotmail.com

Copyright © 2018 by Korean Academy of Oral and Maxillofacial Radiology

This is an Open Access article distributed under the terms of the Creative Commons Attribution Non-Commercial License (<http://creativecommons.org/licenses/by-nc/3.0>) which permits unrestricted non-commercial use, distribution, and reproduction in any medium, provided the original work is properly cited.

Imaging Science in Dentistry · pISSN 2233-7822 eISSN 2233-7830



**Fig. 1.** Preoperative computed tomographic images. A. A coronal image shows the knife fragment in the region of the infratemporal fossa and nasopharynx. B. An axial image shows the knife fragment in the region of the infratemporal fossa and nasopharynx. C. A 3-dimensional reconstructed image reveals the knife path. D. A 3-dimensional reconstruction demonstrates the fracture of the left condylar head.

ular region to the infratemporal fossa, passing through the zygomatic arch and the sigmoid notch of the mandible until the nasopharynx (Fig. 1). An upper left condylar fracture was also observed (Fig. 1D).

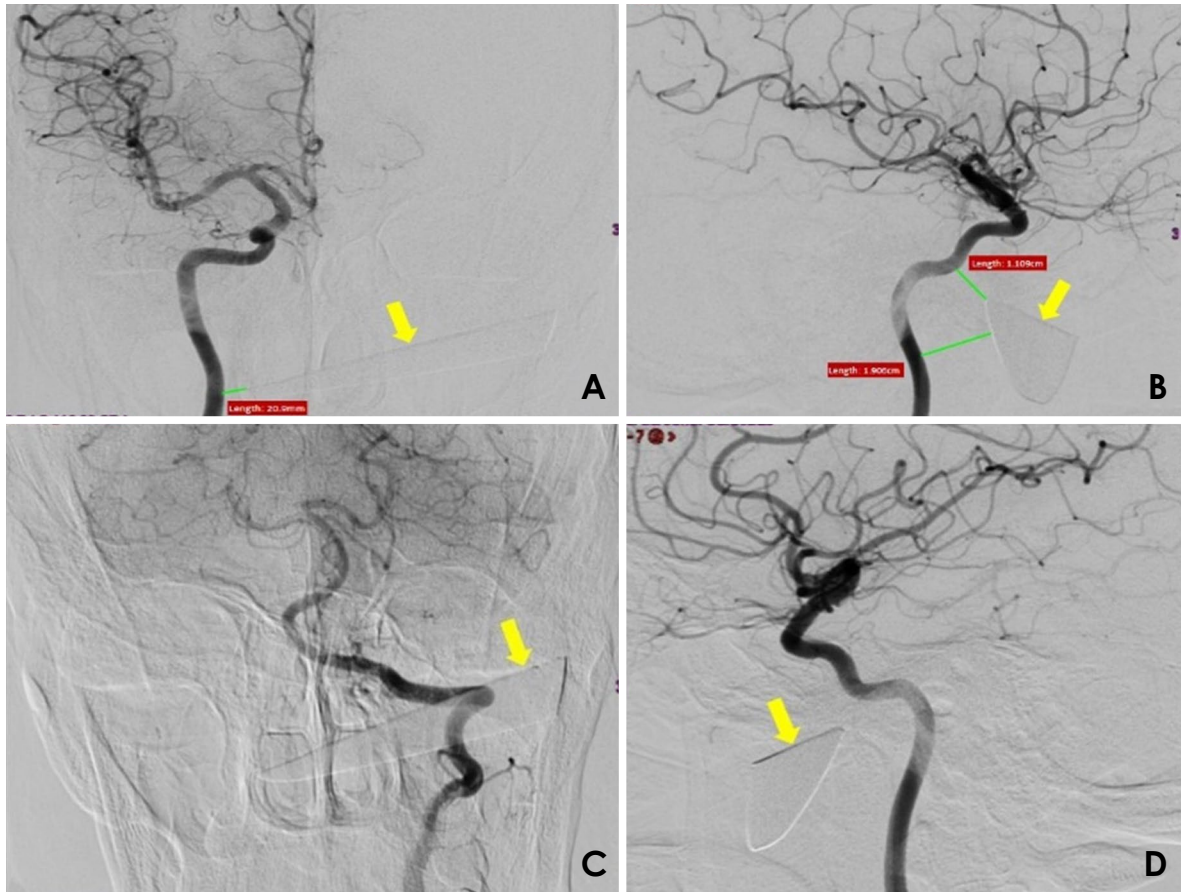
The images suggested moderate proximity of the foreign body to the internal and external carotid arteries; therefore, DSA was requested, since it is selective for the internal and external carotid arteries bilaterally (Figs. 2 and 3). DSA showed no extravasation of contrast, pseudoaneurysm, or arteriovenous fistula, suggesting that the small branches of the left external carotid artery had been transected. DSA also showed that the tip of the knife fragment had an intimate relationship with the right internal carotid artery (1.1 cm × 1.9 cm × 2.1 cm), but without any signs of extravasation. As a therapeutic plan, it was decided to surgically remove the knife, with conservative treatment of the condylar fracture. The procedure was performed jointly with the Head and Neck Surgery Service of the Federal University of Minas Gerais due to the imminent risk of involvement of large vessels during the re-

moval of the impacted blade. Under general anesthesia, extensive left pre-auricular surgical access was obtained, and after careful dissection of the facial tissues, the knife fragment was located and gently removed with the use of a needle holder (Fig. 4).

During the procedure, no intense bleeding was observed, and there was no need for vessel ligation or replacement of blood products. The patient received tetanus antitoxin and prophylactic antibiotics in the perioperative period. In the immediate postoperative period, the patient experienced complete remission of pain symptoms and recovered normal mouth opening. At 3 years after surgery, he is receiving ambulatory follow-up, and has shown a good clinical course.

## Discussion

Penetrating injuries in the maxillofacial region are uncommon;<sup>8</sup> therefore few cases in the literature have been documented.<sup>9</sup> In a review of 37 penetrating injuries involv-



**Fig. 2.** Selective digital subtraction angiography images of the internal carotid arteries show the penetrating object, indicated with yellow arrows. A. Anteroposterior view of the right internal carotid artery. B. Lateral view of the right internal carotid artery. C. Posteroanterior view of the left internal carotid artery. D. Lateral view of the carotid artery.

ing this region, only 4 were caused by a knife.<sup>10</sup>

Considering the high vascularization of the face, the successful treatment of penetrating injuries in the maxillofacial region requires accurate localization of the foreign body. Furthermore, determining the extent of the penetrating injury and its relationship with the relevant anatomical structures decreases the likelihood of severe complications, especially hemorrhage and cranial nerve damage. It is possible for these structures to be injured during the facial trauma itself or the removal process, turning it into a critical situation.<sup>5,10,11</sup>

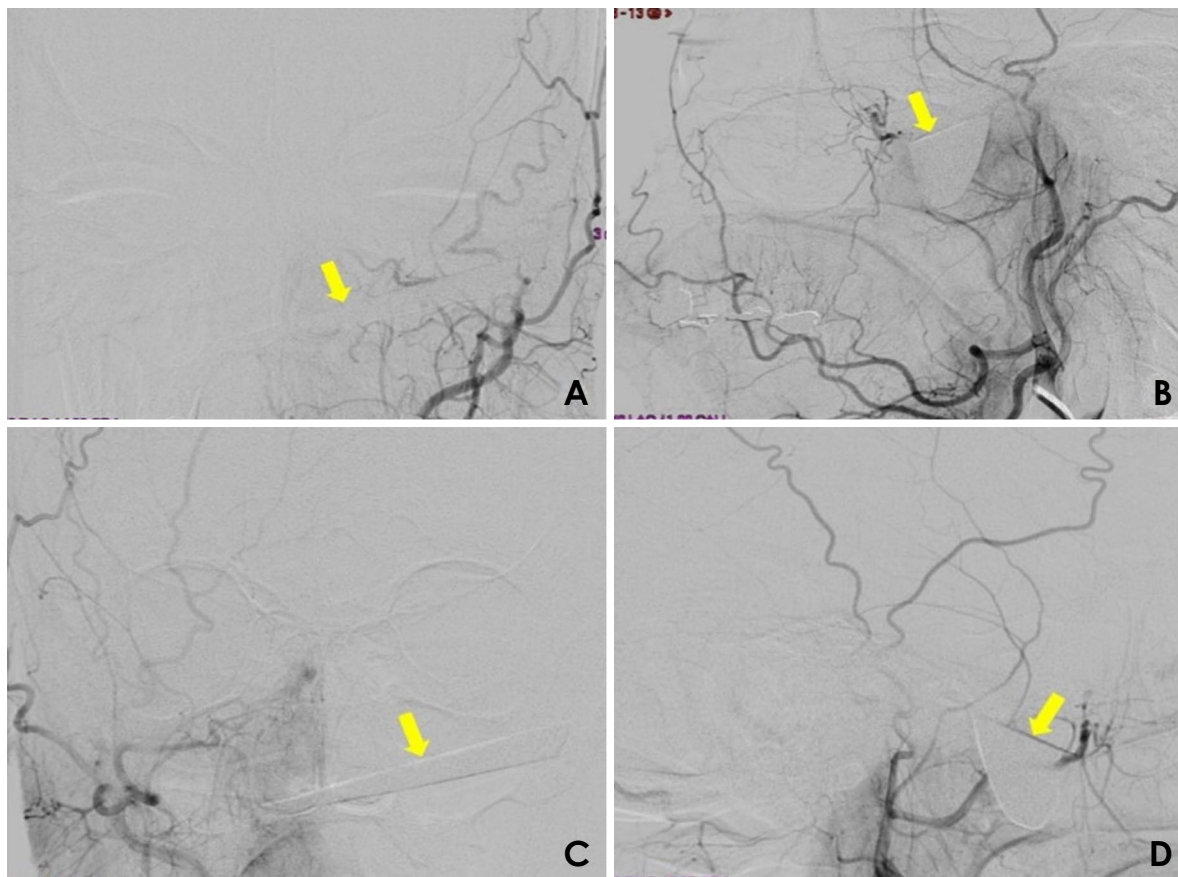
Therefore, imaging exams play a crucial role in mapping the involved region and preventing certain severe complications. The imaging modalities reported in the literature include computed tomography, conventional angiography, DSA, angiotomography, angioresonance, and color Doppler ultrasound.<sup>5-7,12</sup>

Carotid angiography is a valuable exam that allows the identification of possible anatomical alterations in the

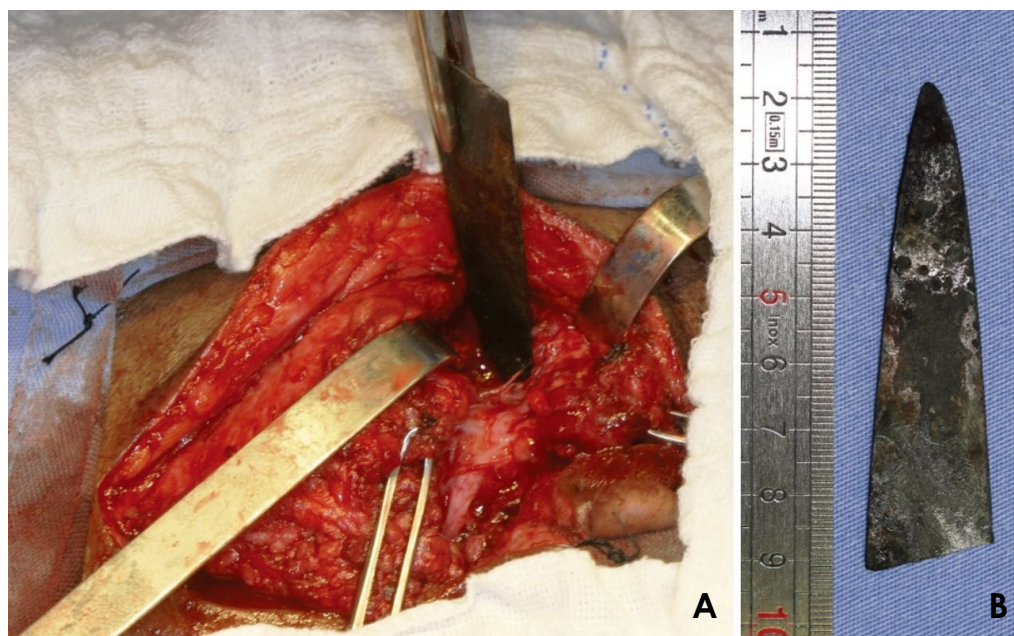
pathway of blood vessel flow in the skull, face, head and neck; however, the injection of radiopaque contrast is necessary.<sup>5-7</sup>

The use of angiography has been questioned in the literature. Some authors have argued that, even though angiography has traditionally been considered the gold standard method for identifying vascular injuries, a small rate of false positive results of this test have been reported in the literature.<sup>4,7</sup> Therefore, it has been argued that angiography should not automatically be performed in cases in which no evidence of vascular injury is observed on the physical examination and a radiographic examination does not suggest the presence of ongoing bleeding.<sup>13</sup>

However, other authors have argued that the importance of angiography, as a diagnostic tool in maxillofacial trauma, is underestimated.<sup>5</sup> They recommended the selective use of emergency angiography for patients who are victims of penetrating injuries in the maxillofacial region.<sup>3</sup> They considered angiography to be mandatory specific-



**Fig. 3.** Selective digital subtraction angiography images of the external carotid arteries show the penetrating object, indicated with yellow arrows. A. Anteroposterior view of the right external carotid artery. B. Lateral view of the right external carotid artery. C. Anteroposterior view of the left external carotid artery. D. Lateral view of the left external carotid artery.



**Fig. 4.** Surgical procedure. A. Surgical access performed to remove the penetrating object. B. The removed fragment of the knife.

ly in cases of excessive bleeding, bruising and expansion, or penetrating lacerations closer to large vessels.<sup>4</sup>

A study showed that angiography was highly reliable for the diagnosis of vascular alterations after penetrating injuries; in 31 patients who underwent angiography, the findings of preoperative angiography coincided with intraoperative findings in 26 cases. In 2 of the remaining patients, angiography underestimated the magnitude of the hemorrhage, and in 3 patients, it did not identify an existing venous lesion. Nonetheless, even in those 5 cases, angiography helped in planning and executing the surgical procedure, meaning that no higher rate of morbidity was associated with the failure of the exam.<sup>14</sup>

In cases of facial injury where the penetrating object remains in the tissues, angiography lends itself both to the investigation of possible vascular lesions related to the trauma and to establishing the proximity of the object to the larger blood vessels. This information helps prevent hemorrhage during surgical removal of the foreign body and reduces the likelihood of the formation of pseudoaneurysms, which may develop when an impacted object strikes the artery.<sup>3,5,11</sup>

Angiotomography is a reliable, sensitive, rapid, and non-invasive examination that has wide applications in the assessment of trauma involving vascular and non-vascular structures of the neck, such as the upper digestive tract and cervical spine. According to some authors, the use of this modality led to a significant reduction in negative surgical explorations.<sup>12,15</sup> However, as well as requiring another imaging examination to be conducted, angiotomography also has certain limitations, such as the possibility of image artifacts when metallic objects are present in the area under investigation.<sup>4</sup>

The imaging exams requested in this case were computed tomography and digital subtraction angiography of the carotid arteries. The left condylar fracture was demonstrated by computed tomography, while angiography revealed a close relationship between the tip of the knife and the right internal carotid artery, along with no damage of the important great blood vessels of the face and neck. A rupture of some smaller branches of the left external carotid artery was observed, and this rupture most likely occurred at the moment of trauma.

DSA was chosen because the knife could yield metal artifacts in other imaging methods (Figs. 1A and B). Such artifacts would have compromised the quality of the images and the interpretation thereof.

We suggest that selective angiography is routinely indicated in cases of deep lesions caused by a penetrating ob-

ject that is retained in the maxillofacial region, with or without vascular impairment on the physical examination. Pseudoaneurysms without a clinical manifestation can be detected using this modality, and they must be treated surgically before they rupture. In addition, when removal of the foreign body is indicated, angiography assists in planning the operation by establishing the proximity of the object to blood vessels in the region.

Fortunately, in this case, the knife did not cause important injuries upon tissue penetration, which allowed the surgical treatment to be delayed. However, the blade was fractured, leaving a large fragment lodged in the left infratemporal fossa, which caused pain and restriction of mandibular movement. This concern led us to remove the fragment under general anesthesia, since preservation of a foreign body close to vascular structures could predispose the patient to the subsequent development of pseudoaneurysms.<sup>3</sup>

Penetrating lesions in the maxillofacial region can vary significantly in terms of the affected structures and severity. Thus, a multidisciplinary therapeutic approach has been recommended by several authors.<sup>4,16</sup> Our case was conducted in partnership with the Service of Vascular Surgery and the Head and Neck Surgery Service, both of the Federal University of Minas Gerais, due to the relatively high likelihood of involvement of large vessels during surgical removal of the impacted blade.

Postoperative clinical follow-up of the patient is essential to manage possible future complications and ensure treatment success.<sup>10</sup> At 3 years after surgery, our patient did not present any type of alteration related to the injury that he had suffered.

When the removal of retained penetrating objects in the maxillofacial region is indicated, surgery should be meticulously planned. The use of specific imaging exams, such as carotid angiography by digital subtraction, enables a proper map of the surgical field to be made, reducing the chances of vascular damage during the surgical procedure.

## References

1. Carneiro JT Jr, da Silva Tabosa AK, de Souza FJ Jr, Shinohara EH. Orbitoethmoidal impacted injury by kitchen knife causing abducens nerve palsy. *J Oral Maxillofac Surg* 2011; 15: 107-8.
2. Shinohara EH, Heringer L, de Carvalho JP. Impacted knife injuries in the maxillofacial region: report of 2 cases. *J Oral Maxillofac Surg* 2001; 59: 1221-3.
3. Kreutz RW, Bear SH. Selective emergency arteriography in cases of penetrating maxillofacial trauma. *Oral Surg Oral Med Oral Pathol* 1985; 60: 18-22.

4. Meer M, Siddiqi A, Morkel JA, Janse van Rensburg P, Zafar S. Knife inflicted penetrating injuries of the maxillofacial region: a descriptive, record-based study. *Injury* 2010; 41: 77-81.
5. Scheepers A, Lownie M. The role of angiography in facial trauma: a case report. *Br J Oral Maxillofac Surg* 1994; 32: 109-10.
6. Cho SH, Lee HC, Park CW. CT angiography with 3D reconstruction for the initial evaluation of penetrating neck injury with retained knife. *Otolaryngol Head Neck Surg* 2007; 136: 504-5.
7. Múnera F, Soto JA, Palacio DM, Castañeda J, Morales C, Sanabria A, et al. Penetrating neck injuries: helical CT angiography for initial evaluation. *Radiology* 2002; 224: 366-72.
8. Subburaman N, Sivabalan K, Ramachandran M, Chandrasekhar D. Impacted knife injury of the orbit, maxilla and oropharynx. *Indian J Otolaryngol Head Neck Surg* 2005; 57: 347-50.
9. Domingute PR, Matos BF, Meyer TN, Oliveira LR. Jael syndrome: removal of a knife blade impacted in the maxillofacial region under local anaesthesia. *BMJ Case Rep* 2013; 2013: pii: bcr-2013-008839.
10. Cohen MA, Boyes-Varley G. Penetrating injuries to the maxillofacial region. *J Oral Maxillofac Surg* 1986; 44: 197-202.
11. Bourguignon Filho AM, Puppim AA, Pimentel DP, Jaques PM, Borges HO, Lanes Silveira R, et al. Unusual penetrating orbit injury. *Int J Oral Maxillofac Surg* 2006; 35: 92-3.
12. Patterson BO, Holt PJ, Cleanthis M, Tai N, Carrell T, Loosemore TM, et al. Imaging vascular trauma. *Br J Surg* 2012; 99: 494-505.
13. Eddy VA. Is routine arteriography mandatory for penetrating injury to zone 1 of the neck? Zone 1 Penetrating Neck Injury Study Group. *J Trauma* 2000; 48: 208-14.
14. Hiatt JR, Busuttil RW, Wilson SE. Impact of routine arteriography on management of penetrating neck injuries. *J Vasc Surg* 1984; 1: 860-6.
15. Offiah C, Hall E. Imaging assessment of penetrating injury of the neck and face. *Insights Imaging* 2012; 3: 419-31.
16. Harris AM, Wood RE, Nortjé CJ, Grotepass F. Deliberately inflicted, penetrating injuries of the maxillofacial region (Jael's syndrome). Report of 4 cases. *J Craniomaxillofac Surg* 1988; 16: 60-3.