

# The Ross Procedure in Pediatric Patients: A 20-Year Experience of Ross Procedure in a Single Institution

Dong Woog Yoon, M.D., Ji-Hyuk Yang, M.D., Tae-Gook Jun, M.D., Pyo Won Park, M.D.

Department of Thoracic and Cardiovascular Surgery, Samsung Medical Center, Sungkyunkwan University School of Medicine

**Background:** The Ross/Ross-Konno procedure is considered a good option for irreparable aortic valve disease in pediatric patients because of its hemodynamic performance and potential for growth of the pulmonary autograft. This study is a review of the long-term results of our 20-year experience with the Ross and Ross-Konno operations in a single institution. **Methods:** Between June 1995 and January 2016, 16 consecutive patients (mean age, 6.0±5.9 years; range, 16 days to 17.4 years) underwent either a Ross operation (n=9) or a Ross-Konno operation (n=7). The study included 12 males and 4 females, with a median follow-up period of 47 months (range, 6 to 256 months). **Results:** There were no cases of in-hospital or late mortality. Six reoperations were performed in 5 patients. Four patients underwent right ventricular-pulmonary artery (RV-PA) conduit replacement. Two patients underwent concomitant replacement of the pulmonary autograft and RV-PA conduit 10 years and 8 years after the Ross operation, respectively. The rate of freedom from adverse outcomes of the pulmonary autograft was 88% and 70% at 5 and 10 years, respectively. The rate of freedom from valve-related reoperations was 79% and 63% at 5 and 10 years, respectively. **Conclusion:** Pulmonary autografts demonstrated good durability with low mortality. The Ross/Ross-Konno procedure is a good option that can be performed safely in pediatric patients with aortic valve disease, even in a small-volume center.

*Key words:* 1. Aortic valve  
2. Autografts  
3. Allografts  
4. Pediatric

## Introduction

Since Donald Ross first described the use of a patient's own pulmonary valve to replace a damaged aortic valve, the Ross and Ross-Konno procedures have become an attractive option for children and adolescents with aortic valve disease [1]. However, the usefulness of the Ross/Ross-Konno procedure remains controversial. This procedure uses the patient's own living valve with favorable hemodynamic

characteristics and shows a relatively low risk for endocarditis, involves low thrombogenicity, and allows anticoagulant therapy to be avoided. Furthermore, the autograft size increases as the child grows [2,3]. However, this procedure is a technically demanding operation, and both the autograft in the aortic position and the valve substitute in the right ventricular outflow tract (RVOT) can experience structural failure over time, compounding the problem of reoperation [4,5].

Received: September 19, 2016, Revised: November 1, 2016, Accepted: November 3, 2016, Published online: August 5, 2017

Corresponding author: Tae-Gook Jun, Department of Thoracic and Cardiovascular Surgery, Samsung Medical Center, Sungkyunkwan University School of Medicine, 81 Irwon-ro, Gangnam-gu, Seoul 06351, Korea  
(Tel) 82-2-3410-3484 (Fax) 82-2-3410-1680 (E-mail) [tgjunsmc@gmail.com](mailto:tgjunsmc@gmail.com)

© The Korean Society for Thoracic and Cardiovascular Surgery. 2017. All right reserved.

© This is an open access article distributed under the terms of the Creative Commons Attribution Non-Commercial License (<http://creativecommons.org/licenses/by-nc/4.0>) which permits unrestricted non-commercial use, distribution, and reproduction in any medium, provided the original work is properly cited.

The aim of this study was to review our 20-year single-institution experience with the Ross/Ross-Konno procedure in a population that included neonates, infants, children, and adolescents, and to describe the incidence of autograft or homograft insufficiency and the need for reoperation on the autograft or homograft.

## Methods

### 1) Patients

Between June 1995 and June 2016, 16 consecutive patients (12 males, 4 females; median age, 5.5 years; range, 16 days to 17.4 years) underwent either a Ross procedure (n=9) or a Ross-Konno procedure (n=7) performed by 3 surgeons at Samsung Medical Center, Seoul, Korea. The indications were pediatric patients who required valve replacement despite percutaneous intervention, and who could not obtain a size-matched bioprosthetic valve. A young female pediatric patient who did not want to take warfarin was also included. The median follow-up period was 47 months (range, 6 to 256 months). Follow-up was completed by 15 of 16 patients (94%), and 13 patients were followed up for longer than 1 year. Recent medical records were unavailable for 1 patient because he returned to his home country of Kazakhstan. Six patients underwent the operation at an age of 1 year or less. The indication for surgery was aortic stenosis in 5 patients (31%), aortic insufficiency in 5 patients (31%), and a combination thereof in 5 patients (31%). The underlying left ventricular outflow tract (LVOT) pathology was congenital in 15 patients (94%) and infective endocarditis in 1 patient. Nine patients (56%) were noted to have a bicuspid (n=5) or monocuspid (n=4) aortic valve. Eleven patients (69%) underwent a total of 18 interventions prior to surgery: 6 (38%) had undergone surgical valvulotomy or valvuloplasty, 7 (44%) had undergone percutaneous balloon dilatation, and 3 (19%) had undergone both procedures. The details are shown in Table 1. Patients were followed regularly by the referring cardiologists and surgeons, using echocardiography and catheter studies if needed. Data were collected from the patients' medical records, including patient charts, operative reports, and echocardiographic examinations.

Table 1. Patient demographics and preoperative characteristics (n=16)

Characteristic	Value
Male sex	12 (75)
Age at operation	5.5 yr (16 day–17.4 yr)
Neonate (< 1 mo)	1 (6)
Infant (1–3 mo)	2 (13)
Infant (3–12 mo)	3 (19)
Child (1–10 yr)	6 (38)
Adolescent (10–17 yr)	4 (25)
Surgical indication	
Aortic stenosis	5 (31)
Aortic insufficiency	5 (31)
Aortic steno-insufficiency	5 (31)
Infective endocarditis	1 (6)
Aortic valve	
Bicuspid	5 (31)
Monocuspid	4 (25)
Previous procedure	
Percutaneous balloon dilatation	7 (44)
Aortic valve repair	6 (38)
Subaortic stenosis repair	1 (6)
Interrupted aortic arch repair	3 (19)
Ventricular septal defect closure	1 (6)

Values are presented as number (%) or median (range).

### 2) Surgical approach

All patients underwent aortic root replacement with a pulmonary autograft. The Ross-Konno procedure was performed with Konno annular enlargement using a pulmonary autograft and conal septotomy, and a narrowed LVOT was opened by incising the outflow septum.

After median sternotomy, cardiopulmonary bypass with bicaval cannulation and moderate hypothermia was started in all patients. After antegrade cold crystalloid cardioplegia was infused, both coronary arteries were mobilized and excised carefully. The aortic valve and sinuses of Valsalva were removed. The patient's pulmonary valve was also removed with the right ventricular (RV) anterior wall. A Konno incision was performed in the interventricular outflow septum for the relief of LVOT obstruction (LVOTO). Fibrous and/or muscular LVOTO was trimmed. The patient's pulmonary valve (the pulmonary autograft) was located in the aortic position; the interventricular incision was closed using the RV anterior wall. Both coronary artery buttons were attached to

Table 2. Operative details and RV-PA conduit selection (n=16)

Variable	Value
Cardiopulmonary bypass (min)	
Cross-clamp time	165 (125–283)
Total pump time	229 (169–336)
Additional procedures	
Mitral valve repair	3 (19)
Coarctation repair	1 (6)
Ascending aorta augmentation	2 (13)
Tricuspid annuloplasty	3 (19)
Ventricular septal defect closure	1 (6)
Extracorporeal membrane oxygenation insertion	2 (13)
RV-PA reconstruction	
Aortic homograft	8 (50)
Original aortic homograft	7 (44)
Bicuspidalized aortic homograft	1 (6)
Pulmonary homograft	6 (38)
Original pulmonary homograft	1 (6)
Bicuspidalized pulmonary homograft	2 (13)
Composite of bicuspidalized pulmonary homograft & monocuspidalized aortic autograft	2 (13)
Composite of monocuspidalized pulmonary homograft & bicuspidalized aortic autograft	1 (6)
Trimmed aortic autograft	1 (6)
Carpentier-Edwards valved conduit	1 (6)

Values are presented as median (range) or number (%).

RV-PA, right ventricular-pulmonary artery.

the pulmonary autograft, and a distal anastomosis with the ascending aorta was performed. The RV to pulmonary artery (PA) connection was then made, mainly with the aortic homograft or PA homograft.

### 3) Operative data

The operative details are presented in Table 2. The median cross-clamp time was 173 minutes, and the median total pump time was 249 minutes. Nine patients had concomitant procedures: mitral valve repair (n=3), tricuspid annuloplasty (n=3), ascending aorta augmentation (n=2), central extracorporeal membrane oxygenation (ECMO) insertion (n=2), coarctation of aorta repair (n=1), and ventricular septal defect closure (n=1). Enlargement of the LVOT was necessary in 7 patients by means of the Ross-Konno procedure.

Regarding RV-PA conduit selection, a pulmonary homograft was the first choice in our institution. However, because of a shortage of pulmonary homograft supply, aortic homograft, bicuspidalized homograft, or a combination of homograft and autograft were also used. The details of the composites that

constituted the RV-PA connections are shown in Table 2.

### 4) Data analysis

Echocardiography was performed regularly during follow-up: before discharge, at 3–6 months and 1 year after surgery, and then annually in the absence of a significant clinical change. For each patient, echocardiographic data were collected to examine ventricular and valvular function. All data in this study are presented as median with ranges. Categorical variables are reported as numbers and percentages. Freedom from reoperation was estimated using the Kaplan-Meier method. Estimates of freedom from reoperation are expressed as percentages with 95% confidence intervals. All statistical tests were 2-sided, and p-values < 0.05 were considered to indicate statistical significance. Statistical analyses were performed using IBM SPSS ver. 22.0 (IBM Corp., Armonk, NY, USA).

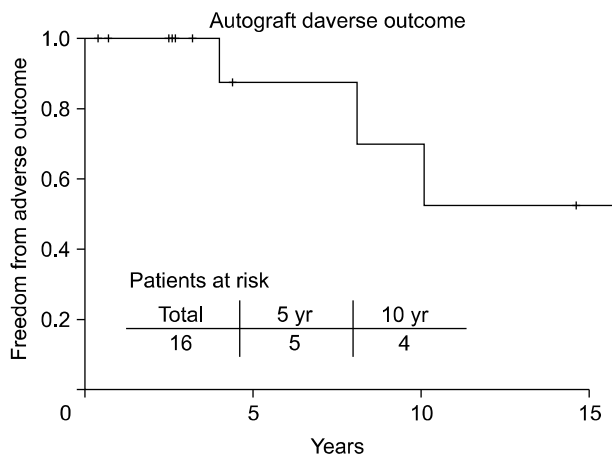


Fig. 1. Kaplan-Meier freedom from autograft adverse outcome.

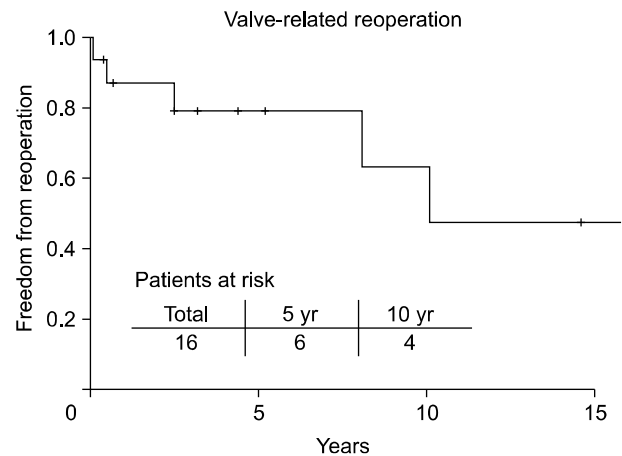


Fig. 2. Kaplan-Meier freedom from valve-related reoperation.

## Results

### 1) Morbidity and mortality

There were no cases of in-hospital mortality or late mortality. Complications developed in 4 patients. Two patients required postoperative ECMO support, because both patients underwent an urgent Ross operation due to severe aortic insufficiency after the failure of percutaneous balloon valvuloplasty and because cardiopulmonary bypass weaning was difficult. Both were successfully weaned from ECMO at 2 and 6 days postoperatively, respectively. One patient had persistent fever and leukocytosis after the Ross-Konno procedure. Mediastinitis was diagnosed by chest computed tomography, and the patient required mediastinal irrigation and debridement 13 days postoperatively. However, as the fever persisted, he required exploration 6 days after irrigation and debridement. Disruption of the RV-PA conduit due to an infection was observed, and it was necessary to change the RV-PA conduit to a new aortic homograft. Aortoplasty with a bovine pericardial patch was also performed. Another patient had postoperative bleeding that required a return to the operating room for resolution. Arrhythmias that required permanent pacemaker insertion or thrombotic events were not identified in any of the patients.

### 2) Reintervention

One patient underwent percutaneous balloon dilatation for a stenotic RV-PA conduit 10 months after the Ross procedure. This patient was 15 years old at

the time of the initial Ross procedure. One year after balloon dilatation, the patient underwent RV-PA conduit replacement.

### 3) Valve-related reoperation

The overall rate of freedom from reoperation for autograft failure was 100% and 80% at 5 and 10 years, respectively. The rate of freedom from adverse outcomes (autograft reoperation and significant regurgitation) was 88% and 70% at 5 and 10 years, respectively (Fig. 1). Two patients required reoperation on the autograft; the major underlying reason was severe aortic insufficiency. Both patients had valvular coaptation failure due to an enlarged aortic sinus, and underwent simultaneous reoperation of both the autograft and the homograft 8 and 10 years postoperatively.

One patient, who underwent autograft reoperation 10 years postoperatively, had diameter values for the neo-aortic annulus, neo-aortic sinus and ascending aorta of 26.7, 44.0, and 50.7 mm at the time of reoperation. This patient underwent a Bentall operation at the age of 27. Another patient, who underwent autograft reoperation 8 years postoperatively, had corresponding diameters of 31.2, 40.9, and 47.0 mm, respectively at the time of reoperation. This patient underwent aortic valve replacement with tissue valve at the age of 15. He requested the use of a tissue valve because of his young age and activity level, so we decided to perform an aortic valve replacement.

A dilated sinus of Valsalva with degenerated cusps

Table 3. Valve-related reoperation

Patient no.	Age at operation	Period between surgery and reoperation	Indication for reoperation	Reoperation procedures
1	17 yr	10.2 yr	AI, PS	Bentall (valvedgraft 25 mm), PVR (St. Jude Regent 23 mm)
2	7 yr	8.0 yr	AI, PS	AVR (CE PERIMOUNT 25 mm), PVR (CE valved conduit 25 mm)
3	8 yr	20 day	Infective endocarditis	PVR (aortic homograft 17 mm), LVOT reconstruction with bovine pericardial patch
		22 mo	PS	PVR (Hancock valved conduit 25 mm)
4	16 day	6 mo	PI, TI	PVR (aortic homograft 13 mm), TVP
5	14 yr	32 mo	PS	PVR (Hancock valved conduit 25 mm)

AI, aortic insufficiency; PS, pulmonary stenosis; AVR, aortic valve replacement; PVR, pulmonary valve replacement; LVOT, left ventricular outflow tract; PI, pulmonary insufficiency; TI, tricuspid valve insufficiency; TVP, tricuspid valvuloplasty.

was detected at the time of reoperation in both cases. Therefore, we performed complete aortic valve replacement in the 2 cases of reoperation on a pulmonary autograft, not a valve-sparing operation.

Six reoperations on the RV-PA conduit were performed in 5 of the 16 patients; of these, 2 patients required simultaneous reoperation of both the autograft and the homograft, as mentioned above. The indication for conduit replacement was predominant stenosis in 4 of the 6 operations. Other indications were pulmonary insufficiency and disruption due to mediastinitis. The estimated rate of freedom from valve-related reoperation was 79% and 63% at 5 and 10 years, respectively (Fig. 2). Details of the reoperations are presented in Table 3.

#### 4) Echocardiographic follow-up

At the time of the latest follow-up, left ventricular function was normal in 15 patients (94%) with an ejection fraction greater than 55% and abnormal in 1 patient (6%) with an ejection fraction of 37%. The median Z score of the neo-aortic annulus was 3.41, and that of the neo-aortic sinus was 4.48. Aortic insufficiency was absent or minimal in 7 patients, mild in 6 patients, and moderate in 1 patient. Severe aortic insufficiency was not described in any patient. Two patients who underwent autograft replacement were excluded. Neo-pulmonary insufficiency was absent or minimal in 5 patients, mild in 1 patient, and moderate or severe in 5 patients. The RVOT graft had a peak gradient less than 30 mm Hg in 3 patients, between 30 and 50 mm Hg in 7 patients, and greater than 50 mm Hg in 1 patient. Five patients who underwent reoperation on the neo-pulmonary valve were excluded. The follow-up echocardiographic

Table 4. Follow-up echocardiographic data

Measurement	Value
Neo-aortic insufficiency (n=14)	
Absent or minimal	7 (50)
Mild	6 (43)
Moderate	1 (7)
Neo-pulmonary insufficiency (n=11)	
Absent or minimal	5 (45)
Mild	1 (9)
≥Moderate	5 (45)
Right ventricular outflow tract gradient (n=11, mm Hg)	
<30	3 (27)
30–50	7 (64)
≥50	1 (9)
Z score of neo-aortic annulus	3.41
Z score of neo-aortic sinus	4.48

Values are presented as number (%) or median.

graphic data are presented in Table 4.

## Discussion

Studies in the literature have reported an early mortality rate of 0%–13% and a 10-year survival rate of 79%–98% after the Ross/Ross-Konno procedure [3,6–11]. In particular, the mortality rate has been reported to be higher in neonates and infants [7–10,12]. Fortunately, there was no mortality in our series of patients who underwent the Ross/Ross-Konno procedure. Neonatal age at the time of operation, the presence of congenital aortic arch defects, poor LV function, and preoperative severe mitral valve insufficiency have been suggested as risk factors for early mortality [11–14]. In the present study, 6 infants, including 1 neonate, were enrolled, and 3 pa-

tients had a congenital aortic arch defect. Preoperative severe mitral valve insufficiency was not identified in any patient. Improvements in postoperative management in recent years, the relatively old age of the patients, and the relatively low risk status of the patients could explain our favorable results.

Durability of the pulmonary autograft is a matter of concern in Ross/Ross-Konno operations. The rate of freedom from reoperation of the pulmonary autograft has previously been reported to be 74%–98% at 10 years in pediatric series [7,8,10,12]. Preoperative aortic insufficiency has been suggested to be a predictor of autograft failure in other reports [6,15,16]. In our study, 2 reoperations were performed, and both patients had aortic insufficiency as the indication of the original Ross procedure. The indication for reoperation was aortic insufficiency with aortic dilatation in both cases. The first patient underwent a Bentall operation because of a dilated sinus of Valsalva (44 mm) and ascending aorta (51 mm) at the age of 28. The second patient underwent aortic valve replacement with a tissue valve at the age of 15. This patient had a sinus of Valsalva measuring 40.9 mm and an ascending aorta measuring 47 mm. The estimated rate of freedom from adverse outcomes of the pulmonary autograft in our study was 88% and 70% at 5 and 10 years, respectively. Regarding the reoperation method for the pulmonary autograft, previous reports have suggested a valve-sparing operation [17] under the belief that dilatation of the neo-aortic root was the main cause of aortic insufficiency. However, David et al. [16] found abnormal cusps at reoperation that precluded aortic valve sparing in most patients. Similarly, as abnormal cusps were detected in our study, we performed complete aortic valve replacement in the 2 cases of reoperation on a pulmonary autograft.

Reoperations on the RVOT graft are common and remain a substantial drawback of the Ross/Ross-Konno procedure. Our institution prefers to use cryopreserved homografts for RVOT reconstruction in Ross/Ross-Konno operations. In this study, 14 of the 16 patients underwent RVOT reconstruction using a cryopreserved homograft; in the other 2 cases, a Carpentier-Edwards valved conduit or aortic autograft was used. Among these 14 patients, bicuspidalized homografts, which have the advantage of the availability of a small-sized valve, were applied in 3

patients. In our previous study, a size-reduced cryopreserved homograft showed a favorable outcome, which seemed to be comparable to that of an unmodified homograft of the same size [18]. A composite of bicuspidalized pulmonary homograft and aortic autograft was used in 3 patients, who are all doing well without reoperation at the time of writing. One patient, who had undergone RVOT reconstruction using an aortic autograft at 7 years of age, underwent reoperation for neo-aortic valve failure at 15 years. In the present study, the overall rate of freedom from reoperation of homografts after the Ross/Ross-Konno procedure was 79% and 63% at 5 and 10 years, respectively. In other reports, the rate of freedom from reoperation of homografts at 10 years after the Ross/Ross-Konno procedure in pediatric patients has been reported to be 56%–77% [7,8,10]. Our study, therefore, shows worse outcomes than other reports concerning pediatric patients in this regard. The inclusion of 1 patient with a very young age at the time of the Ross-Konno operation (16 days) and of 1 patient with mediastinitis at 20 days postoperatively could explain the need for early reoperation in our study. A rare potential problem is a humoral immune response to a cryopreserved homograft, resulting in early rapid stenosis [19].

The Ross/Ross-Konno procedure is a technically demanding operation. As with other complex operative procedures, a certain number of Ross procedures must be performed for surgeons to develop their expertise. In our institution, these procedures have been performed by 3 different surgeons. In the early period, between 1995 and 2003, 5 cases of the Ross procedure were performed by a single surgeon. After a gap of 8 years, 4 Ross procedures and 7 Ross-Konno procedures were performed in the last 6 years by 2 different surgeons, respectively. The reasons for the gap period were as follows. First, patients with critical aortic stenosis were rare at Samsung Medical Center during that period. Second, during that period, we changed the congenital cardiac operation team to include a new surgeon, and he needed time to build confidence with the Ross procedure. After success with the first case of the Ross procedure, we have performed Ross and Ross-Konno procedures in recent years. Third, the surgical indications have been extended to infants. In the early period, the age range at operation was 3 to 17

years. However, in recent years, we operated on 6 patients aged 1 year or younger. Although our institution has experienced limited cases of Ross or Ross-Konno procedures and the operations were performed by 3 surgeons, our mortality outcomes are not worse than those reported from larger centers. Therefore, our study results suggest that even a small-volume center can perform Ross and Ross-Konno procedures safely.

Our study has several limitations. It is retrospective and descriptive. Regarding the statistical analysis, the number of patients is too small to allow reliable estimates, and there is a gap period in our study. Surgical and perioperative techniques varied among patients. Finally, the dimensions of the neo-aortic sinus and annulus were not available for all patients.

In conclusion, the Ross/Ross-Konno procedure involves technically demanding operations with relatively high morbidity rates; however, they showed a low mortality rate in our study. Our patient series shows that Ross/Ross-Konno operations are often a suitable choice that can be performed safely, even in a small-volume center. However, a longer follow-up period is required with regard to conclusions concerning reoperation because of the gap period in our study.

### Conflict of interest

No potential conflicts of interest relevant to this article are reported.

### Acknowledgments

This study was supported by a Grant of the Samsung Vein Clinic Network (Daejeon, Anyang, Cheongju, Cheonan; Fund no. KTCS04-078).

### References

- Ross DN. Replacement of aortic and mitral valves with a pulmonary autograft. *Lancet* 1967;2:956-8.
- Al-Halees Z, Pieters F, Qadoura F, Shahid M, Al-Amri M, Al-Fadley F. The Ross procedure is the procedure of choice for congenital aortic valve disease. *J Thorac Cardiovasc Surg* 2002;123:437-41.
- Takkenberg JJ, Klieverik LM, Schoof PH, et al. The Ross procedure: a systematic review and meta-analysis. *Circulation* 2009;119:222-8.
- David TE, Omran A, Ivanov J, et al. Dilation of the pulmonary autograft after the Ross procedure. *J Thorac Cardiovasc Surg* 2000;119:210-20.
- Jonas RA. The Ross procedure is not the procedure of choice for the teenager requiring aortic valve replacement. *Semin Thorac Cardiovasc Surg Pediatr Card Surg Annu* 2005;8:176-80.
- Elkins RC, Thompson DM, Lane MM, Elkins CC, Peyton MD. Ross operation: 16-year experience. *J Thorac Cardiovasc Surg* 2008;136:623-30.
- Tan Tanny SP, Yong MS, d'Udekem Y, et al. Ross procedure in children: 17-year experience at a single institution. *J Am Heart Assoc* 2013;2:e000153.
- Brancaccio G, Polito A, Hoxha S, et al. The Ross procedure in patients aged less than 18 years: the midterm results. *J Thorac Cardiovasc Surg* 2014;147:383-8.
- Bansal N, Kumar SR, Baker CJ, Lemus R, Wells WJ, Starnes VA. Age-related outcomes of the Ross procedure over 20 years. *Ann Thorac Surg* 2015;99:2077-83.
- Nelson JS, Pasquali SK, Pratt CN, et al. Long-term survival and reintervention after the Ross procedure across the pediatric age spectrum. *Ann Thorac Surg* 2015;99:2086-94.
- Schneider AW, Bokenkamp R, Bruggemans EF, Hazekamp MG. Twenty-year experience with the Ross-Konno procedure. *Eur J Cardiothorac Surg* 2016;49:1564-70.
- Mookhoek A, Charitos EI, Hazekamp MG, et al. Ross procedure in neonates and infants: a European multicenter experience. *Ann Thorac Surg* 2015;100:2278-84.
- Lo Rito M, Davies B, Brawn WJ, et al. Comparison of the Ross/Ross-Konno aortic root in children before and after the age of 18 months. *Eur J Cardiothorac Surg* 2014;46:450-7.
- Shinkawa T, Bove EL, Hirsch JC, Devaney EJ, Ohye RG. Intermediate-term results of the Ross procedure in neonates and infants. *Ann Thorac Surg* 2010;89:1827-32.
- Laudito A, Brook MM, Suleman S, et al. The Ross procedure in children and young adults: a word of caution. *J Thorac Cardiovasc Surg* 2001;122:147-53.
- David TE, David C, Woo A, Manlhiot C. The Ross procedure: outcomes at 20 years. *J Thorac Cardiovasc Surg* 2014;147:85-93.
- Mookhoek A, de Kerchove L, El Khoury G, et al. European multicenter experience with valve-sparing reoperations after the Ross procedure. *J Thorac Cardiovasc Surg* 2015;150:1132-7.
- Yang JH, Jun TG, Sung K, Kim WS, Lee YT, Park PW. Midterm results of size-reduced cryopreserved homografts for right ventricular outflow tract reconstruction. *Ann Thorac Surg* 2010;89:1821-6.
- Rajani B, Mee RB, Ratliff NB. Evidence for rejection of homograft cardiac valves in infants. *J Thorac Cardiovasc Surg* 1998;115:111-7.