

# Early Aggressive Surgical Treatment of Multiloculated Empyema

Jong Hyun Baek, M.D., Young Uk Lee, M.D., Seok Soo Lee, M.D.,  
Jang Hoon Lee, M.D., Jung Cheul Lee, M.D., Myeong Su Kim, M.D.

*Department of Thoracic and Cardiovascular Surgery, Yeungnam University College of Medicine*

**Background:** Empyema is the collection of purulent exudate within the pleural space. Overall, 36%–65% of patients with empyema cannot be treated by medical therapy alone and require surgery. Multiloculated empyema is particularly difficult to treat with percutaneous drainage. Therefore, we describe our experiences with early aggressive surgical treatment for rapid progressive multiloculated empyema. **Methods:** From January 2001 to October 2015, we retrospectively reviewed 149 patients diagnosed with empyema who received surgery. The patients were divided into 2 groups according to whether they underwent emergency surgery or not. We then compared surgical outcomes between these groups. **Results:** The patients in group A (emergency surgery, n=102) showed a more severe infectious state, but a lower complication rate and shorter length of hospital stay. The incidence of lung abscess was higher in group A, and abscesses were associated with diabetes and severe alcoholism. **Conclusion:** Early aggressive surgical treatment resulted in good surgical outcomes for patients with rapid progressive multiloculated empyema. Furthermore, we suspect that the most likely causes of multiloculated empyema are lung abscesses found in patients with diabetes mellitus as well as severe alcoholism.

*Key words:* 1. Empyema  
2. Infection  
3. Pleural disease

## Introduction

Empyema is defined as a collection of purulent exudate within the normally sterile pleural space. The most common cause of empyema is parapneumonic effusion (approximately 66% of all cases) [1]. The natural history of the disease has been classified. The early or exudative phase (stage I) is simple fluid or pus collection. Without treatment, this will soon evolve into a loculated, fibrinopurulent effusion (stage II) complex, which is an organized collection of pus trapping the underlying lung (stage III)

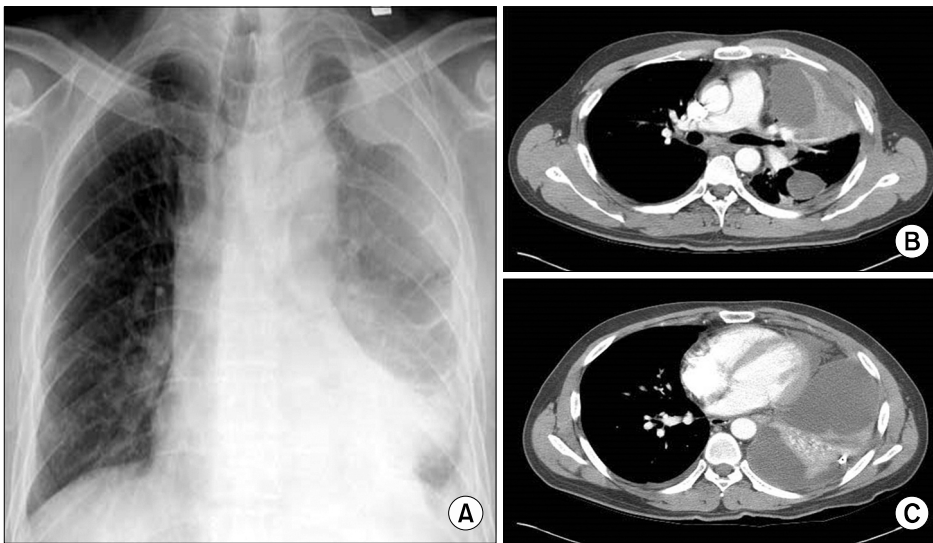
[2]. Initial medical treatment usually consists of intravenous antibiotics and drainage of the pleural cavity by needle aspiration or tube thoracostomy [3]. Nevertheless, 36% to 65% of cases are not cured with medical therapy alone and require surgery [4,5]. In particular, multiloculated empyema is difficult to treat with traditional medical intervention strategies (Fig. 1). To achieve adequate pus evacuation, more than 1 catheter may be necessary. Pleural empyema and lung abscess are both forms of lower respiratory tract infections. According to clinical observations, it is possible for both pleural empyema and lung ab-

*Received: August 31, 2016, Revised: November 4, 2016, Accepted: November 7, 2016, Published online: June 5, 2017*

*Corresponding author: Jang Hoon Lee, Department of Thoracic and Cardiovascular Surgery, Yeungnam University College of Medicine, 170 Hyeonchung-ro, Nam-gu, Daegu 42415, Korea  
(Tel) 82-53-620-3885 (Fax) 82-53-626-8660 (E-mail) [heartljh@yumail.ac.kr](mailto:heartljh@yumail.ac.kr)*

© The Korean Society for Thoracic and Cardiovascular Surgery. 2017. All right reserved.

© This is an open access article distributed under the terms of the Creative Commons Attribution Non-Commercial License (<http://creativecommons.org/licenses/by-nc/4.0>) which permits unrestricted non-commercial use, distribution, and reproduction in any medium, provided the original work is properly cited.



**Fig. 1.** Radiologic findings of multiloculated empyema. (A) Simple X-ray and (B, C) computed tomography showed multiloculated empyema. Images from one of our patients who failed percutaneous drainage treatment.

scasses to occur in the same patient [6]. In such cases of empyema with lung abscess, because of its rapid progression, there is not sufficient time to wait for the intravenous antibiotics to have an effect on the patients. This paper describes our experiences of surgery for rapidly progressive acute multiloculated empyema.

## Methods

A review of a thoracic surgical database identified 177 patients who underwent surgery for the management of acute and subacute empyema between January 2001 and October 2015. The diagnosis for all patients was based initially on a chest X-ray, followed by a computed tomography (CT) scan. Cases associated with trauma were excluded. Patients with an underlying thoracic malignancy, who had undergone pulmonary resection surgery, or who had severe neurological problems were also excluded. Indications for surgery were as follows: sudden worsening of symptoms that could not be tolerated, rapid progressive multiloculated empyema that could not be drained percutaneously, no improvement in the chest X-ray after tube thoracostomy, failure of medical treatment, existence of a definite lung lesion such as a lung abscess on the CT scan, progression to sepsis, or septic shock. We analyzed age, gender, past medical history, laboratory findings, surgical parameters, postoperative course, and surgical outcomes. All operations were performed under general anes-

thesia in the lateral decubitus position. A transverse skin incision (about 4–5 cm) was made laterally at the largest empyema cavity level, and the rib was partially resected. A thoracoscope was used for additional visibility. Pleural fluid was drained and any fibrinous debris was curetted out. Some cases required decortication. Pneumonotomy, wedge resection, or lobectomy was performed if there was a lesion on the lungs, such as a lung abscess. Copious washout of the pleural cavity was carried out using a povidone-iodine solution. One or two 28F chest drains were inserted, and the lung was reflat under direct vision. The decision to remove the drainage catheter was made when clinical symptoms improved, it was identified as having a serous nature, or drainage decreased to less than 100 mL/day. The data were analyzed using PASW SPSS statistics ver. 18.0 (SPSS Inc., Chicago, IL, USA). The independent t-test, chi-square test, Mann-Whitney test, and multivariate logistic recurrence analysis were used for statistical analysis. A p-value < 0.05 was considered statistically significant.

## Results

A total of 149 patients underwent surgery due to empyema. The demographics of the patients are outlined in Table 1. Their mean age was 50.8 years (range, 1 to 82 years), and there were 124 men and 25 women. Chest pain was the most common main complaint. All patients had a fever of up to 37.5° before surgery. The mean arterial oxygen saturation

was 92.1% (range, 21% to 99%), the mean arterial oxygen concentration was 64.1 mm Hg (range, 38 to 82 mm Hg), and the mean systemic inflammation reaction syndrome score was 2.2 (range, 0 to 4). Forty-five patients received preoperative antibiotic treatment only, and 42 patients received preoperative antibiotic treatment with tube thoracostomy. The mean preoperative treatment duration was 6.9 days. Sixty-two patients underwent surgery just after their diagnosis, without any preoperative treatment. The mean surgery time was 202 minutes. During the operation, a lung abscess was found in 92 cases. Patients with a lung abscess showed significant comorbidities. Patients in whom a lung abscess was discovered during surgery showed a significantly higher incidence of diabetes mellitus and severe alcoholism (Fig. 2). The most common operation was open drainage with

wedge resection of the lung abscess. Six patients underwent lobectomy due to having an extremely large abscess and consolidation sufficiently severe that recovery seemed impossible (Table 2). Bacterial cultures of pleural empyema were performed in all patients. However, only 21.4% of cultures (32 cases) showed positive results. The principal pathogen isolated in our series was *Streptococcus* species (Table 3). Moreover, not surprisingly, methicillin-resistant *Staphylococcus aureus* was cultured in patients with community-acquired infections. Seven patients were diagnosed with tuberculosis pleurisy. After confirmation, antituberculosis medications were initiated immediately. The mean length of the hospital stay after surgery was 19.8 days. Postoperative complications occurred in 11 cases (Table 4). Wound infection was the most common complication, and among those cases, 7 patients underwent tube thoracostomy before surgery. The number of preoperative tube thoracostomy procedures was significantly

Table 1. General characteristics of patients (n=149)

Characteristic	Value
Age (yr)	50.8±15.3
Gender (male:female)	124:25
Chief complaint	
Chest pain	80
Dyspnea	35
Cough	12
Chill	19
Other	3
Past medical history	
Diabetes mellitus	52
Tuberculosis	12
Hypertension	34

Values are presented as mean±standard deviation or number.

Table 2. Intraoperative findings

Variable	Value
Surgery time (day)	202.0±87.4
Operation site (right:left)	83:66
Presence of lung abscess	92 (61.7)
Operation	
Drainage	31 (20.8)
Drainage+pneumonotomy	36 (24.6)
Drainage+wedge resection	45 (30.2)
Lobectomy	6 (4.0)
Decortication	31 (20.8)

Values are presented as mean±standard deviation or number (%).

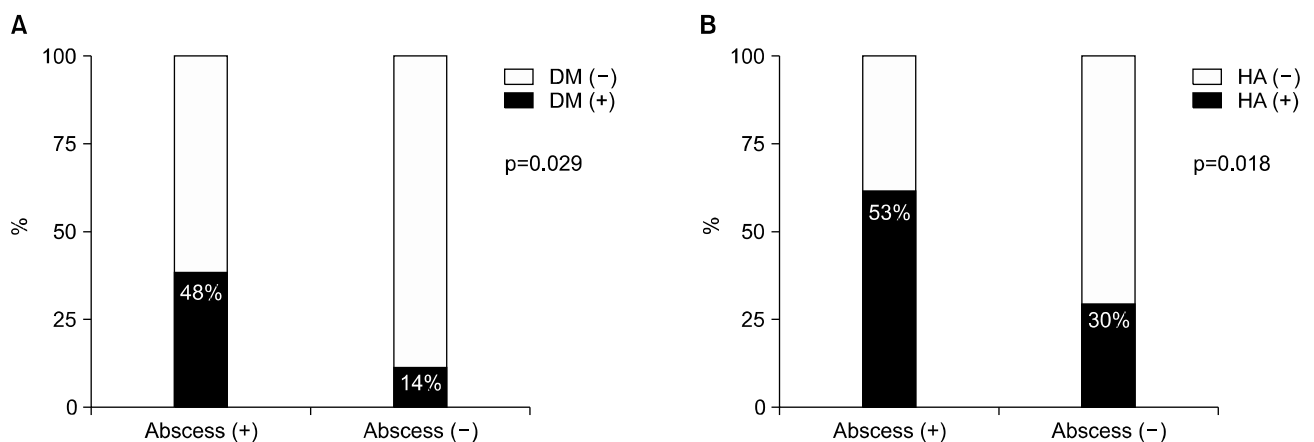


Fig. 2. Relationships between the presence of a lung abscess and comorbidities. DM, diabetes mellitus; HA, heavy alcoholism.

Table 3. Organisms identified from the pleural fluid

Organisms	No. of cases
<i>Streptococcus</i> spp.	13
<i>Staphylococcus</i> spp.	5
<i>Klebsiella</i>	3
Other	4
Tuberculosis	7

spp., species.

Table 4. Postoperative course of patients

Variable	Value
Length of hospital stay (day)	19.8±13.4
Need for ventilator care	112 (75.2)
Complications	
Wound infection	8
Pneumonia	2
Prolonged air leak	2

Values are presented as mean±standard deviation, number (%), or number.

higher in patients with complications (72% versus 36%,  $p=0.02$ ). The risk factors of postoperative complications were analyzed by multivariate logistic regression analysis (Table 5). Two patients suffered from prolonged air leakage, and it was necessary to discharge them with a drainage catheter. No in-hospital mortality occurred. Long-term outcomes were evaluated with a simple chest X-ray after 3 and 6 months. No recurrence was reported, and all patients showed satisfactory results.

## Discussion

The treatment of empyema has 2 objectives: (1) evacuation of the infected material and (2) re-expansion of the lung [7]. Therefore, empyema is usually treated with intravenous antibiotics and tube drainage. In this study, the initial antibiotic treatment was a triple antibiotic regimen. The third-generation antibiotics cephalosporin, aminoglycoside, and metronidazole are used against anaerobic bacteria. The yield of bacterial culture of pleural fluid in empyema is low with conventional laboratory methods [8-10]. In our study, only 21.4% of pleural cultures showed positive results. According to Nyambat et al. [8] in 2008, due to the low culture rate, the use of cultures in the majority of cases may not be a sufficiently

Table 5. Risk factors for postoperative complications

Risk factors	Odds ratio (confidence interval)	p-value
Age	1.060 (1.004-1.120)	0.035
Preoperative tube thoracostomy	4.406 (1.037-18.721)	0.044

sensitive diagnostic method in determining the etiology. Multiloculation implies that patients either did not receive the proper initial treatment or that further medical treatment was likely to fail [11]. Despite the proper positioning of the tube thoracostomy, it is possible for the pleural cavity to be filled with gelatinous material that cannot be drained if thoracentesis fails to adequately drain the pus. Therefore, any additional catheter insertion may not be helpful, and at this point, it is good to perform surgery within 1-2 days [12,13]. Another paper showed that tube thoracostomy for more than 7 days increases the likelihood that a staged procedure (from antibiotics to thoracotomy and decortication) will be necessary. Hence, the decision to perform surgery should be determined within a few days after initiating the drainage. The staged approach to treatment leads to an unnecessarily prolonged infective process in patients who may be debilitated by malnutrition, diabetes, or other disease processes. Moreover, prolonged use of antibiotics results in opportunistic infections [14]. Furthermore, in our study, we showed that preoperative tube thoracostomy was associated with complications such as wound infection. Therefore, it is imperative to perform surgery within an appropriate period of time and without hesitation. A lung abscess is defined as a circumscribed collection of pus in the lung, which leads to the formation of a cavity. This develops when a localized area of parenchymal infection becomes necrotic and then cavitates. Huang et al. [6] examined empyema with an abscess, and they reported that patients with pleural empyema and lung abscess have a higher intensive care unit admission rate, and higher overall mortality, than patients with pleural empyema. In our study, a lung abscess was identified in 92 patients. During the operation, we saw fresh pus leaking from the abscess, which could have led to a more rapid accumulation of pleural fluid. Therefore, physicians must pay close attention to patients

who show clinically severe features with rapid progressive multiloculated empyema, particularly with an abscess. Although we obtained satisfactory surgical outcomes, a comparison with patients who underwent only chest tube drainage or antibiotic treatment is needed to make conclusions about the efficacy of surgical treatment. To date, there have only been a few randomized controlled trials comparing surgery and tube thoracostomy as the primary intervention for empyema [13,14]. These studies showed that patients undergoing surgery as the primary management strategy had fewer treatment failures and shorter hospital stays [2]. Nevertheless, a large, multi-institute, prospective comparative study is still necessary to determine the efficacy of surgical treatment.

In conclusion, surgery played an important role in the treatment of empyema in addition to traditional medical therapy. In our study, there were 11 cases (7.4%) of postoperative complications, and no in-hospital mortality occurred. In patients with complications, more patients underwent tube thoracostomy before surgery. Therefore, if medical treatment fails, we urge that the decision to perform surgery be made without hesitation.

### Conflict of interest

No potential conflicts of interest relevant to this article are reported.

### Acknowledgments

This study was supported by a Grant of the Samsung Vein Clinic Network (Daejeon, Anyang, Cheongju, Cheonan; Fund no. KTCS04-072).

### References

1. Martella AT, Santos GH. *Decortication for chronic post-pneumonic empyema*. J Am Coll Surg 1995;180:573-6.
2. Wilson H, Mohite P, Hall A, Anikin V. *Timing and efficacy of VATS debridement in the treatment of parapneumonic empyema*. Arch Pulmonol Respir Care 2016;2:16-9.
3. Heffner JE, McDonald J, Barbieri C, Klein J. *Management of parapneumonic effusions: an analysis of physician practice patterns*. Arch Surg 1995;130:433-8.
4. Lemmer JH, Botham MJ, Orringer MB. *Modern management of adult thoracic empyema*. J Thorac Cardiovasc Surg 1985;90:849-55.
5. Varkey B, Rose HD, Kutty CP, Politis J. *Empyema thoracis during a ten-year period: analysis of 72 cases and comparison to a previous study (1952 to 1967)*. Arch Intern Med 1981;141:1771-6.
6. Huang HC, Chen HC, Fang HY, Lin YC, Wu CY, Cheng CY. *Lung abscess predicts the surgical outcome in patients with pleural empyema*. J Cardiothorac Surg 2010;5:88.
7. Bilgin M, Akcali Y, Oguzkaya F. *Benefits of early aggressive management of empyema thoracis*. ANZ J Surg 2006;76:120-2.
8. Nyambat B, Kilgore PE, Yong DE, et al. *Survey of childhood empyema in Asia: implications for detecting the unmeasured burden of culture-negative bacterial disease*. BMC Infect Dis 2008;8:90.
9. Huh JP, Lee JC, Jung TE, Lee DH, Han SS, Sun GN. *Surgical treatment of loculated empyema: closed rib resectional drainage*. Korean J Thorac Cardiovasc Surg 1998;31:1063-9.
10. Pothula V, Krellenstein DJ. *Early aggressive surgical management of parapneumonic empyemas*. Chest 1994;105:832-6.
11. Lim JS, Lee HG, Kim WG, Cho KS, Park JC, Yoo SY. *Comparative analysis between early minithoracotomy and conventional treatment for empyema*. Korean J Thorac Cardiovasc Surg 1989;22:1101-5.
12. Cham CW, Haq SM, Rahamim J. *Empyema thoracis: a problem with late referral?* Thorax 1993;48:925-7.
13. Wozniak CJ, Paull DE, Moezzi JE, et al. *Choice of first intervention is related to outcomes in the management of empyema*. Ann Thorac Surg 2009;87:1525-30.
14. Wait MA, Sharma S, Hohn J, Dal Nogare A. *A randomized trial of empyema therapy*. Chest 1997;111:1548-51.