

재건된 새 인두의 이차암에 대한 증례 보고서

강가람 · 한혜민 · 김현정 · 백승국 · 정광윤*

고려대학교 안암병원 이비인후-두경부외과

Second primary cancer in reconstructed neopharynx: a case report

Karam Kang, MD, Hye Min Han, MD, Hyunjung Kim, MD,
Seung-Kuk Baek, MD, PhD, Kwang Yoon Jung, MD, PhD*

Department of Otorhinolaryngology-Head and Neck Surgery, Korea University College of Medicine, Seoul, South Korea

= Abstract =

Background. Ever since the first report of deltopectoral flap in pharyngo-esophageal reconstruction in 1965, various methods of flap reconstruction have been introduced, allowing surgical eradication of tumors that were once thought to be inoperable. Despite these advancement, many literatures emphasize distant metastasis and second primary malignancies as the most important factors that contribute to the low 5-year survival rate of the patients. Specific consensus about defining second primary cancer is still debatable, due to small number of reports regarding second primary tumors arising in flaps used for reconstruction of defects in the head and neck region.

Case. We report a case of a 72-year-old male patient who, under the diagnosis of hypopharyngeal cancer, underwent total laryngectomy with partial pharyngectomy, extended right radical neck dissection with extended left lateral neck dissection, right hemithyroidectomy and radial forearm free flap reconstruction on June 16, 2003. After 37 cycles of radiation therapy, the patient exhibited no sign of recurrence. The patient revisited our department on June 14, 2016 with chief complaint of dysphagia that started two months before the visit. Radiologic studies and histology revealed squamous cell carcinoma in neopharynx, one that had been reconstructed with forearm free flap.

Conclusion. Until now, only a handful of reports regarding patients with second primary cancer in reconstructed flaps have been described. Despite its rarity, diagnostic criteria for second primary cancer should always kept in consideration for patients with recurred tumor.

Key Words : Recurrence, Second primary tumor

Introduction

Ever since the first report of deltopectoral flap in pharyngo-esophageal reconstruction in 1965, various methods of flap reconstruction have been introduced, allowing surgical eradication of tumors that were once thought to be inoperable.

Despite these advancement, the 5-year survival rate of patients still remain low. Many literatures emphasize both distant metastasis and second primary cancers as the most important factors that contribute to the low survival rate.¹⁾

The term relapse refers to the return of the disease after the treatment. It encases both the regrowth of tumor that are not fully eliminated by treatment, and second primary cancers where an independent carcinogenic process develops a brand new tumor.²⁾ The incidence of local recurrence does increase with stage T3 and T4 tumors in spite of previous surgery or radiotherapy.³⁾ According to study done by Yuen et al., most patients developed local recurrence after total laryngectomy within 1 year of surgery; in addi-

Received : September 28, 2017

Revised : November 3, 2017

Accepted : November 4, 2017

+Corresponding author: Kwang-Yoon Jung, M.D. Ph.D.
Department of Otorhinolaryngology-Head and Neck Surgery
Korea University Anam Hospital, 73, Incheon-ro, Seongbuk-gu,
Seoul, 02841, South Korea
Tel: 82-2-920-5486 Fax: 82-2-920-5233
E-mail: kyjungmd@gmail.com

tion, pharynx was the most common place for recurrence.¹⁾ Other studies show that the second primary cancers tend to develop in upper aero-digestive tract.³⁾ Nevertheless, only a handful of reports regarding patients with second primary cancer in reconstructed flaps have been described.

Specific consensus about defining second primary cancer is still debatable, due to small number of reports regarding second primary tumors arising in flaps used for reconstruction of defects in the head and neck region. Despite its rarity, diagnostic criteria for second primary cancer should always be kept in consideration for patients with recurred tumor.

Case

We report a case of a 72-year-old male patient who first visited Department of Otorhinolaryngology Head and Neck Surgery in Korea University Medical Center with chief complaints of sore throat and dysphagia. Under the diagnosis of hypopharyngeal cancer at stage T4aN2cM0, the patient underwent total laryngectomy with partial pharyngectomy, extended right radical neck dissection with extended left lateral neck dissection, right hemithyroidectomy, and radial forearm free flap reconstruction on June 16, 2003. Once recovered, the patient underwent 37 cycles of radiation therapy. Periodic follow ups were performed for thirteen years, and both endoscopic and radiologic examination demonstrated no recurrence of tumor.

The patient revisited our department on June 14, 2016 with chief complaint of dysphagia that started two months

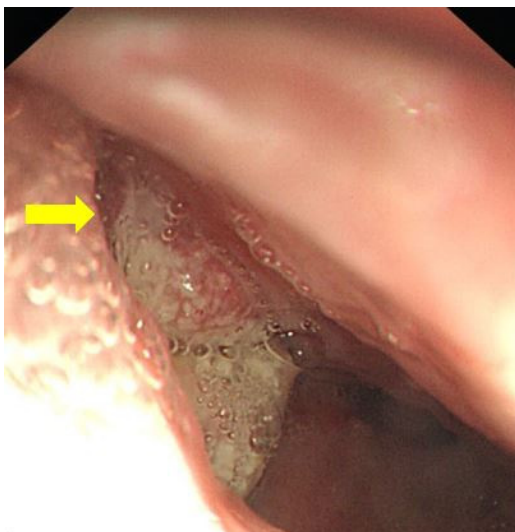


Fig. 1. Fungating mass on right neopharynx is observed from the laryngeal endoscope of the patient.

prior to the visit. No palpable mass was found upon physical examination; endoscopic examination revealed a fungating mass in right neopharynx (Fig. 1). Laryngeal CT scan showed enlarged lymph node in left level Ia; in addition, enhancing

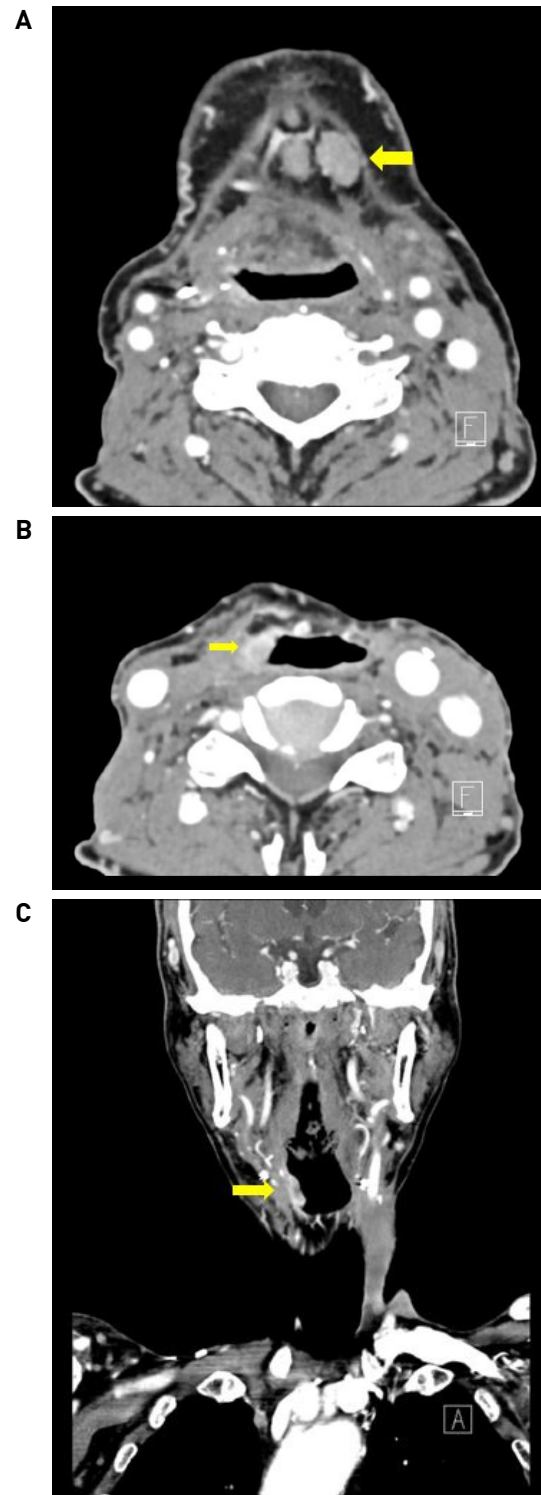


Fig. 2. Laryngeal CT taken before the surgery shows enlarged lymph node in left level Ia (A). Enhancing lesion is found from tongue base to pharyngoesophageal junction, along the lateral neopharyngeal wall (B, C).

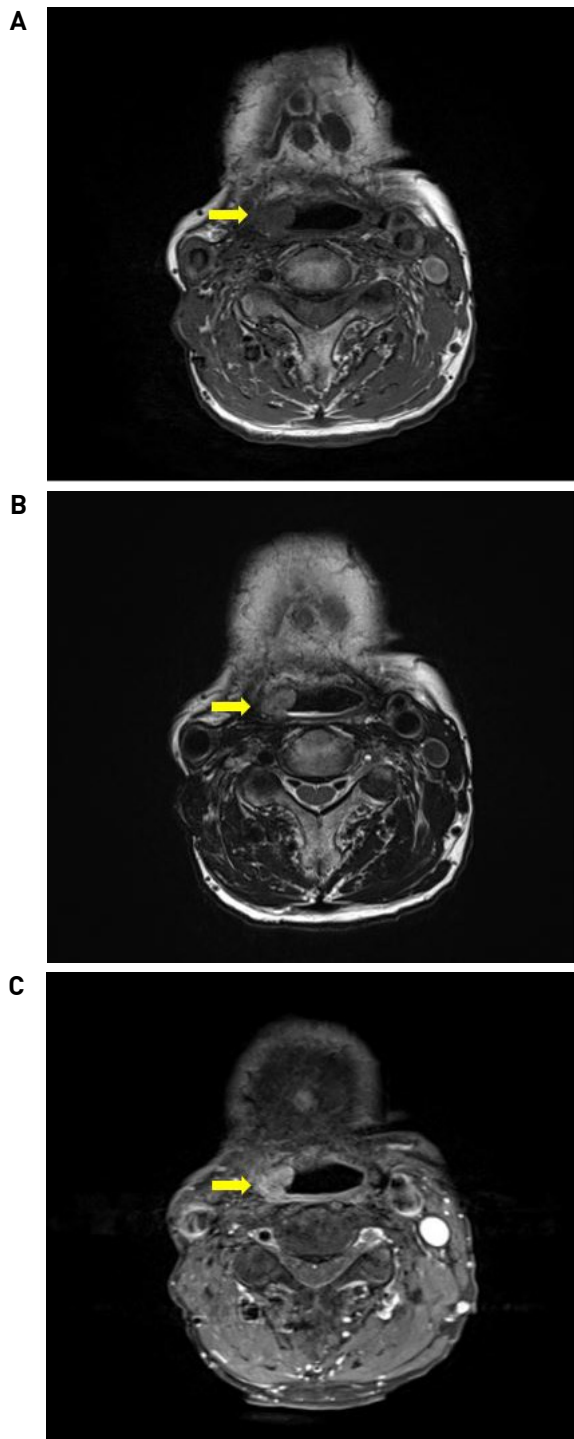


Fig. 3. Mass is found along the lateral neopharyngeal wall in both T1 (A) and T2 (B) MRI image. In T1-CE MRI image, enhancing lesion is found from tongue base to pharyngoesophageal junction (C).

lesion was found from tongue base to pharyngoesophageal junction, along the right lateral neopharyngeal wall (Fig. 2). Same finding was seen in T1 (Fig. 3A) and T2 (Fig. 3B) MRI images; mass showed enhancement in T1-CE MRI image (Fig. 3C). Biopsy was done, and the histology revealed

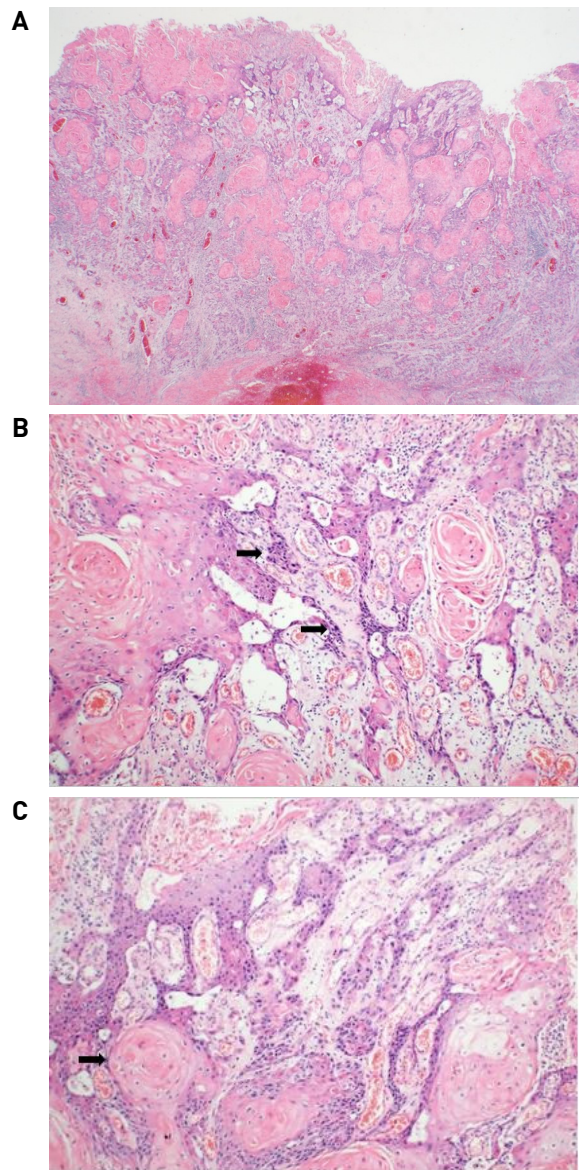


Fig. 4. Histopathology of second primary cancer shows fungating appearance and keratinization (A) (X20, HE stain). Tumor cells have enlarged, hyperchromatic nuclei with nuclear anaplasia (B) (X100, HE stain). They also exhibit squamous pearls with intercellular bridges (X200, HE stain) (C).

squamous cell carcinoma in neopharynx, one that had been reconstructed with radial forearm free flap. Under the impression of second primary cancer, the patient underwent total neopharyngectomy, total esophagectomy, bilateral selective neck dissection (level Ia), and gastric pull-up reconstruction on June 22, 2016. Final pathology confirmed well differentiated squamous cell carcinoma without lymphovascular invasion, perineural invasion, nor metastasis. The tumor exhibited fungating appearance with keratinization (Fig. 4A). Enlarged, hyperchromatic nuclei with nuclear anaplasia were found in tumor cells; moreover, inter-

cellular bridges and squamous pearls were seen (Fig. 4B, C). Periodic follow ups are ongoing, yet no signs of recurrence are seen.

Discussion

Despite advancement in both surgical and medical treatment of cancers, many literatures emphasize distant metastasis and second primary malignancies as the most important factors that contribute to the low 5-year survival rate of patients.¹⁾ The second primary cancer is defined as those that appear to be related to pre-existing cancers, but are in fact new entities arisen independently and not as a result of metastasis of the original primary cancer.³⁾ Warren et al. in 1932 first organized criteria to clinically characterize second primary tumors. Firstly, the clinical appearance must portray malignancy. Secondly, the manifestation must be at a distinct site. Thirdly, distant metastasis must be excluded. Lastly, the tumor must occur at least three years past the primary tumor manifestation.⁵⁾ Hong et al. further expanded this criteria in 1990; if the new tumor shows similar histology with the primary tumor, and is separated from the primary tumor by more than 2 cm of normal epithelium, it can be considered as the second primary tumor.⁶⁾

Only few cases regarding second primary tumors arising in flaps used for reconstruction of defects in the head and neck region are reported. Sakamoto et al. reported case of a 63 year old patient who, under the diagnosis of hypopharyngeal cancer, underwent pharyngolaryngectomy with bilateral modified radical neck dissection with left radial forearm free flap reconstruction in 1985. The patient showed no recurrence for 10 years; then in 1995, second primary cancer was found in the reconstructed pharynx. The patient received complete resection of the flap and partial oropharyngectomy, with left pectoralis major myocutaneous flap reconstruction.⁷⁾ Deans et al. reported case of a 27 year old male patient who, under the diagnosis of glottis cancer, underwent total laryngectomy, partial pharyngectomy, and delto-pectoral flap reconstruction in 1963. Periodic follows showed complete remission. However, the patient began to experience dysphagia at the age of 61, and newly developed tumor was found in reconstructed pharynx. The patient underwent excision of the neopharynx and esophagus, and gastric pull-up was performed.⁸⁾ Similar to the case presented

in this report, newly developed tumors in both patients occurred in reconstructed flaps, long after complete remission; under the impression of second primary cancer, both patients received complete resection.

Recent research shows three possible explanations for the development of second primary cancer. Firstly, the primary carcinoma may have been implanted into the flap at the time of tumor resection.⁹⁾ This theory, however, seems inappropriate in the present report since no other complications were observed during the thirteen years of disease-free follow ups. Secondly, the recurrent tumor may have been disseminated through the lymphatic system along the pedicle.¹⁰⁾ However, lymphatic system was amputated at the time of the surgery in our case, as well as in aforementioned two cases; therefore, this theory is inappropriate as well. Lastly, exposure of stimuli that skin has not experienced may have induced creation of second primary cancer. Post-operative radiation therapy, as well as exposure to saliva, food, or ingested potential carcinogens may have played an important role, and this theory is also supported by other studies.^{8,11)}

To the best of our knowledge, specific consensus about defining second primary cancer is still debatable, due to small number of reports regarding second primary tumors arising in flaps used for reconstruction of defects in the head and neck region. However, this type of complication tend to occur more often in the future with increased application of microvascular free flap transfers in reconstructive surgery for patients with head and neck cancers. Despite complete remission or length of duration after surgical treatment, second primary cancer must always be considered in patients with tumor recurrence.

중심 단어 : 재발, 이차암

References

- 1) Yuen AP, Wei WI, Hui Y. *Comprehensive analysis of pharyngeal recurrence of laryngeal carcinoma after total laryngectomy. Am J Otolaryngol* 1996;17:380-385.
- 2) Gleber-Netto F, Braakhuis B, Triantafyllou A, Takes R, Kelner N, Rodrigo J, et al. *Molecular events in relapsed oral squamous cell carcinoma: Recurrence vs. secondary primary tumor. Oral Oncol* 2015; 51:738-744.
- 3) Priante AV, Carvalho AL, Kowalski LP. *Second primary tumor in patients with upper aerodigestive tract cancer. Braz J Otorhinolaryngol* 2010;76:251-256.

- 4) Morris LG, Sikora AG, Patel SG, Hayes RB, Ganly I. *Second primary cancers after an index head and neck cancer: subsite-specific trends in the era of human papillomavirus-associated oropharyngeal cancer. J Clin Oncol 2011;29:739-746.*
- 5) Warren S, Gates O. *Multiple primary malignant tumors: A survey of the literature and statistical study. Am J Cancer 1932;16:1358-414.*
- 6) Hong WK, Lippman SM, Itri LM, Karp DD, Lee JS, Byers RM, et al. *Prevention of second primary tumors with isotretinoin in squamous-cell carcinoma of the head and neck. N Engl J Med 1990;323:795-801.*
- 7) Sakamoto M, Nibu K, Sugawara M, Nakatsuka T, Harii K, Ichimura K. *A second primary squamous cell carcinoma arising in a radial forearm flap used for reconstruction of the hypopharynx. ORL J Otorhinolaryngol Relat Spec 1998;60:170-173.*
- 8) Deans JA, Hill J, Welch AR, Soames JV. *Late development of a squamous carcinoma in a reconstructed pharynx. J Laryngol Otol 1990;104:827-828.*
- 9) Schouten JT. *Tumor implantation in a skin flap. JAMA 1983;250:2670.*
- 10) Ellison DE, Hoover LA, Ward PH. *Tumour recurrence in myocutaneous flaps. Annals of Otolology, Rhinology and Laryngology 1987;96:26-28.*
- 11) Johnson FE, Chang PK, Huvos AG, Strong EW. *Neoplastic changes in transposed deltopectoral skin. Arch Otolaryngol 1983;109:407-409.*