

성대에서 발견된 재발성 T세포 림프종에 대한 증례 보고

강가람 · 최인학 · 이도영 · 백승국 · 정광윤*

고려대학교 안암병원 이비인후과

Recurrent T-cell lymphoma occurred in the vocal fold: a case report

Karam Kang, MD, In Hak Choi, MD, Doh Young Lee, MD, PhD,
Seung-Kuk Baek, MD, PhD, Kwang Yoon Jung, MD, PhD*

Department of Otorhinolaryngology-Head and Neck Surgery, Korea University College of Medicine, Seoul, South Korea

= Abstract =

Background. Lymphoma of the vocal fold is extremely rare due to low lymphoid content in the larynx. To date, fewer than 100 cases of laryngeal lymphoma have been reported; however, none of these literatures are concerned about exclusive laryngeal involvement of recurred lymphoma which initially appeared in other body sites. Specific consensus about management for these patients yet to exist, due to its rare occurrence; however, the main modality of treatment is chemotherapy alone or in combination with radiation therapy.

Case. Herein, we report a case of a 51-year-old female patient who had recurrent T-cell lymphoma developing in bilateral vocal folds. The patient was originally diagnosed of T-cell lymphoma in right colic flexure 10 years ago, and was cured by chemotherapy. Immunohistochemical stain revealed the histologic type of recurred tumor in the vocal folds that are identical to the previously cured lymphoma.

Conclusion. To the best of our knowledge, this was the first case that recurrent lymphoma occurred solely in the vocal folds. Despite its rarity, lymphoma should be put in the index of suspicion among those patients with decreased vocal fold mucosal wave without definite vocal fold mass who had a history of cured lymphoma.

Key Words : Lymphoma, Recurrence, Vocal cord

Introduction

Lymphoma of the vocal fold is extremely rare due to low lymphoid content in the larynx. Nevertheless, lymphomas that are primary to the larynx are predominantly located in the supra-glottic region due to accumulation of follicular lymphoid tissues.¹⁾ Patients with laryngeal lymphoma often

complain of dysphagia, dysphonia, dyspnea, and cervical lymphadenopathy as main symptoms. In addition, laryngeal endoscopic examination frequently reveals non-ulcerated, polypoid submucosal supra-glottic mass; however, these findings can be diverse and non-specific.²⁾ Therefore, the diagnosis can only be made upon histological examination of a biopsy specimen.

To date, fewer than 100 cases of laryngeal lymphoma have been reported; however, none of these literatures are concerned about exclusive laryngeal involvement of recurred lymphoma which initially appeared in other body sites.³⁾ This was the first case that recurrent lymphoma occurred solely in the vocal folds. Despite its rarity, lymphoma should be put in the index of suspicion among those patients with decreased vocal fold mucosal wave without definite

Received : September 27, 2017

Revised : October 10, 2017

Accepted : October 22, 2017

+Corresponding author: Kwang Yoon Jung, M.D. Ph.D.
Department of Otorhinolaryngology-Head and Neck Surgery
Korea University Anam Hospital,
73, Incheon-ro, Seongbuk-gu, Seoul, 02841, South Korea
Tel: 82-2-920-5486 Fax: 82-2-920-5233
E-mail: kyjungmd@gmail.com

vocal fold mass who had a history of cured lymphoma.

Case

A 51-year-old female patient first visited Department of Otorhinolaryngology-Head and Neck Surgery in Korea University Medical Center on November 6, 2015, with chief complaints of voice change that began 3 months prior to the visit. The patient was originally diagnosed of T-cell lymphoma in right colic flexure in November of 1999. Since then, the patient underwent eight cycles of first line chemotherapy composed of cyclophosphamide, epirubicin, vincristine, prednisone, and bleomycin, and then six cycles of sec-

ond line chemotherapy composed of etoposide, methylprednisolone, cytarabine, and cisplatin. Through aforementioned chemotherapy, the patient achieved complete remission.

The voice change began 3 months prior to the visit as mentioned earlier. Under the laryngeal endoscope, diffuse mucosal irregularity was found (Fig. 1A, B). Stroboscopy findings showed complete glottis closure with absence of mucosal wave. The patient underwent laryngomicrosurgery for laryngeal biopsy on November 11, 2015. The laryngeal CT taken after the laryngomicrosurgery revealed mucosal surface irregularity and enhancing wall thickening in both vocal cords and subglottic space (Fig. 2A). In addition, narrowing of glottis lumen was observed (Fig. 2B).

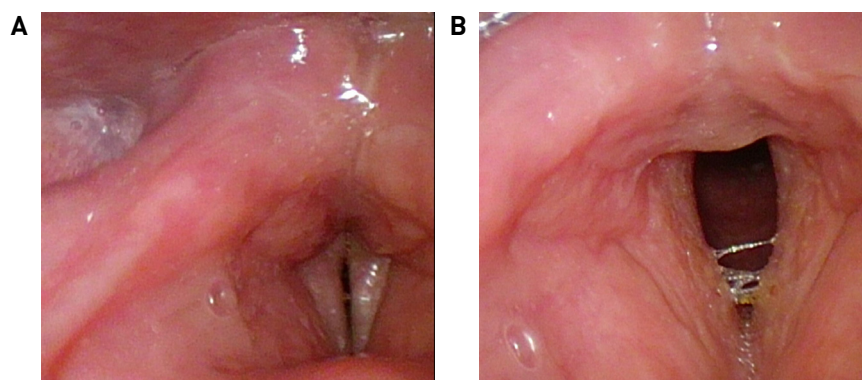


Fig. 1. (A, B) Initial laryngeal endoscope of the patient's vocal cord. Diffuse mucosal irregularity and absence of mucosal wave can be observed.

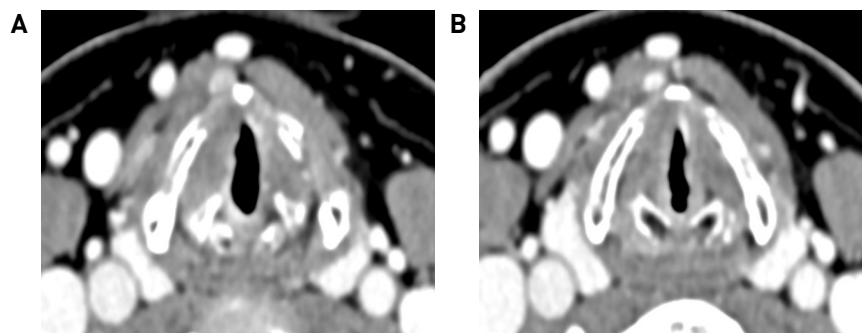


Fig. 2. (A, B) Laryngeal CT taken after the laryngomicrosurgery. (A) Mucosal surface irregularity and enhancing wall thickening in both vocal cords and subglottic space are shown. (B) Narrowing of glottic lumen can be observed.

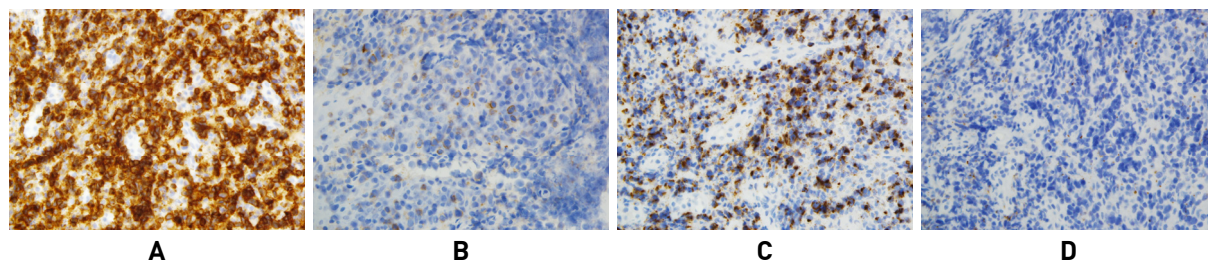


Fig. 3. (A, B, C, D) Immunohistochemical stain. (A, B, C) The tumor shows positive immunohistochemical stain for CD3, CD56, Granzyme B, respectively (X 400). The infiltrating tumor cells are monotonous and medium to large-sized, with angulated nuclei and prominent nucleoli. The tumor exhibits pleomorphism. (D) The tumor cell shows negative immunohistochemical stain for CD20 (X 400).

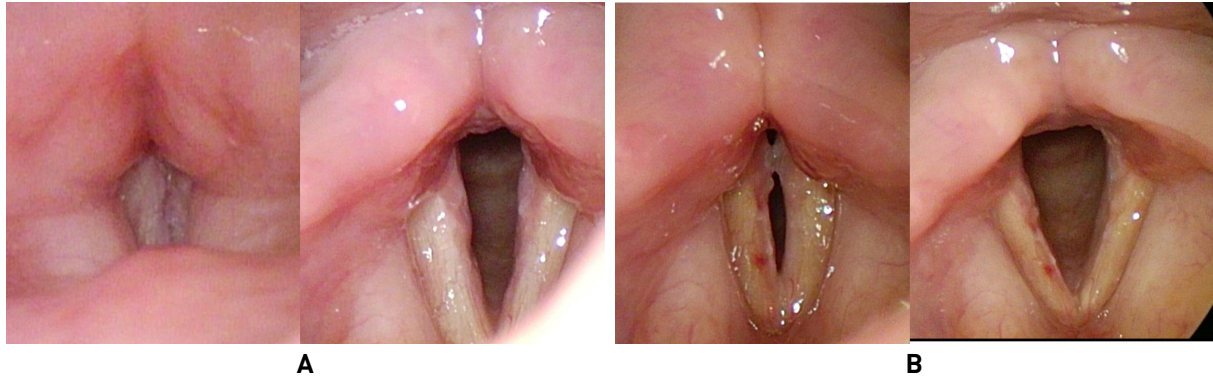


Fig. 4. (A, B) Laryngeal endoscope post chemotherapy. (A) Laryngeal endoscope of the patient's vocal cord after first cycle of third line chemotherapy, completed 30 days after the laryngomicrosurgery. (B) Laryngeal endoscope of the patient's vocal cord after second cycle of third line chemotherapy, completed 50 days after the laryngomicrosurgery.

Immunohistochemical stain revealed the histologic type of recurred tumor in the vocal folds that are identical to the previously cured lymphoma. The specimen showed positive immunohistochemical stain for CD3, CD56, Granzyme B (Fig. 3A, B, C respectively). On the other hand, the specimen showed negative immunohistochemical stain for CD20 (Fig. 3D).

Once the diagnosis was made, the patient underwent additional four cycles of third line chemotherapy of rituximab, ifosfamide, carboplatin, and etoposide. The lymphoma responded well to the treatment, as seen in both Fig. 4A and 4B, and symptoms vanished soon after.

Discussion

Lymphoid tissues undergo neoplastic transformation to produce malignant lymphomas. Extra-nodal involvement occurs in approximately 25% of cases, and is typically seen in locations that are rich with lymphoid tissues.⁴⁾ Extra-nodal lymphomas can be found in non-lymphoid tissues as well. Markou et al. reviewed cases of primary lymphomas in the larynx from 1996 to 2008 and reported that majority of the lymphomas were found in supra-glottic area; glottis was in second, and the rest were found in either subglottic or trans-glottic regions.²⁾ Nevertheless, the vocal fold is extremely rare anatomical location for lymphomas to occur, due to low lymphoid content in the larynx.⁵⁾ In addition, cases of recurrent lymphoma occurring solely in the vocal folds have not been reported.

Patients with laryngeal lymphomas, both primary and recurrent, initially portray symptoms of cough, hoarseness,

dysphagia, globus sensation, stridor, or systemic signs such as fever and loss of weight.^{2,4)} Similar clinical symptoms were found in the patients of this study. However, such information is not enough for diagnosis. Due to its rarity and absence of specific clinical and gross differential criteria, laryngeal lymphomas present diagnostic challenge. Based on studies done by Horny et al., most lymphomas are initially demonstrated as non-ulcerated smooth or polypoid submucosal masses.¹⁾ Imaging modalities including CT scan and MRI can be helpful, yet histopathological examination is essential for the final diagnosis.⁶⁾ In order to confirm the lymphoid nature of the tissue, as well as to classify between B-cell or T-cell lineage, numerous antibodies are required. B-cell lymphomas are reported more frequently compared to that of T-cell lymphomas.⁷⁾ In this case, immunohistochemical stain after the laryngomicrosurgery revealed the histologic type of recurred T-cell lymphoma in the vocal folds that is identical to the previously diagnosed lymphoma. The infiltrating tumor cells were relatively monotonous and medium to large-sized, with angulated nuclei and prominent nucleoli. The tumor exhibited pleomorphism. The lymphoid cells were positive for CD3, CD56 and Granzyme B, but negative for CD20.

Newly developed non-Hodgkin's lymphoma, even after complete remission, is often assumed to be recurrence of the primary tumor.⁸⁾ However, the second primary cancer must always be kept in consideration for patients with recurred tumor. Immune suppression through chemotherapy for the primary cancer may attribute to the development of second primary cancer.⁹⁾ Study done by Libra et al. shows that histopathological findings cannot solely discriminate re-

currence from second primary cancer; diagnostic analysis using VDJ gene rearrangement can further assess clonality of lymphomas, leading to identification of recurrence.¹⁰⁾ Therefore, despite similar histological patterns, the possibility of second primary cancer cannot be excluded from suspicion in this case.

Due to its rare occurrence, consensus of treatment for laryngeal lymphoma, either primary or recurrent, has yet to be established. A number of case studies demonstrate effectiveness of radiotherapy and chemotherapy on primary laryngeal lymphomas. Moderate dose therapy seems to be enough for control, while chemotherapy is reserved for recurrent or disseminated disease.¹¹⁾ Indeed, combined treatment of radiotherapy and chemotherapy, or chemotherapy alone proved effectiveness for recurrent or disseminated cases.¹²⁾ The patient presented in this case responded well to chemotherapy; follow up laryngeal endoscope showed improvement in both voice change and vocal cord.

To the best of our knowledge, this was the first case that recurrent lymphoma occurred solely in the vocal folds. As mentioned earlier, both primary and recurrent lymphomas often develop smooth submucosal mass that give rise to symptoms such as cough, hoarseness, dysphagia, globus sensation, and stridor. On the contrary, submucosal mass may not be visualized, just like the patient of this case. Therefore, despite its rarity, lymphoma should be put in the index of suspicion among those patients with decreased vocal fold mucosal wave without definite vocal fold mass

who had a history of cured lymphoma.

중심 단어 : 림프종, 재발, 성대

References

- 1) Horny HP, Ferlito A, Carbone A. *Laryngeal lymphoma derived from mucosa-associated lymphoid tissue. Ann Otol Rhinol Laryngol.* 1996; 105:577-583.
- 2) Markou K, Goudakos J, Constantinidis J, Kostopoulos I, Vital V, Nikolaou A. *Primary laryngeal lymphoma: report of 3 cases and review of the literature. Head Neck.* 2010; 32:541-549.
- 3) Ashamalla M, Teng MS, Brody J, Demicco E, Parikh R, Dharmarajan K, et al. *A Case of a Laryngeal MALT Lymphoma in a Patient with a History of Gastric MALT. Case Rep Hematol.* 2015:109561.
- 4) Ansell SM, Habermann TM, Hoyer JD, Strickler JG, Chen MG, McDonald TJ. *Primary laryngeal lymphoma. Laryngoscope.* 1997; 107:1502-1506.
- 5) Sasai K, Yamabe H, Kokubo M, Shibata T, Oya N, Nagata Y, et al. *Head-and-neck stages I and II extranodal non-Hodgkin's lymphomas: real classification and selection for treatment modality. Int J Radiat Oncol Biol Phys.* 2000; 48:153-160.
- 6) Takayama F, Takashima S, Momose M, Arakawa K, Miyashita K, Sone S. *MR imaging of primary malignant lymphoma in the larynx. Eur Radiol.* 2001; 11:1079-1082.
- 7) Morgan K, MacLennan KA, Narula A, Bradley PJ, Morgan DA. *Non-Hodgkin's lymphoma of the larynx. Cancer.* 1989;64:1123-1127.
- 8) Cappelaere P. *Les lymphomes non hodgkiniens secondaires. Bulletin Du Cancer.* 1998; 85:217-231.
- 9) Brennan P, Sce'lo G, Hemminki K, Mellemkjaer L, Tracey E, Andersen A, et al. *Second primary cancers among 109000 cases of non-Hodgkin's lymphoma. Br J Cancer.* 2005; 93: 159-166.