

Additional Root of the Primary Maxillary Second Molar Possibly Associated with Displacement and Rotation of the Permanent Successor : Two Case Reports

Jaewon Ku, Jewoo Lee, Jiyoung Ra

Department of Pediatric Dentistry, College of Dentistry, Wonkwang University

Abstract

An additional root of the primary maxillary second molar is rarely observed. Two cases are presented herein, and we discuss a possible association between additional root of the primary maxillary second molar and displacement and rotation of the permanent successor. Investigation of crown morphology enables the detection of a potential additional root of the primary maxillary second molar, and eruption of the permanent successor needs to be examined carefully if an additional root is present. Early extraction of primary molar and space maintenance can be used as a conservative treatment if the premolar germ shows an abnormal eruption pattern.

Key words : Additional root, Primary molar, Premolar germ, Displacement, Rotation

I . Introduction

Previous studies of additional roots have been performed mainly in permanent dentition, especially in mandibular first molars¹⁻⁹⁾. In the mandibular first molar, an additional root appears mostly in the form of a distolingual root^{1,2)}. The incidence varies according to race, with a relatively higher incidence in people of Mongoloid origin than in Caucasians. The incidence of distolingual root is reportedly 11.4 - 33.1% in those of Mongoloid origin²⁻⁶⁾, and 2.2 - 4.2% in Caucasians⁶⁻⁹⁾.

There is a limited timeframe for the detection of additional roots in the primary dentition, as the roots of primary teeth are resorbed by the permanent tooth germ. Previous studies investigating additional roots in the primary dentition have mainly taken the form of case reports, and recently the research focus has been on the incidence of additional roots in primary mandibular mo-

lars. With regard to primary mandibular second molars, studies involving Korean and Chinese patients reported additional root incidence rates of 27.8% and 27.5% respectively^{2,10)}. In primary mandibular first molars, incidence rates of 9.7% and 5.0% have been reported in Korean and Taiwanese subjects respectively^{2,11)}.

With regard to primary maxillary molars, only a few case studies have been reported^{12,13)}. This report describes two cases of an additional root in the primary maxillary second molar accompanied by displacement and rotation of the permanent successor.

II . Case Reports

1. Case 1

A male patient aged 10 years and 9 months was admitted for oral examination. Displacement of the maxil-

Corresponding author : Jiyoung Ra

Department of Pediatric Dentistry, College of Dentistry, Wonkwang University, 895 Moowang-ro, Iksan, Jeollabuk-do, 54538, Korea

Tel: +82-63-850-6633 / Fax: +82-63-851-5324 / E-mail: pedojoy@wku.ac.kr

Received April 25, 2016 / Revised June 15, 2016 / Accepted June 14, 2016

※ This research was supported by Wonkwang University, in 2016.

lary right second premolar was identified via panoramic radiography (Fig. 1), and further analysis was performed via cone-beam computed tomography (CBCT). CBCT images revealed that the maxillary right second premolar was orientated horizontally in a distal direction on the palatal side of the first premolar (Fig. 2). The primary maxillary right second molar had 4 roots. The size difference between the 2 palatal roots was not significant and an additional cusp was found on the mesiopalatal side of the crown (Fig. 3).

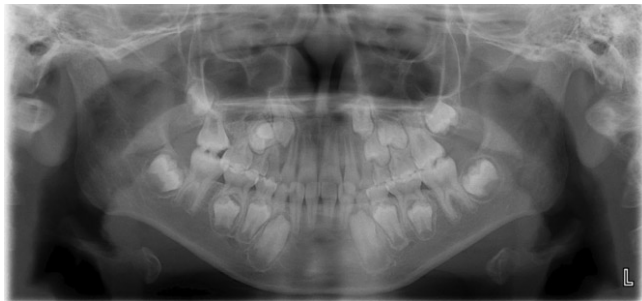


Fig. 1. Panoramic radiograph at first visit of case 1.

The primary maxillary first and second molars were extracted to accelerate the eruption of the first premolar and improve the eruption path of the second premolar. A Nance holding arch was used for space maintenance. Seventeen months after extraction, the buccal cusp tip of the second premolar emerged into the oral cavity and a fixed orthodontic appliance was placed on the upper arch. Twenty-nine months after extraction, the second premolar was aligned in the arch (Fig. 4).

2. Case 2

A male patient aged 9 years and 11 months was admitted due to swelling of the left mandibular body region. Panoramic radiography revealed that the mandibular left first premolar was horizontally impacted in the buccolingual direction below the primary first molar (Fig. 5). Radiolucency around the crown of the maxillary

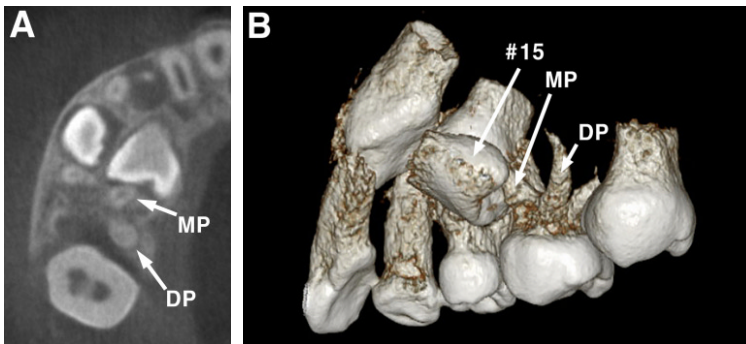


Fig. 2. CBCT view of case 1. The primary maxillary right second molar had two distinct palatal roots and the second premolar was displaced. (A) Axial view (MP: mesiopalatal root, DP: distopalatal root). (B) 3-dimensional view.

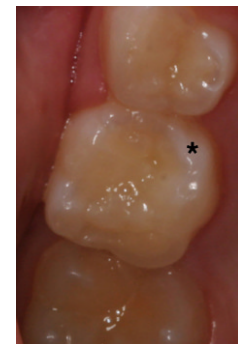

Fig. 3. Crown morphology of the primary maxillary right second molar of case 1 (*: additional cusp).

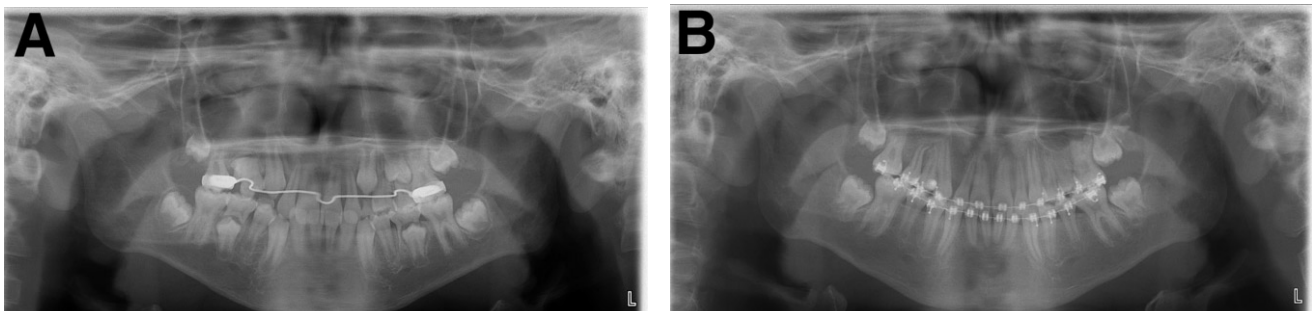


Fig. 4. Panoramic radiographs after extraction of the primary maxillary right second molar of case 1. (A) 14 months after extraction. Position of the maxillary right second premolar was improved. (B) 29 months after extraction.

right canine was suspected to be a cystic lesion. CBCT was performed, and a cystic lesion around the maxillary right canine was confirmed. The primary maxillary right second molar had 4 roots, and second premolar was mesially angulated and rotated by more than 90 degrees (Fig. 6). The distopalatal root was more robust than the mesiopalatal root in the primary maxillary right second molar. With regard to crown morphology, a well-developed additional cusp was identified on the mesiopalatal side (Fig. 7).

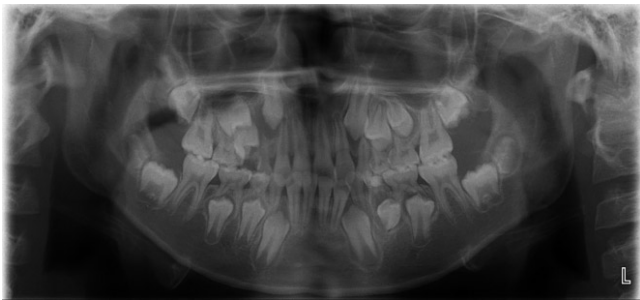


Fig. 5. Panoramic radiograph at first visit of case 2.

The cyst around the maxillary right canine was enucleated and orthodontic traction was initiated. The primary maxillary right second molar was extracted to improve angulation of the second premolar. A transpalatal arch was used for space maintenance. Thirteen months after extraction, the second premolar emerged into the oral cavity (Fig. 8).

III. Discussion

In a previous report of a primary maxillary second molar with 4 roots, the distopalatal root was the more robust of the two palatal roots, and the mesiopalatal root was suspected to be the additional root¹²⁾. In case 1 of the current report there was no significant size difference between the 2 palatal roots, but in case 2 the distopalatal root was more robust, which was similar to the findings in the previous report¹²⁾.

Taylor¹³⁾ reported that an additional root may be present if an additional cusp is present in the crown of the primary maxillary second molar, and that the size of the

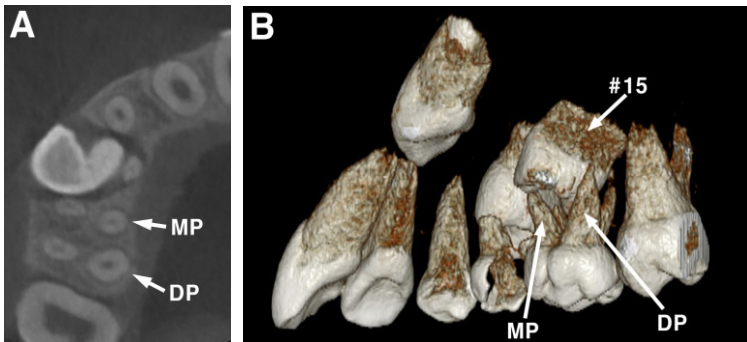


Fig. 6. CBCT view of case 2. Primary maxillary right second molar had two distinct palatal roots and second premolar was mesially angulated and rotated. (A) Axial view (MP: mesiopalatal root, DP: distopalatal root). (B) 3-dimensional view.

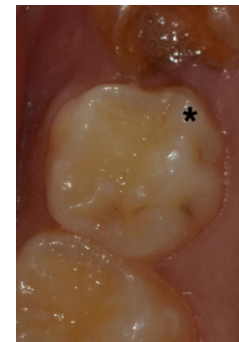


Fig. 7. Crown morphology of the primary maxillary right second molar of case 2 (*: additional cusp).

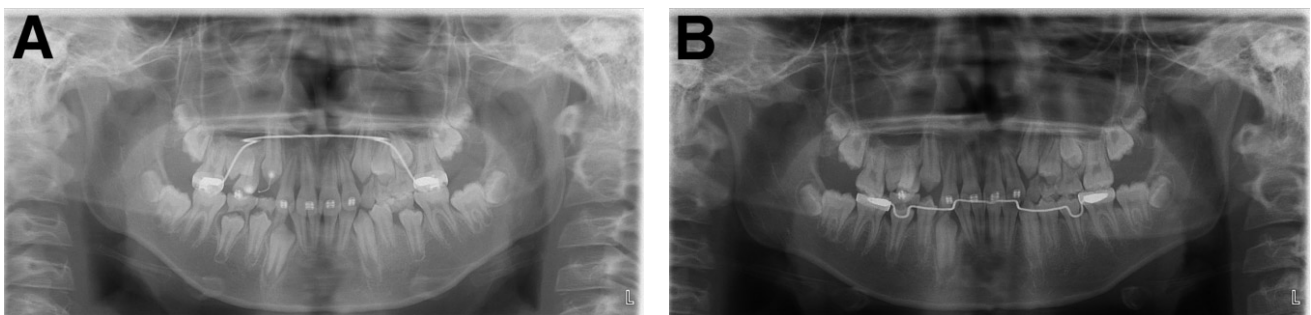


Fig. 8. Panoramic radiographs after extraction of the primary maxillary right second molar of case 2. (A) 8 months after extraction. Mesial angulation of the maxillary right second premolar was improved. (B) 14 months after extraction.

additional cusp is not associated with the likelihood of additional roots. Carlsen and Alexandersen¹⁴⁾ reported that maxillary molars with 2 palatal roots had a prominent structure on the palatal side of the crown and that the palatal root existed on the same side of the prominence was identified as the additional root. Additional cusps were observed in both cases in the current report, although it was observed more clearly in case 2.

The association between an additional root of the primary molar and displacement and rotation of the permanent successor has rarely been studied. An additional root in a primary tooth may disturb the eruption of the successor and normal exfoliation of the primary tooth, due to uneven root resorption by the permanent successor¹⁵⁾. Asymmetric resorption of roots in primary molars can result in the rotation of premolars¹⁶⁾.

In the current report, the primary molar could not accommodate the permanent successor in case 1. Usually, the premolar germ moves towards the apical side of the primary molar after primary molar root formation¹⁷⁾. The degree of primary molar root separation is not determined by the premolar germ, but depends on the amount of alveolar bone and the shape and proximity of the maxillary sinus¹⁸⁾. Based on these findings, alterations in the interradicular space due to an additional root in the primary molar may have been responsible for the failed accommodation of the permanent successor observed in case 1. The rotation of the premolar observed in case 2 may also have been due to alterations in the interradicular space, causing improper positioning of the premolar germ or asymmetric resorption of the root, resulting in rotation.

If the premolar germ is displaced or shows an abnormal eruption pattern compared to the corresponding tooth in the opposite side of the arch, early extraction of the primary molar and maintaining space can be used as a conservative treatment¹⁸⁻²⁰⁾. In case 1 of the current report, spontaneous improvement of eruption path of the maxillary second premolar was observed after the extraction of the primary second molar and space maintenance treatment. In case 2, improvement of mesial angulation of the maxillary second premolar was observed.

IV. Summary

Clinicians should suspect the presence of an additional root if an additional cusp is observed on the crown of the primary maxillary second molar and its presence can be

confirmed via routine dental radiographs. If an additional root is present, eruption of the permanent successor should be observed carefully. Early extraction of the primary molar and space maintenance may be required if the premolar germ shows an abnormal eruption pattern.

References

1. Kim KR, Song JS, Son HK, *et al.* : Morphological changes in the crown of mandibular molars with an additional distolingual root. *Arch Oral Biol*, 58:248-253, 2013.
2. Song JS, Kim SO, Lee JH, *et al.* : Incidence and relationship of an additional root in the mandibular first permanent molar and primary molars. *Oral Surg Oral Med Oral Pathol Oral Radiol Endod*, 107:e56-60, 2009.
3. Jones AW : The incidence of the three-rooted lower first permanent molar in Malay people. *Singapore Dent J*, 5:15-17, 1980.
4. Reichart PA, Metah D : Three rooted permanent mandibular first molars in the Thai. *Community Dent Oral Epidemiol*, 9:191-192, 1981.
5. Yew SC, Chan K : A retrospective study of endodontically treated mandibular first molars in a Chinese population. *J Endod*, 19:471-473, 1993.
6. Ferraz JA, Pecora JD : Three rooted mandibular molars in patients of Mongolian, Caucasian, and Negro origin. *Braz Dent J*, 3:113-117, 1993.
7. Cruzon ME : Three-rooted mandibular permanent molars in English Caucasians. *J Dent Res*, 52:181, 1973.
8. Souza-Freitas JA, Lopes ES, Casati-Alvares L : Anatomic variations of lower first permanent molar roots in two ethnic groups. *Oral Surg Oral Med Oral Pathol*, 31:274-278, 1971.
9. Skidmore AE, Bjorndal AM : Root canal morphology of the human mandibular first molar. *Oral Surg Oral Med Oral Pathol*, 32:778-784, 1971.
10. Yang R, Yang C, Zou J, *et al.* : Evaluate root and canal morphology of primary mandibular second molars in Chinese individuals by using cone-beam computed tomography. *J Formos Med Assoc*, 112:390-395, 2013.
11. Tu MG, Liu JF, Huang HL, *et al.* : Prevalence of three-rooted primary mandibular first molars in Taiwan. *J Formos Med Assoc*, 109:69-74, 2010.
12. Kavanagh C, O'Sullivan VR : A four-rooted primary

- upper second molar. *Int J Paediatr Dent*, 8:279-282, 1998.
13. Taylor RM : Deciduous molar root variation. *Hum Biol*, 58:655-698, 1986.
 14. Carlsen O, Alexandersen V : Radix mesiolingualis and radix distolingualis in a collection of permanent maxillary molars. *Acta Odontol Scand*, 58:229-236, 2000.
 15. Hayutin DJ, Ralstrom CS : Primary maxillary bilateral birooted canines: report of two cases. *ASDC J Dent Child*, 59:235-237, 1992.
 16. Kim YH, Shiere FR, Fogels HR : Pre-eruptive factors of tooth rotation and axial inclination. *J Dent Res*, 40:548-557, 1960.
 17. Nanci A : Ten Cate's Oral Histology: Development, Structure and Function, 7th ed., 268-282, Mosby, 2007.
 18. Collett AR : Conservative management of lower second premolar impaction. *Aust Dent J*, 45:279-281, 2000.
 19. Valcheva Z, Arnautska HI, Gergiev T, *et al.* : Diagnostic approach to the incorrect position of lower second premolars. *Scripta Scientifica Medciniae Dentalis*, 1:36-40, 2015.
 20. Jung HJ, Kim YJ, Nam SH, *et al.* : Eruption guidance for tooth germ of premolar displaced by infraoccluded upper deciduous molar. *J Korean Acad Pediatr Dent*, 39:390-395, 2012.

국문초록

상악 제2유구치의 부가치근과 함께 관찰된 영구 계승치의 변위 및 회전 : 증례 보고

구재원 · 이제우 · 라지영

원광대학교 치과대학 소아치과학교실

상악 제2유구치의 부가치근은 드물게 관찰된다. 본 증례보고에서는 두 증례를 통해 상악 제2유구치의 부가치근과 하방 영구 계승치의 변위 및 회전이 연관되었을 가능성에 대해 논의하였다. 상악 제2유구치의 치관 형태를 관찰함으로써 부가치근의 존재 가능성을 의심할 수 있으며, 부가치근이 존재하는 경우 영구 계승치의 맹출 양상을 주의 깊게 관찰해야 할 필요가 있을 것으로 사료된다. 만약 소구치 치배가 비정상적인 맹출 양상을 보인다면 선행 유치의 조기 발거 및 공간유지가 보존적인 치료법이 될 수 있다.

주요어: 부가치근, 유구치, 소구치 치배, 변위, 회전