

Ankylosed Primary Molar and Eruption Guidance of Succeeded Permanent Premolar : Case Reports

Hayoung Jang, Sohee Oh

Department of Pediatric Dentistry, Dental Clinic Center, Hallym University Sacred Heart Hospital

Abstract

In the management of ankylosed primary molars, early diagnosis, proper treatment, and thorough follow-ups are very important. Untreated infraocclusion due to ankylosis has a negative impact on normal occlusal development, and may cause problems. There are many treatment options on infraoccluded deciduous molars, such as periodic observation, conservative method, restoration, and space regaining via extraction of the teeth. In this case report, two 6-year-old girls were diagnosed with ankylosed maxillary second primary molar and displaced tooth germ of the second premolar. Early surgical removal of the ankylosed primary molar was considered as a treatment approach. The long-term follow-up shows normal eruption of a succeeded permanent premolar.

Key words : Ankylosis, Infraocclusion, Tooth germ displacement, Eruption guidance

I . Introduction

An ankylosed tooth is defined as an anatomical fusion of the tooth cementum with the alveolar bone as a result of some disturbance in their periodontal ligament^{1,2)}. In this situation, the teeth have failed to undergo a normal process of eruption, and this will result in an under growth around the teeth. Andlaw and Rock³⁾ defined infraocclusion as “a tooth that has failed to maintain its position relative to the adjacent teeth in the developing dentition and is, therefore, submerged below the occlusal level”.

Many studies showed that the ankylosis is considered as a typical etiology in infraocclusion. Many authors⁴⁻⁷⁾ reported that there was a hereditary component of ankylosis based on the observation of infraocclusion of the second maxillary primary molars in several members of

the same family. The high incidence of ankylosed primary teeth was seen in children between ages seven and eleven^{4,8-10)}.

In the management of ankylosed primary molars, early diagnosis, proper treatment, and thorough follow-ups are very important. Extensive bony ankylosed primary molars interfere with the exfoliation and eruption of the permanent successors¹¹⁻¹⁵⁾. Several authors^{11,15,16)} have reported complications when the condition has remained untreated. Untreated infraocclusion has a negative impact on normal occlusal development, and may cause problems, such as prolonged retention of infraoccluded teeth, extrusion of apposed teeth, destruction of periodontal tissues via occlusal force and food packing, increased susceptibility to dental caries, and disturbances on the eruption pathway of the permanent successors. Over time, the progressive infraocclusion may cause

Corresponding author : Sohee Oh

Department of Pediatric Dentistry, Dental Clinic Center, Hallym University Sacred Heart Hospital, 896, Pyengchon-dong, Dongan-gu, Anyang, 14068, Republic of Korea

Tel: +82-31-380-5973 / FAX : +82-31-380-1726 / E-mail: pedopia@hallym.or.kr

Received April 28, 2016 / Revised July 1, 2016 / Accepted June 15, 2016

tipped adjacent teeth, bone defects, and hindered or delayed eruption of the permanent successors¹⁷⁾. As a result, periodic check-ups and proper treatments are required.

Treatment should be based on the evaluation of the growth potential that has been jeopardized by the condition. There are many treatment options on infraoccluded deciduous molars, such as periodic observation, conservative method, restoration, and space regaining via extraction of the teeth. The choice of treatment may depend on the presence of succedaneous teeth, time of diagnosis, and degree of infraocclusion¹⁶⁾. The general treatment recommendation is to await normal exfoliation of the infraoccluded primary molars. Henderson¹⁸⁾ has reported the possibility that ankylosed molars can break loose and subsequently become aligned in a normal manner. A constant supervision of the occlusal development and periodic radiographic control of the normal root resorption are recommended. Biederman and Skolnick^{19,20)} introduced a locking technique in an attempt to break the bony union and allow the affected tooth to resume eruption. A restorative procedure to maintain the ankylosed tooth's mesiodistal dimension and occlusal contact is also taken into consideration¹⁴⁾. However, there are special cases accompanied by deleterious effects (occlusal disturbances with severe tipping of the neighbouring teeth and space loss, malposition of the permanent successor that prevents normal root resorption, and severe infraocclusion, among others that require an extraction. Most authorities^{17,21)} have recommended early extraction of the ankylosed primary teeth and subsequent space management, particularly on a younger patient.

Early developing ankylosis is viewed as a condition which progressively worsens. Postponement of the removal of an early ankylosed primary molar is not frequently recommended because a subsequent removal will be inevitable, and the surgical procedure may be more difficult if the teeth mesial or distal to the ankylosed tooth tip into its intended space.

In this case report, two 6-year-old girls were diagnosed with ankylosed maxillary second primary molar and displaced tooth germ of the second premolar. Early surgical removal of the ankylosed primary molar was considered as a treatment approach. After a year, there was evidence of further development of a permanent successor premolar in radiographic evaluation. The long-term follow-up shows normal eruption of a succeeded

permanent premolar and any other complications.

II . Case Reports

1. Case 1

A six-year-old girl was referred to the Pediatric Dentistry Department of Hallym University Sacred Heart Hospital by general dentist to assess her ankylosed maxillary left second primary molar. The patient does not have a relevant medical history of any systemic disease, and she has a normal development for her age.

Intraoral examination showed the patient to be in the early mixed dentition with the entire primary teeth, except for the maxillary left second primary molar. The ankylosed maxillary left second primary molar was found to be severely infraoccluded and the adjacent teeth had tilted toward the infraoccluded tooth (Fig. 1A).

Radiographic examination by means of a panoramic radiograph showed the presence of a completely submerged maxillary left second primary molar with an underlying maxillary left second premolar tooth germ (Fig. 1B). The 3-dimensional cone-beam computed tomography (CBCT) view revealed an ankylosed left second primary molar with displacement of the successor tooth germ (Fig. 1C-1E). The underlying left second premolar was in an abnormal relationship with the roots of the primary molar and compared to right second premolar. The left second premolar tooth germ was completely displaced mesiopalatally.

An emergency intervention seemed logical when considering the loss of arch length and abnormal development of the patient's permanent successor tooth germ. For this reason, surgical extraction was the preferred treatment approach.

The surgical extraction of the ankylosed tooth was performed under general anesthesia at the oral and maxillofacial surgery (OMFS) in Hallym University Sacred Heart Hospital (Fig. 2). The orthodontic treatment was scheduled at a subsequent time in order to provide space by uprighting of the first permanent molar that had tipped mesially. An appropriate space was acquired approximately eight months with fixed appliance, and followed by space maintenance (Fig. 3). There was evidence of further development of a permanent successor in the radiographic evaluation (Fig. 4).

The patient was reviewed annually for 6 years until the spontaneous eruption of the second premolars. At

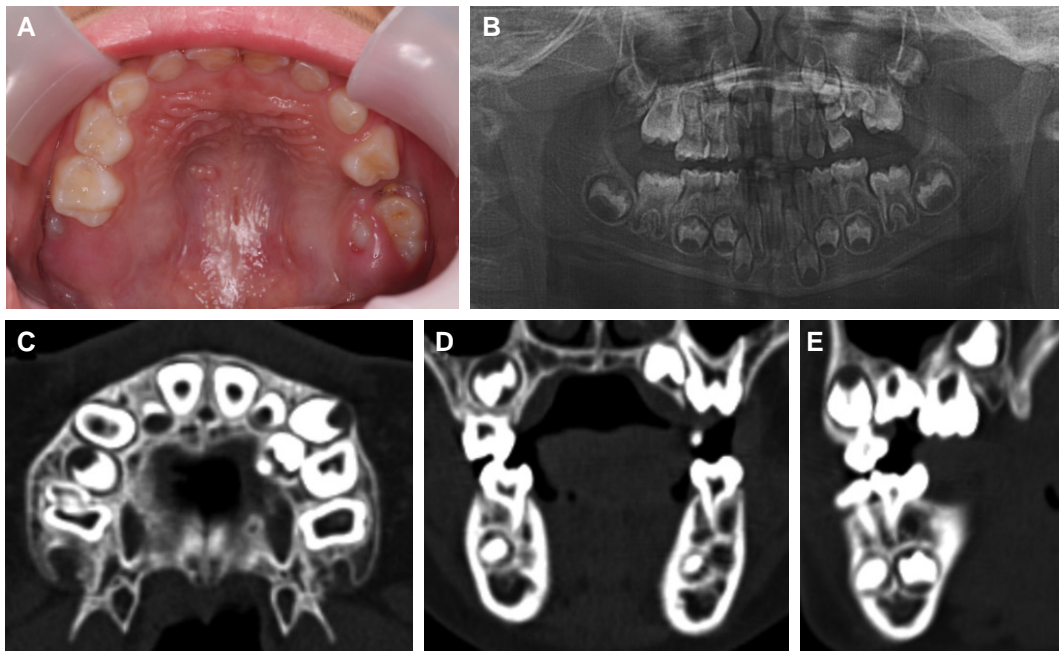


Fig. 1. At first examination. (A) intraoral photo. Infraocclusion of the maxillary left second primary molar being covered by the surrounding tissues. (B) Panoramic radiograph. Submerged maxillary left second primary molar with underlying permanent successors. (C-E) CBCT image, horizontal, coronal and sagittal view. Upper left second premolar tooth germ position mesiopalatally.

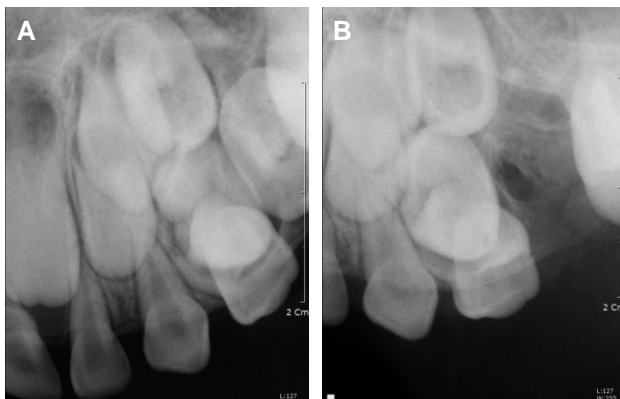


Fig. 2. Periapical view. Before (A) and after (B) surgical removal of ankylosed primary molar. Mesiopalatally positioned second premolar tooth germ is seen.

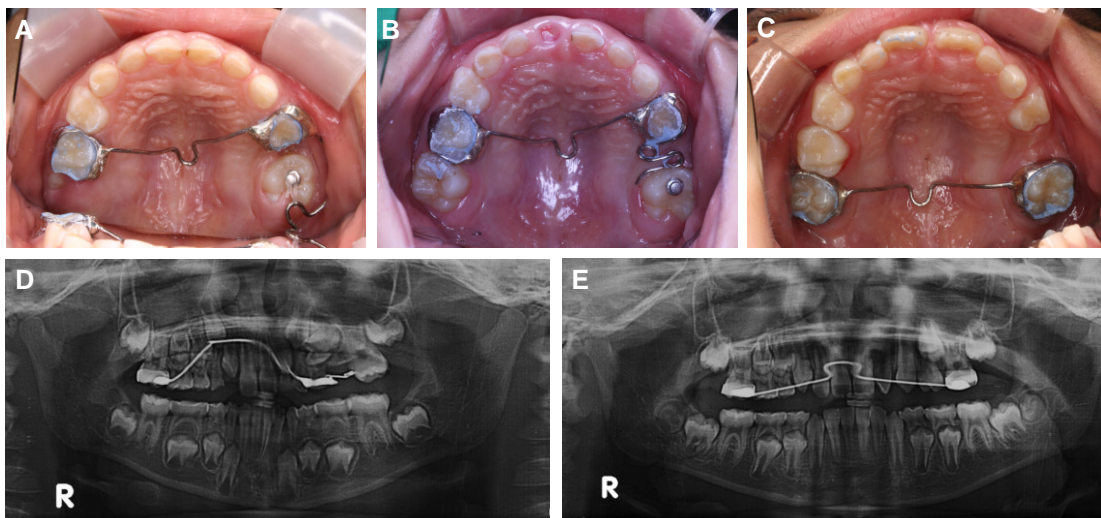


Fig. 3. During treatment; Fixed intraoral appliance for space regaining and space maintaining.

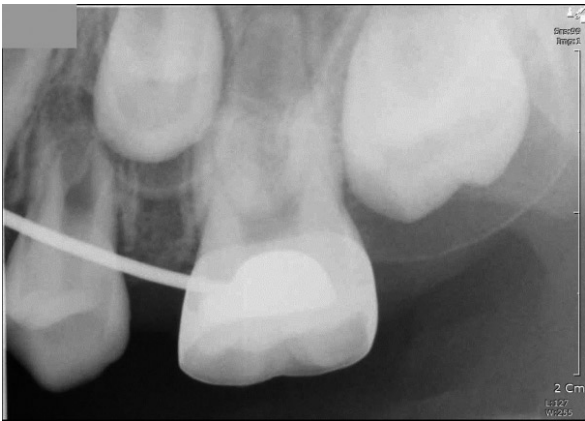

Fig. 4. At 30 months after surgical removal of ankylosed tooth; Periapical view shows the movement of permanent successor tooth germ in alveolar bone.

the age of 12, a comprehensive orthodontic treatment was performed to align the whole dentition for approximately 18 months (Fig. 5). At the follow-up appointment, a favorable result was found on her dentition and well-retained occlusion (Fig. 6).

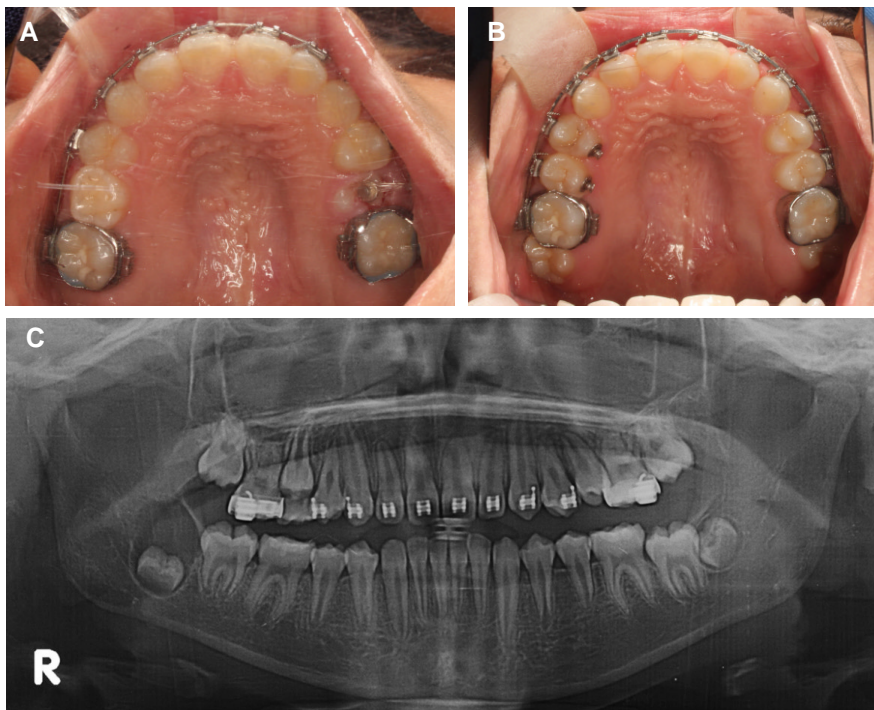


Fig. 5. Sign of spontaneously eruption (A) and complete eruption (B, C) of upper left second premolar.

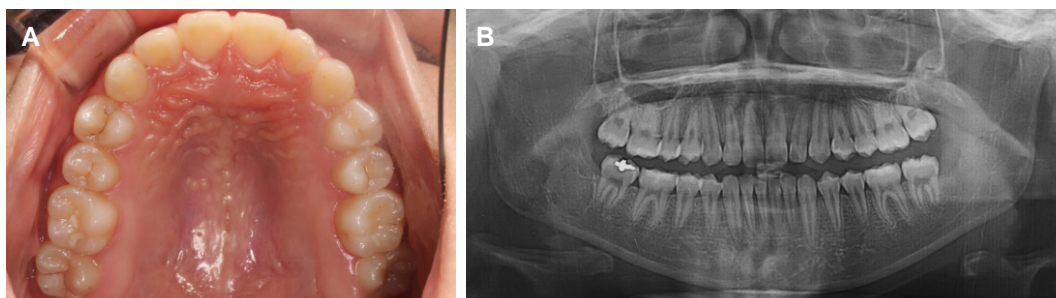


Fig. 6. Follow-up examination of 8 years.

2. Case 2

A six-year-old girl was referred to the Pediatric Dentistry Department of Hallym University Sacred Heart Hospital by general dentist for the correction of a partial eruption of the maxillary right second primary molar. The patient had no relevant medical history of any systemic disease, and her family reported no drug use.

Intraoral examination showed the patient to be in the early mixed dentition with a severely infraoccluded maxillary right second primary molar. The maxillary left second primary molar is ankylosed, partially erupted, and covered by the surrounding tissues. Adjacent teeth, maxillary first primary molar and first permanent molar has tilted toward the infraoccluded tooth (Fig. 7A).

Radiographic examination by means of a panoramic radiograph showed the presence of a infraoccluded maxillary left second primary molar with an underlying maxillary left second premolar tooth germ (Fig. 7B). The 3-dimensional cone-beam computed tomography (CBCT) view revealed an ankylosed right second primary molar, and a displaced underlying permanent successor tooth germ mesiopalatally located above the roots of the first primary molar (Fig. 7C, 7D).

Surgical extraction of the ankylosed maxillary left second primary molar was carried out under general anesthesia at the oral and maxillofacial surgery (OMFS) in Hallym University Sacred Heart Hospital (Fig. 8). A subsequent treatment involved regaining the loss of space with a removable and fixed space regainer appliance for approximately 6 months (Fig. 9). The space for the permanent successor second premolar was acquired. After a year, the development of maxillary right second premolar germ was observed to its normal position (Fig. 10). In the follow-up examination, we observed a normal and spontaneous eruption of the maxillary right second premolar (Fig. 11).

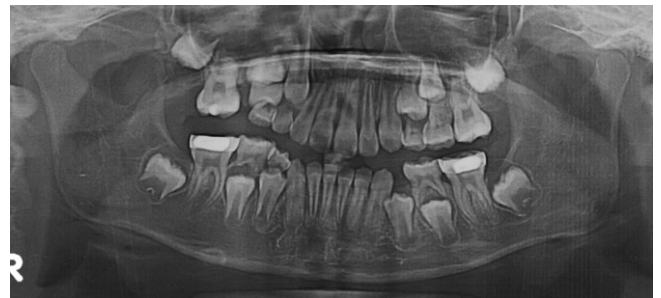

Fig. 8. After surgical removal of ankylosed second primary molar.

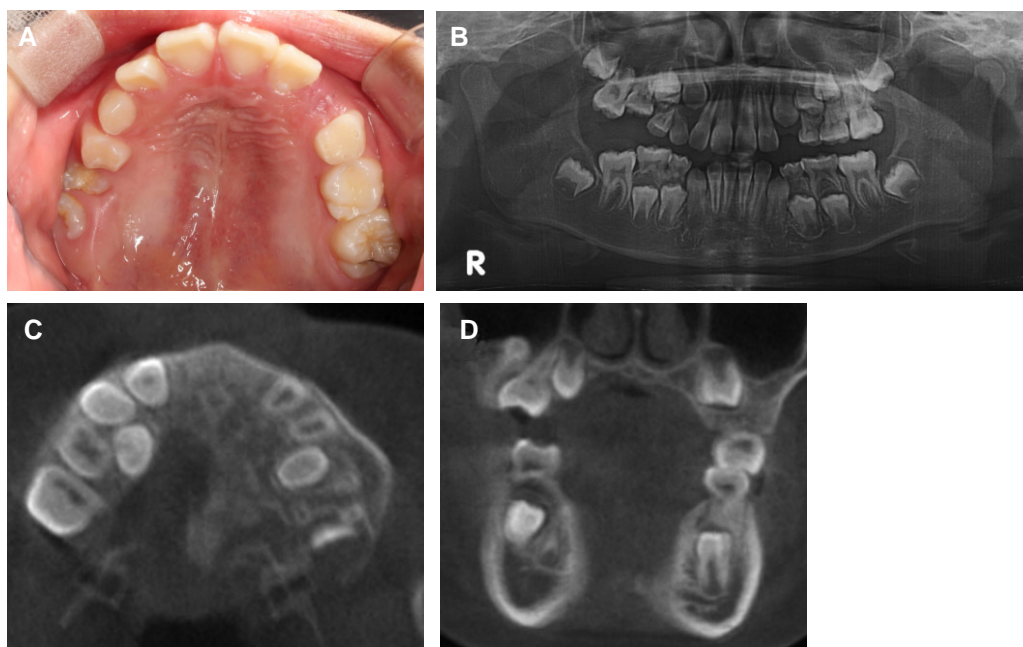


Fig. 7. At first examination. (A) intraoral photo. Infraocclusion of the maxillary right second primary molar being covered by the surrounding tissues. (B) Panoramic radiograph. Submerged maxillary right second primary molar with underlying permanent successors. (C, D) CBCT image, horizontal and coronal view. Upper right second premolar tooth germ position mesiopalatally.

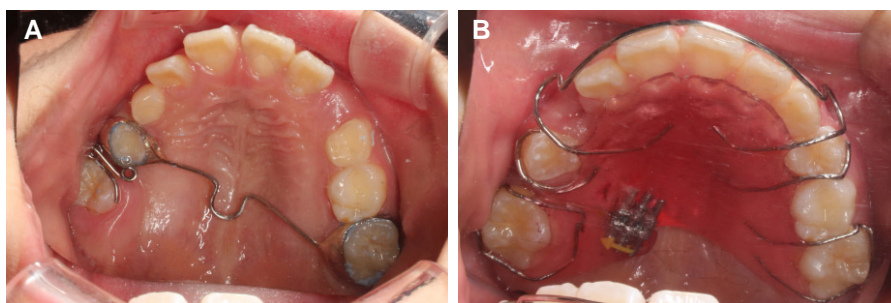


Fig. 9. During treatment. Fixed and removable intraoral appliance for Space regaining.

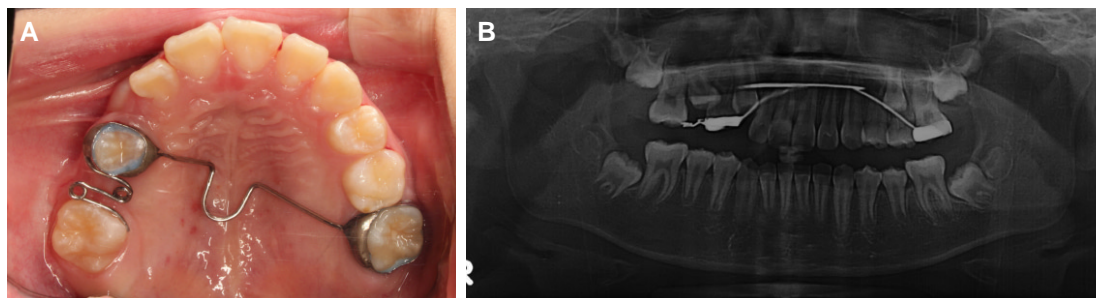


Fig. 10. At 24 months after surgical removal of ankylosed tooth; space maintaining appliance (A) and panoramic view (B) shows the movement of permanent successor tooth germ in alveolar bone.

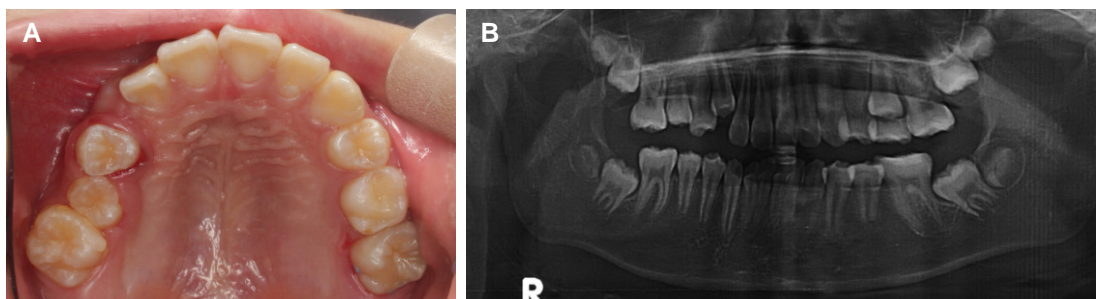


Fig. 11. follow-up examination of 2 years; Normal eruption of Upper right second premolar is observed.

III . Discussion

In this case report, the ankylosed maxillary primary second molars are surgically removed, and the space is regained for the spontaneous eruption of the displaced tooth germ of the second premolar.

Normally, ankylosed primary molars with permanent successor teeth are physiologically resorpted and exfoliated. However, there are unknown factors that induce extensive bony ankylosis. It may interrupt with a normal tooth resorption and induce eruption problems, such as delayed eruption, ectopic eruption, and tooth impaction.

Ankylosis may occasionally occur even before the eruption and complete root formation of the primary tooth. Infraocclusion induced by ankylosis is diagnosed in the early mixed dentition, between ages 8-9, at the peak of facial growth⁹⁾. The tooth remained in its ankylosed condition until the adjacent first permanent molar began to erupt through the gingival tissue. However, previous studies have shown an infraocclusion of the primary molar that has been observed from a 3-year-old child^{4,10)}.

The ankylosed primary molar should undergo a periodic follow-up until the proper time for treatment intervention, such as extraction and space management, for guiding the eruption of the permanent successor. The

decision, as to whether or not to instigate treatment, is based on the age of the patient, the degree and extent of the infraocclusion, the amount of root resorption, the severity of the tilting of neighboring teeth, and the presence and location of the permanent successor.

The ankylosed maxillary primary molar has the tendency to become severely submerged, and progressively worse with age²². Infraocclusion in the maxillary primary molar with permanent tooth germ displacement and loss of arch length caused by tipping of the adjacent teeth are predicted to delay the eruption or impaction of the permanent successor. It should be surgically removed and a space maintaining appliance should be used.

An extraction should be deferred if possible until the first permanent molar erupts in order to allow space maintenance. Extraction is recommended as soon as possible by many authors. Meanwhile, other authors recommended early treatment only when there is a severely affected primary molar, and if there is evidence of possible future crowding. According to Kurol and Thilander²³, early extraction is only necessary when there is a combination of occlusal disturbance, severe tipping of neighbouring teeth, space loss, malposition of the permanent successor with irregular primary root resorption, and severe infraocclusion. Early extraction may be technically difficult and may result in fracture of the roots, or possible disturbance of the succeeded tooth bud.

In addition, early extraction and long-term space maintenance would have been simple solutions in these cases, and may have prevented the tilting, loss of space for the successor, and the significant centre line shift, which can be difficult to correct. The marginal ridge of the ankylosed tooth that is on the gingival level or below must be extracted. The tendency of ankylosed maxillary molars to be severely infraoccluded usually indicates early extraction²⁴.

Severe tipping of the neighbouring teeth toward the infraoccluded teeth may induce arch length problems that should be surgically extracted. Mesial tilting of the first permanent molar makes surgical extraction difficult. In this situation, space regaining is preceded until surgical extraction due to the severe loss of arch length that required ankylosed teeth extraction. Altay and Cengiz²⁵ recommended space regaining prior to the extraction of a submerged tooth.

Space regaining of the competent spaces and extraction were performed with minimum possibility of trauma toward the subsequent permanent molar. These surgical

sequences are considered much easier and more comfortable for both the surgeon and the patient.

The sequence is not affected by the treatment prognosis or determined by the state of infraocclusion at the initial diagnosis of its removal. Jung²⁶ reported two cases with space management and a case extraction prior to space regaining. It was determined upon first examination where it was easy to extract. Both methods induced the subsequent permanent premolar to erupt spontaneously, indicating that the treatment result is not affected by the sequence.

Cozza¹⁷ reported three cases of early extraction of infraoccluded ankylosed primary molars, accompanied by orthodontic treatment until the spontaneous eruption of the second premolar.

In this case report, ankylosed primary molars are extracted early, and space management is performed. Surgical extraction of the primary molar should be carefully approached for the possibility of affecting the successor permanent tooth germ through iatrogenic damage or complication during operation. We achieved a spontaneous eruption of the successor permanent teeth via early removal of the ankylosed teeth, and performed treatment with space management. Periodic follow-up showed proper vertical alveolar bone height on the whole dentition.

In the management of an ankylosed tooth, early recognition and diagnosis are extremely important. In an ankylosed tooth, the obstruction is removed, and the displaced permanent tooth will normally erupt. If there is a severe infraocclusion that requires a space regaining procedure, it should be considered before treatment due to the possibility of re-evaluation of the orthodontic treatment after the eruption of the second premolar.

IV. Summary

In this case, the maxillary second premolar tooth germs were displaced due to the ankylosis of the maxillary second primary molar. The ankylosed tooth was extracted, and the space regaining was performed, thereby leading to the normal eruption of the subsequent permanent tooth buds.

In two cases presented here, the early extraction of the infraoccluded primary molars and the active treatment of space regaining allowed the spontaneous eruption of the second premolars, thereby obtaining a normal vertical relationship and normal bone height.

References

1. Owen TL : Ankylosis of teeth. *J Mich State Dent Assoc*, 47:347-350, 1965.
2. Pilo R, Littner MM, Marshak B, Aviv I : Severe infraclusion ankylosis: report of three cases. *ASDC J Dent Child*, 56:144-146, 1989.
3. Kurol J, Magnusson BC : Infraocclusion of primary molars: a histologic study. *Scand J Dent Res*, 92:564-576, 1984.
4. Kurol J : Infraocclusion of primary molars: an epidemiologic and familial study. *Community Dent Oral Epidemiol*, 9:94-102, 1981.
5. Via WF : Submerged Deciduous Molars : Familial Tendencies. *J Am Dent Assoc*, 69:127-129, 1964.
6. Helpin ML, Duncan WK : Ankylosis in monozygotic twins. *ASDC J Dent Child*, 53:135-9, 1986.
7. Douglass J, Tinanoff N : The etiology, prevalence and sequelae of infraclusion of primary molars. *ASDC J Dent Child*, 58:481-483, 1991.
8. Noble J, Karaikos N, Wiltshire WA : Diagnosis and management of the infraerupted primary molar. *Br Dent J*, 203:632-634, 2007.
9. Rune B, Sarnos KV : Root resorption and submergence in retained deciduous second molars. *Eur J Orthod*, 6:123-131, 1984.
10. Steigman S, Koyoumdjisky-Kaye E, Matrai Y : Submerged deciduous molars in the preschool children: an epidemiological survey. *J Dent Res*, 52:322-326, 1973.
11. Biederman W : The problem of the ankylosed tooth. *Dent Clin North Am*, 12:409-424, 1968.
12. Andlaw RJ : Submerged deciduous molars. A review with special reference to the rationale of treatment. *J Int Assoc Dent Child*, 5:59-66, 1974.
13. Darling AI, Levers BG : Submerged human deciduous molars and ankylosis. *Arch Oral Biol*, 18:1021-1040, 1973.
14. Krakowiak FJ : Ankylosed primary molars. *ASDC J Dent Child*, 45:288-292, 1978.
15. Konstat MM, White GE : Ankylosed teeth: a review of the literature. *J Mass Dent Soc*, 24:74-78, 1975.
16. Jenkins FR, Nichol RE : Atypical retention of infraoccluded primary molars with permanent successor teeth. *Eur Arch Paediatr Dent*, 9:51-55, 2008.
17. Cozza P, Gatto R, Mucedero M, et al. : Case report: severe infraocclusion ankylosis occurring in siblings. *Eur J Paediatr Dent*, 5:174-178, 2004.
18. Henderson HZ : Ankylosis of primary molars: a clinical, radiographic and histologic study. *ASDC J Dent Child*, 46:117-122, 1979.
19. Biederman W : Etiology and treatment of tooth ankylosis. *Am J Orthod*, 48:670-684, 1962.
20. Skolnick IM : Ankylosis of Maxillary Permanent First Molar. *J Am Dent Assoc*, 100:558-560, 1980.
21. Belanger GK, Strange M, Sexton JR : Early ankylosis of a primary molar with self-correction: case report. *Am Academy Pediatr Dent*, 8:37-40, 1986.
22. Messer LB, Cline JT : Ankylosed primary molars : results and treatment recommendations from an eight-year longitudinal study. *Pediatr Dent*, 2:37-47, 1980.
23. Kurol J, Thilander B : Infraocclusion of primary molars and the effect on occlusal development, a longitudinal study. *Eur J Orthod*, 6:277-293, 1984.
24. Kurol J, Koch G : The effect of extraction of infraoccluded deciduous molars : A longitudinal study. *Am J Orthod*, 87:46-55, 1985.
25. Altay N, Cengiz SB : Space-regaining treatment for a submerged primary molar: a case report. *Int J Paediatr Dent*, 12:286-289, 2002.
26. Jung JH, Kim YJ, Kim HJ, Nam SH : Eruption guidance for tooth germ of premolar displaced by infraoccluded upper deciduous molar. *J Korean Acad Pediatr Dent*, 39:390-396, 2012.

국문초록

유착된 유구치와 후속 영구 소구치의 맹출 유도 : 증례보고

장하영 · 오소희

한림대학교성심병원 치과진료센터 소아치과

유착된 유구치의 치료에 있어 조기 진단이 매우 중요하다. 유착으로 인하여 발생된 저위교합을 방지하는 경우 교합적인 문제가 생길 수 있으므로 정기검진을 통한 진단과 이에 따른 적절한 치료가 필요하다. 저위교합 된 유구치의 치료 방법으로 정기검진, 보존적 접근, 보철적 수복, 발치를 수반한 공간획득 등이 있다. 본 증례에서는 상악 제2유구치의 유착으로 인하여 제2소구치 치배의 변위를 보이는 두 명의 환아를 대상으로 이환치의 발거를 먼저 시행하고 고정성 혹은 가철성 교정장치를 이용하여 공간확장술을 함으로써 변위되었던 제2소구치 치배의 정상 맹출을 유도하였으며 장기간에 걸쳐 부작용이 없었음을 보고하는 바이다.

주요어: 유착, 저위교합, 치배 변위, 맹출 유도