

## Effect of Areca Nut on *Helicobacter pylori*-Induced Gastric Diseases in Mice

Jinwook Lee<sup>1†</sup>, Niluka D. Gunawardhana<sup>2#</sup>, Sungil Jang<sup>2,3</sup>, Yun Hui Choi<sup>2,3</sup>, Rasika P. Illeperuma<sup>4</sup>, Aeryun Kim<sup>2,3</sup>, Hanfu Su<sup>2,3</sup>, Youngmin A. Hong<sup>2,3</sup>, Ji-Hye Kim<sup>5</sup>, Jinmoon Kim<sup>2#</sup>, Da-Woon Jung<sup>6</sup>, In-Ho Cha<sup>1</sup>, Eun-Jung Bak<sup>2\*</sup>, and Jeong-Heon Cha<sup>2,3,7\*</sup>

<sup>1</sup>Department of Dentistry, The Graduate School, Department of Oral and Maxillofacial Surgery, Yonsei University College of Dentistry, Seoul 03722, Republic of Korea

<sup>2</sup>Department of Oral Biology, Oral Science Research Center, BK21 PLUS Project, Yonsei University College of Dentistry, Seoul 03722, Republic of Korea

<sup>3</sup>Department of Applied Life Science, The Graduate School, Yonsei University, Seoul 03722, Republic of Korea

<sup>4</sup>Department of Medical Laboratory Science, Faculty of Allied Health Sciences, University of Peradeniya, Peradeniya, Sri Lanka

<sup>5</sup>Department of Dental Hygiene, Jeonju Kijeon College, Jeonju 54989, Republic of Korea

<sup>6</sup>New Drug Targets Laboratory, School of Life Sciences, Gwangju Institute of Science and Technology, Gwangju 61005, Republic of Korea

<sup>7</sup>Key Laboratory of Oral Medicine, Guangzhou Institute of Oral Disease, Stomatology Hospital of Guangzhou Medical University, Guangzhou 510140, P.R. China

Received: June 16, 2016

Revised: July 8, 2016

Accepted: July 11, 2016

First published online  
July 19, 2016

\*Corresponding authors

J.-H.C.

Phone: +82-2-2228-3061;

Fax: +82-2-2227-7903;

E-mail: jcha@yuhs.ac

E.-J.B.

Phone: +82-2-2228-3062;

Fax: +82-2-2227-7903;

E-mail: ejbak@yuhs.ac

#Current address: OMFS Unit,  
District General Hospital, Nuwara  
Eliya, Sri Lanka

#Current address: ATGen Ltd,  
Seongnam, Republic of Korea

†These authors contributed  
equally to this work.

pISSN 1017-7825, eISSN 1738-8872

Copyright© 2016 by  
The Korean Society for Microbiology  
and Biotechnology

Areca nut (AN) chewing is a habit in many countries in Central, Southern, and Southeast Asia. It is strongly associated with the occurrence of oral, pharyngeal, and esophageal cancer as well as systemic inflammation. However, the association between AN intake and the development of gastric lesions has not yet been identified. The aim of this study was to investigate the effect of AN on gastric diseases using a mouse model for *Helicobacter pylori* infection. We studied four groups of mice: those fed a normal diet (ND), those fed a diet containing 2.5% AN (AD), those fed ND and infected with *H. pylori* PMSS1 strain (ND/HP), and those fed AD and infected with *H. pylori* PMSS1 strain (AD/HP). Food intake and body weight were monitored weekly during the experiments. At 10 weeks, the mice were sacrificed, and the stomach weight, *H. pylori* colonization, and gastric inflammation were evaluated. The stomach weight had increased significantly in the ND/HP and AD/HP groups along with increases in *H. pylori* colonization; however, there was no significant difference between these two groups with respect to stomach weight and colonization. On histological grading, mononuclear cell infiltration was severer in the AD/HP group than in the ND/HP group. These data suggest that chronic gastric inflammation was aggravated by AN treatment in the mice with *H. pylori*-induced gastric lesions. Furthermore, as previously suggested, this animal model is useful to determine the effect of potential carcinogens on gastric lesions induced by *H. pylori* infection.

**Keywords:** Areca nut, *Helicobacter pylori*, gastric diseases

### Introduction

Areca nut (AN) is the fruit seed of the palm tree *Areca catechu*, which is often mixed with betel quid and used as a

masticatory substance by approximately 600 million people worldwide [14]. AN is consumed by people of all age groups, and chewing AN is a popular habit in Asian and Oceanic countries. It is considered to be commonly used as

a psychoactive substance, such as tobacco, alcohol, and caffeine [24], and its constituents include carbohydrate, fat, protein, crude fiber, polyphenols (such as flavonol and tannin), alkaloid, and mineral matter [21]. Systemic effects of AN are mainly due to its principal alkaloid, arecoline [12]. Previous studies have shown that AN chewers have a higher prevalence of periodontal diseases and of oral, pharyngeal and esophageal cancers [16]. Recently, it has also been reported that chewing AN may increase the risk of systemic inflammation [28].

*Helicobacter pylori* is a microaerophilic gram-negative spiral-shaped bacterium found in the human stomach. *H. pylori* is the major causative agent in chronic gastritis and peptic ulcer disease as well as a cause of gastric cancers [17]. An association between *H. pylori* infection and the development of gastric disease is also found in studies using animal models [2, 10, 11, 22]. Among these models, the mouse model using *H. pylori* strain PMSS1 is widely used [2, 20, 27]. Fernando *et al.* [8] suggested that chewing betel quid that contains AN and lime, with or without tobacco, may predispose persons infected with *H. pylori* to the development of severe gastric diseases, including gastric cancers, as a result of chewing and swallowing this substance. Thus, to identify an association between AN intake and *H. pylori*-induced gastric disease, we investigated the effects of AN on gastric lesions and on bacterial colonization in mice infected with the *H. pylori* PMSS1 strain.

## Materials and Methods

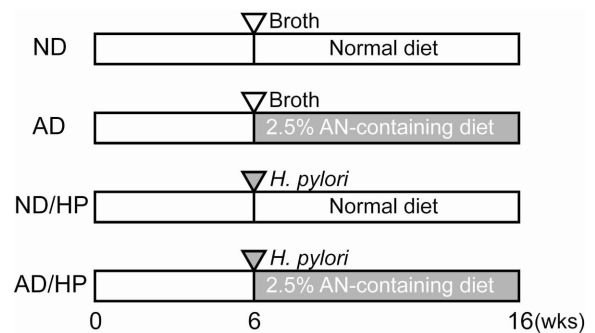
### Diet Preparation

AN was provided by the University of Peradeniya, Sri Lanka. Dried AN was finely powdered and mixed with a normal diet AIN76A (Research Diets, USA) at a concentration of 2.5% (w/w) in Gwangju Institute of Science and Technology, Korea. The diet containing AN was pelleted, sealed, and stored at 4°C until use.

### Animal Experiments

We purchased 5-week-old male C57BL/6 mice from Orient Bio Inc. (Korea). The animals were maintained in a temperature-controlled room at 22°C, with a 12 h light-dark cycle. Food and water were provided ad libitum. After 1 week of acclimation, 34 mice were divided into four groups: those fed a normal diet (the ND group) ( $n = 6$ ), those fed a diet containing 2.5% AN (the AD group) ( $n = 8$ ), those fed a normal diet and infected with *H. pylori* PMSS1 strain (the ND/HP group) ( $n = 10$ ), and those fed a diet containing 2.5% AN and infected with *H. pylori* PMSS1 strain (the AD/HP group) ( $n = 10$ ) (Fig. 1).

At 6 weeks after intragastric inoculation with *H. pylori* PMSS1 strain, the mice in the ND/HP and AD/HP groups were fed the



**Fig. 1.** Experimental design.

Mice in the ND group were inoculated with Brucella broth ( $\nabla$ ) and fed a normal diet ( $\square$ ). The AD group of mice was inoculated with Brucella broth and fed a diet containing 2.5% AN ( $\blacksquare$ ). The ND/HP group was inoculated with *H. pylori* strain PMSS1 ( $\blacktriangledown$ ) and fed a normal diet. The AD/HP group was inoculated with *H. pylori* strain PMSS1 and fed a diet containing 2.5% AN.

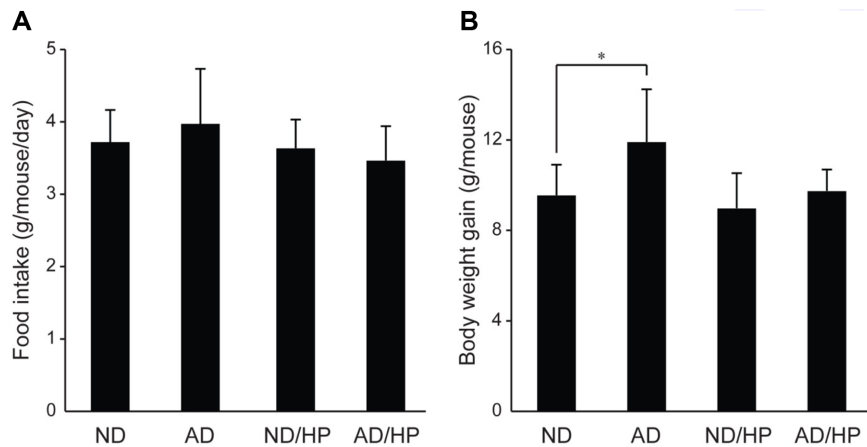
AIN76A diet and the AIN76A diet containing 2.5% AN, respectively, for 10 weeks. As a negative control, ND mice and AD mice that received Brucella broth were fed the AIN76A diet. The body weight and food intake were measured every week during the experimental period. At the end of this period, the mice were sacrificed, gastric mucosal tissues were weighed and examined histologically, and *H. pylori* colonization was determined, as described below. The animal experiments were performed in accordance with institutional guidelines, and protocols were approved by the animal ethics committee of the Yonsei University College of Dentistry in Seoul, Korea (2012-0076).

### *H. pylori* Culture and Infection of Mice

The *H. pylori* PMSS1 strain was stored as frozen stock at  $-80^{\circ}\text{C}$  in brain–heart infusion medium supplemented with 20% glycerol and 10% fetal bovine serum (FBS; Gibco-BRL, USA). *H. pylori* was grown on horse blood agar plates containing 4% Columbia blood agar base (Oxoid, Basingstoke, UK), 5% defibrinated horse blood (Hemostat Laboratories, Dixon, CA, USA), 0.2%  $\beta$ -cyclodextrin, 10  $\mu\text{g}/\text{ml}$  of vancomycin, 2.5 U/ml of polymyxin B, 5  $\mu\text{g}/\text{ml}$  of trimethoprim, and 8  $\mu\text{g}/\text{ml}$  of amphotericin B at  $37^{\circ}\text{C}$  under microaerobic conditions. A microaerobic atmosphere was generated using a CampyGen sachet (Oxoid) in a GasPak jar (BD, USA). For liquid culture, *H. pylori* was grown in Brucella broth (Difco & BBL Diagnostics, USA) containing 10% FBS and 10  $\mu\text{g}/\text{ml}$  of vancomycin. Cultures were shaken in a microaerobic environment. According to the growth curve,  $2 \times 10^7$  bacteria were collected and resuspended in 250  $\mu\text{l}$  of Brucella broth, which was introduced via intragastric gavage to produce infection after the mice had fasted for 24 h.

### Determining the Number of Viable *H. pylori* in the Stomach

The number of viable *H. pylori* colonies in the stomachs of the mice was determined as previously described, with minor



**Fig. 2.** Gross changes in food intake and body weight in mice during the experimental period. (A) Food intake change. (B) Body weight change. Data are presented as the means  $\pm$  SD. \* indicates a significant difference at  $p < 0.05$ .

modifications [29]. After the mice had fasted for 18 h, they were euthanized, and their stomachs were excised. The stomach was dissected along the greater curvature, the forestomach was removed, and the stomachs were washed with 0.01 M of phosphate-buffered saline (pH 7.4) and then divided into two halves longitudinally. One half of each stomach was homogenized in 1 ml of Brucella broth using a homogenizer (Kinematica, Switzerland). The diluted homogenates were applied to horse blood agar plates used to culture *H. pylori* and were supplemented with 100  $\mu$ g/ml of vancomycin, 100  $\mu$ g/ml of bacitracin, and 10  $\mu$ g/ml of nalidixic acid. The plates were incubated at 37°C under microaerobic conditions for 5 days. The colonies were counted, and the number of viable *H. pylori* was expressed as colony-forming units (CFU) per gram of stomach tissue.

#### Histological Analysis

The remaining half of each stomach was fixed in 10% neutral buffered formalin and embedded in paraffin. The paraffin was cut into 4  $\mu$ m sections and stained with hematoxylin and eosin for morphological observation. Two aspects of gastric lesions were recorded according to the updated Sydney system: the infiltration of polymorphonuclear leukocytes (PMNs) and chronic inflammation based on mononuclear cell infiltration. Morphological features of the gastric antrum and corpus were graded on a scale of 0 to 4: Grade 0, normal; Grade 1, slight; Grade 2, mild; Grade 3, moderate; and Grade 4, severe [7]. Microscopic images were obtained at magnifications of  $\times 100$  for the corpus and  $\times 200$  for the antrum.

#### Statistical Analysis

The SPSS statistics ver. 23 program (IBM, USA) was used for all statistical analyses. Analysis of variance was used to compare different groups, and multiple comparisons were performed using Scheffé's method. A  $p$ -value of  $< 0.05$  was regarded as statistically significant.

## Results

### Gross Changes in Food Intake and Body Weight of Mice

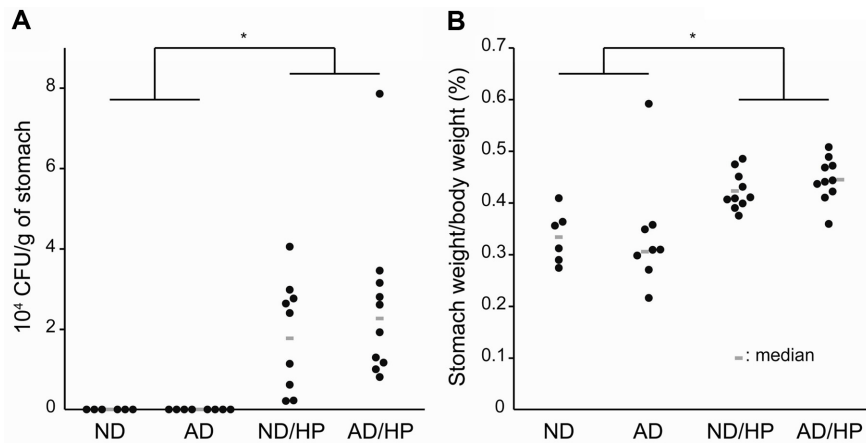
We measured the food intake and body weight of the mice over 10 weeks to determine whether feeding AN caused any gross changes in these values. During this period, food intake was similar in all four groups of mice (Fig. 2A). The body weight increased in the AD group as compared with the ND group (Fig. 2B). Thus, importantly, the ND/HP and AD/HP groups showed no difference in either food intake or weight gain.

### Effect of AN on Viable *H. pylori* Colonization in the Mouse Stomach

To determine the effect of AN on *H. pylori* colonization in the gastric mucosa of mice, the number of *H. pylori* colonies was measured at 10 weeks after the mice had been fed the normal or AN-containing diet. Obviously, the ND/HP and AD/HP groups infected with *H. pylori* showed a significant increase in *H. pylori* colonization as compared with the ND and AD groups without *H. pylori* infection (Fig. 3A). However, there was no significant difference between the ND/HP and AD/HP groups infected with *H. pylori*, suggesting that AN treatment had no effect on *H. pylori* colonization.

### Effect of AN on Stomach Weight of *H. pylori*-Infected Mice

To determine the effect of AN on the stomach weight of the mice infected with *H. pylori*, the stomachs were weighed at 10 weeks after the mice had been fed either the normal or the AN-containing diet, with results expressed as the ratio of stomach weight to body weight. The stomach weight in



**Fig. 3.** Viable number of *H. pylori* colonies in the gastric mucosa, and the ratio of stomach weight to body weight in the *H. pylori*-infected mice.

(A) Viable *H. pylori* colonization was evaluated by means of a whole stomach culture system. (B) Stomachs were weighed at 10 weeks after the mice were fed a normal or AN-containing diet, and results were expressed as the ratio of stomach weight to body weight in the *H. pylori*-infected mice. \* indicates a significant difference at  $p < 0.05$ .

the ND/HP and AD/HP groups infected with *H. pylori* was significantly increased (Fig. 3B); however, there was no significant difference between these two groups, suggesting that AN treatment did not affect gross stomach weight.

#### Effect of AN on Gastric Lesions of *H. pylori*-Infected Mice

To determine whether AN affects *H. pylori*-induced gastric lesions, we observed the histopathological changes (*i.e.*, infiltration of PMNs and mononuclear cells) in the corpus and antrum (Figs. 4A and 4B). Although PMN infiltration was similar in all four groups of mice, mononuclear cell infiltration was significantly increased in the ND/HP and AD/HP groups as compared with the mice in non-infected groups (Figs. 4C and 4D). More importantly, the mononuclear cell infiltration was more severe in the AD/HP group than in the ND/HP group (Fig. 4D). In addition, it is worth noting that no hyperplastic or metaplastic lesions were observed in any group throughout the experimental period.

## Discussion

The distinctive characteristic of *H. pylori* infection is chronic gastric inflammation [26]. Various animal models have been employed to investigate human *H. pylori* infection. Recently, it was reported that certain *H. pylori* strains were able to colonize the gastric mucosa of mice [23] and of Mongolian gerbils [30]. Of the several animal models infected with *H. pylori*, mice appear to have mild responses in terms of gastric inflammation [9]. The commonly used mouse-adapted strain is *H. pylori* SS1, which does not

translocate cytotoxin-associated gene A (CagA), a virulence factor, into the host cells or induce interleukin (IL)-8 [6]. Since the presence of the functional CagA in *H. pylori* strains is associated with more severe gastric inflammation and the development of neoplastic gastric disease [4, 26], the *H. pylori* PMSS1 strain with a functional CagA in vivo system has been employed for the mouse model [2].

In this mouse study, this PMSS1 strain induced moderate chronic inflammation in the animals' gastric mucosa. This finding suggests that the mice infected with the *H. pylori* PMSS1 strain probably mimic the human's asymptomatic response to CagA-positive *H. pylori* infection. Furthermore, the pre-neoplastic lesions such as glandular hyperplasia and metaplasia were not observed during the period of *H. pylori* infection. To develop pre-neoplastic lesions, it might be necessary for a more long-term infection or infection combined with exposure to carcinogens such as AN.

Among the mice without *H. pylori* infection, those fed AD showed no inflammatory changes as compared with the control ND group during the experimental period. In contrast, in the presence of *H. pylori* infection, the mice fed AD showed more severe lymphocyte infiltration than did the ND/HP group fed a normal diet in the presence of *H. pylori* infection. Previous studies have reported that AN extracts increase the expression of inflammatory cytokines such as tumor necrosis factor- $\alpha$ , IL-1 $\beta$ , IL-6, and IL-8 [5], and *H. pylori* induces the increased production of pro-inflammatory cytokines [13, 15]. Combined with these findings, our data suggest that AN treatment aggravates *H. pylori*-induced gastritis by inducing the increased



conclusion, AN induced severer chronic gastritis infection with the *H. pylori* PMSS1 strain, and the chewing of betel quid containing AN may predispose those infected with *H. pylori* to severe gastric diseases, including gastric cancers.

## Acknowledgments

This study was supported by the Yonsei University College of Dentistry Fund (6-2016-0041).

## References

- Adachi K, Suetsugu H, Moriyama N, Kazumori H, Kawamura A, Fujishiro H, et al. 2001. Influence of *Helicobacter pylori* infection and cetraxate on gastric mucosal blood flow during healing of endoscopic mucosal resection-induced ulcers. *J. Gastroenterol. Hepatol.* **16**: 1211-1216.
- Arnold IC, Lee JY, Amieva MR, Roers A, Flavell RA, Sparwasser T, Muller A. 2011. Tolerance rather than immunity protects from *Helicobacter pylori*-induced gastric preneoplasia. *Gastroenterology* **140**: 199-209.
- Atuma C, Engstrand L, Holm L. 1999. *Helicobacter pylori* extracts reduce gastric mucosal blood flow by a nitric oxide-independent but mast cell- and platelet-activating factor receptor-dependent pathway in rats. *Scand. J. Gastroenterol.* **34**: 1183-1189.
- Blaser MJ, Perez-Perez GI, Kleanthous H, Cover TL, Peek RM, Chyou PH, et al. 1995. Infection with *Helicobacter pylori* strains possessing *cagA* is associated with an increased risk of developing adenocarcinoma of the stomach. *Cancer Res.* **55**: 2111-2115.
- Chang LY, Wan HC, Lai YL, Kuo YF, Liu TY, Chen YT, Hung SL. 2009. Areca nut extracts increased expression of inflammatory cytokines, tumor necrosis factor- $\alpha$ , interleukin-1 $\beta$ , interleukin-6 and interleukin-8, in peripheral blood mononuclear cells. *J. Periodontal Res.* **44**: 175-183.
- Crabtree JE, Ferrero RL, Kusters JG. 2002. The mouse colonizing *Helicobacter pylori* strain SS1 may lack a functional *cag* pathogenicity island. *Helicobacter* **7**: 139-140; author reply 140-131.
- Dixon MF, Genta RM, Yardley JH, Correa P. 1996. Classification and grading of gastritis. The updated Sydney System. International Workshop on the Histopathology of Gastritis, Houston 1994. *Am. J. Surg. Pathol.* **20**: 1161-1181.
- Fernando N, Jayakumar G, Perera N, Amarasingha I, Meedin F, Holton J. 2009. Presence of *Helicobacter pylori* in betel chewers and non betel chewers with and without oral cancers. *BMC Oral Health* **9**: 23.
- Ferrero RL, Thiberge JM, Huerre M, Labigne A. 1998. Immune responses of specific-pathogen-free mice to chronic *Helicobacter pylori* (strain SS1) infection. *Infect. Immun.* **66**: 1349-1355.
- Fox JG, Batchelder M, Marini R, Yan L, Handt L, Li X, et al. 1995. *Helicobacter pylori*-induced gastritis in the domestic cat. *Infect. Immun.* **63**: 2674-2681.
- Franco AT, Israel DA, Washington MK, Krishna U, Fox JG, Rogers AB, et al. 2005. Activation of beta-catenin by carcinogenic *Helicobacter pylori*. *Proc. Natl. Acad. Sci. USA* **102**: 10646-10651.
- Garg A, Chaturvedi P, Gupta PC. 2014. A review of the systemic adverse effects of areca nut or betel nut. *Indian J. Med. Paediatr. Oncol.* **35**: 3-9.
- Guiraldes E, Duarte I, Pena A, Godoy A, Espinosa MN, Bravo R, et al. 2001. Proinflammatory cytokine expression in gastric tissue from children with *Helicobacter pylori*-associated gastritis. *J. Pediatr. Gastroenterol. Nutr.* **33**: 127-132.
- Gupta PC, Warnakulasuriya S. 2002. Global epidemiology of areca nut usage. *Addict. Biol.* **7**: 77-83.
- Harris PR, Smythies LE, Smith PD, Dubois A. 2000. Inflammatory cytokine mRNA expression during early and persistent *Helicobacter pylori* infection in nonhuman primates. *J. Infect. Dis.* **181**: 783-786.
- IARC Working Group on the Evaluation of Carcinogenic Risks to Humans. 1994. Schistosomes, liver flukes and *Helicobacter pylori*. *IARC Monogr. Eval. Carcinog. Risks Hum.* **61**: 1-241.
- IARC Working Group on the Evaluation of Carcinogenic Risks to Humans. 2004. Betel-quid and areca-nut chewing and some areca-nut derived nitrosamines. *IARC Monogr. Eval. Carcinog. Risks Hum.* **85**: 1-334.
- Ji WT, Chuang YC, Chen HP, Lee CC, Chen JYF, Yang SR, et al. 2014. Areca nut extracts exert different effects in oral cancer cells depending on serum concentration: a clue to the various oral alterations in betel quid chewers. *Toxicol. Rep.* **1**: 1087-1095.
- Konturek PC, Brzozowski T, Konturek SJ, Stachura J, Karczewska E, Pajdo R, et al. 1999. Mouse model of *Helicobacter pylori* infection: studies of gastric function and ulcer healing. *Aliment. Pharmacol. Ther.* **13**: 333-346.
- Krakowiak MS, Noto JM, Piazuolo MB, Hardbower DM, Romero-Gallo J, Delgado A, et al. 2015. Matrix metalloproteinase 7 restrains *Helicobacter pylori*-induced gastric inflammation and premalignant lesions in the stomach by altering macrophage polarization. *Oncogene* **34**: 1865-1871.
- Kumar AM, Sravani K, Veena KM, Rao PK, Chatra L, Shenai P, et al. 2015. Areca nut and its effects on the human body. *Am. J. Oral Med. Radiol.* **2**: 10-14.
- Li H, Kalies I, Mellgard B, Helander HF. 1998. A rat model of chronic *Helicobacter pylori* infection. Studies of epithelial cell turnover and gastric ulcer healing. *Scand. J. Gastroenterol.* **33**: 370-378.
- Marchetti M, Arico B, Burrone D, Figura N, Rappuoli R, Ghiara P. 1995. Development of a mouse model of *Helicobacter pylori* infection that mimics human disease. *Science* **267**: 1655-1658.

24. Nelson BS, Heischouer B. 1999. Betel nut: a common drug used by naturalized citizens from India, Far East Asia, and the South Pacific Islands. *Ann. Emerg. Med.* **34**: 238-243.
25. Peek RM Jr, Blaser MJ. 2002. *Helicobacter pylori* and gastrointestinal tract adenocarcinomas. *Nat. Rev. Cancer* **2**: 28-37.
26. Philpott DJ, Belaid D, Troubadour P, Thiberge JM, Tankovic J, Labigne A, Ferrero RL. 2002. Reduced activation of inflammatory responses in host cells by mouse-adapted *Helicobacter pylori* isolates. *Cell. Microbiol.* **4**: 285-296.
27. Serizawa T, Hirata Y, Hayakawa Y, Suzuki N, Sakitani K, Hikiba Y, et al. 2015. Gastric metaplasia induced by *Helicobacter pylori* is associated with enhanced SOX9 expression via interleukin-1 signaling. *Infect. Immun.* **84**: 562-572.
28. Shafique K, Mirza SS, Vart P, Memon AR, Arain MI, Tareen MF, Haq ZU. 2012. Areca nut chewing and systemic inflammation: evidence of a common pathway for systemic diseases. *J. Inflamm. (Lond.)* **9**: 22.
29. Takahashi S, Keto Y, Fujita H, Muramatsu H, Nishino T, Okabe S. 1998. Pathological changes in the formation of *Helicobacter pylori*-induced gastric lesions in Mongolian gerbils. *Dig. Dis. Sci.* **43**: 754-765.
30. Watanabe T, Tada M, Nagai H, Sasaki S, Nakao M. 1998. *Helicobacter pylori* infection induces gastric cancer in Mongolian gerbils. *Gastroenterology* **115**: 642-648.