

# Essential Thrombocytosis-Associated Thromboembolism in the Abdominal Aorta

Byung Kwon Chong, M.D.<sup>1</sup>, Dana Mun, M.D.<sup>1</sup>, Chae Hoon Kang, M.D.<sup>2</sup>,  
Chong-bin Park, M.D.<sup>3</sup>, Won Chul Cho, M.D.<sup>3</sup>

<sup>1</sup>Department of Thoracic and Cardiovascular Surgery, Asan Medical Center, University of Ulsan College of Medicine, Departments of <sup>2</sup>Radiology and <sup>3</sup>Thoracic and Cardiovascular Surgery, Gangneung Asan Hospital, University of Ulsan College of Medicine

Essential thrombocytosis (ET) is a myeloproliferative disorder characterized by an anomalous increase in platelet production. Many patients with ET are asymptomatic. Few studies have reported ET-associated thromboembolism in large vessels such as the aorta. We report a patient with ET who presented with peripheral embolism from an abdominal aortic thrombus and developed acute limb ischemia. The patient underwent aortic replacement successfully. The patient's platelet count was controlled with hydroxyurea, and no recurrence was noted over 2 years of follow-up.

**Key words:** 1. Thrombocythemia, Essential  
2. Thrombocytosis  
3. Embolism  
4. Platelets  
5. Aorta

## Case report

A 60-year-old man presented to the emergency room with a sudden onset of intractable pain in the left leg. The patient had a history of intermittent abdominal pain and hypertension without other risk factors for atherosclerosis. A computed tomographic angiogram (CTA) revealed chronic total occlusion of the abdominal aorta from the inferior mesenteric artery level to the level of both common iliac arteries (Fig. 1A). The CTA also showed chronic total occlusion of the left external iliac artery and acute total occlusion of the left popliteal artery (Fig. 1B). Through an endovascular thrombectomy, the popliteal artery occlusion was removed, and angiography confirmed

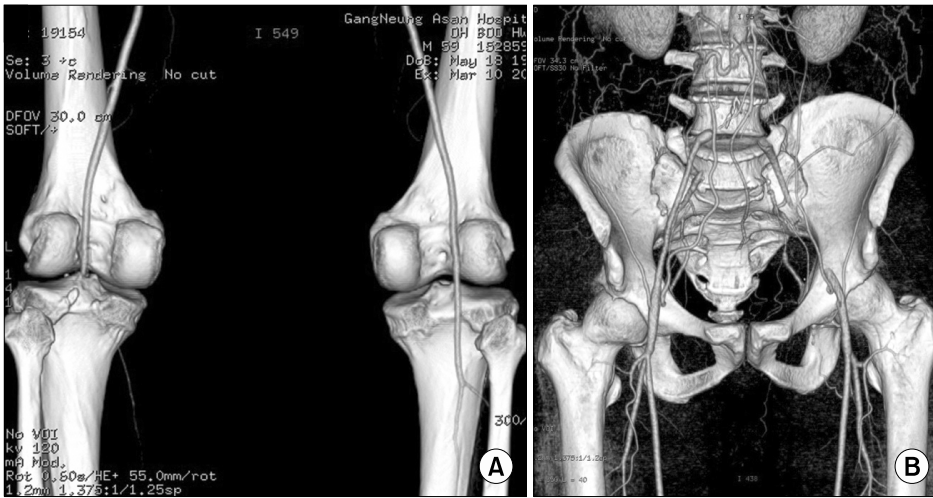
good distal run-off through the anterior and posterior tibial arteries (Fig. 2B). However, 3 days after the procedure, the patient suffered from the same intractable pain in the left leg. Repeated femoral angiography showed a recurrence of the acute total occlusion of the left popliteal artery. After repeated endovascular treatment, urgent surgery was performed to prevent the reoccurrence of thromboembolism. Exploration of the abdominal aorta found fresh white clots that were adherent to the aortic wall (Fig. 3A). Resection of the abdominal aorta below the inferior mesenteric artery was followed by aortic replacement with a 20×10×10-mm Dacron Y graft (Meadox Medicals, Oakland, NJ, USA). Distal anastomosis of the right and left arteries was performed on the common iliac

Received: October 19, 2015, Revised: November 9, 2015, Accepted: November 10, 2015, Published online: October 5, 2016

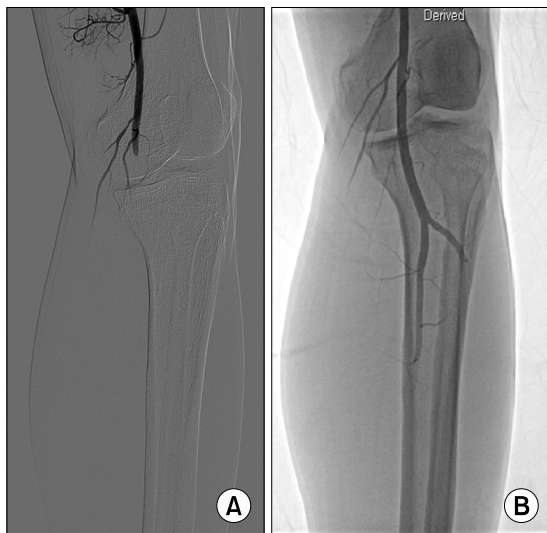
Corresponding author: Won Chul Cho, Department of Thoracic and Cardiovascular Surgery, Gangneung Asan Hospital, University of Ulsan College of Medicine, 38 Bangdong-gil, Gangneung 25440, Korea  
(Tel) 82-33-610-3267 (Fax) 82-33-641-8070 (E-mail) [chomedy@hanmail.net](mailto:chomedy@hanmail.net)

© The Korean Society for Thoracic and Cardiovascular Surgery. 2016. All right reserved.

© This is an open access article distributed under the terms of the Creative Commons Attribution Non-Commercial License (<http://creativecommons.org/licenses/by-nc/4.0>) which permits unrestricted non-commercial use, distribution, and reproduction in any medium, provided the original work is properly cited.



**Fig. 1.** Preoperative computed tomography. (A) Chronic total occlusion of the left external iliac artery. (B) Acute total occlusion of the left popliteal artery.



**Fig. 2.** (A) Angiography after endovascular thrombectomy. (B) Good distal run-off in the anterior and posterior tibial arteries.

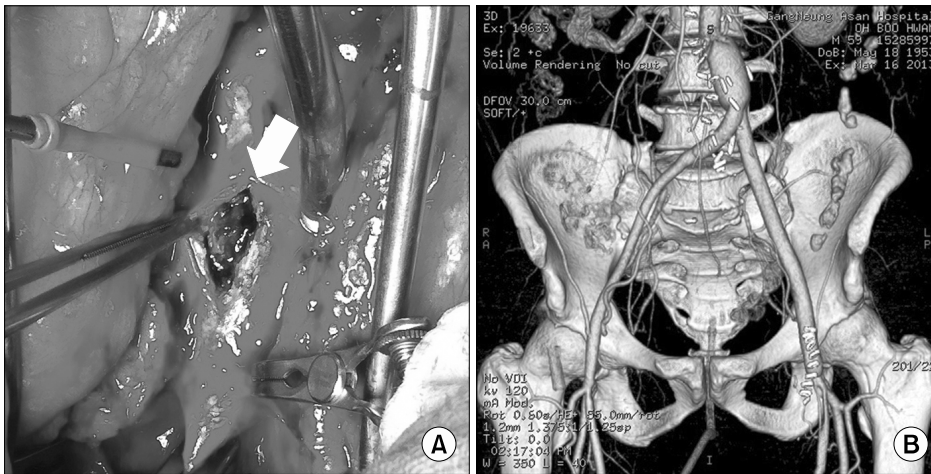
artery and common femoral artery levels, respectively (Fig. 3B). The patient complained of no specific symptoms or signs after the operation. However, due to the abnormal ranges of the platelet count since the first day of admission (ranging from  $533 \times 10^3 / \mu\text{L}$  to  $1,149 \times 10^3 / \mu\text{L}$ ), a bone marrow biopsy was performed postoperatively. The exam showed markedly increased numbers of megakaryocytes, which were clustered with mature cytoplasm and hyper-lobulated nuclei. However, the clusters lacked hematopoietic cells. A cytogenetic study revealed the patient was heterozygous for the  $JAK2^{V617F}$  mutation. Therefore, the final diagnosis of the patient was essential thrombocytosis

(ET), according to the 2008 World Health Organization (WHO) diagnostic criteria. Medical therapy was started immediately with hydroxyurea and aspirin once daily at doses of 1,000 mg and 100 mg, respectively. The platelet count decreased gradually and the patient was discharged on postoperative day 17 without any complications. The therapeutic target for the platelet count ( $<400 \times 10^3 / \mu\text{L}$ ) was achieved 2 months after surgery. On the last follow-up, more than 2 years after the operation, the patient was in good condition with a patent graft (Fig. 4) and controlled platelet counts (from  $219 \times 10^3 / \mu\text{L}$  to  $252 \times 10^3 / \mu\text{L}$ ).

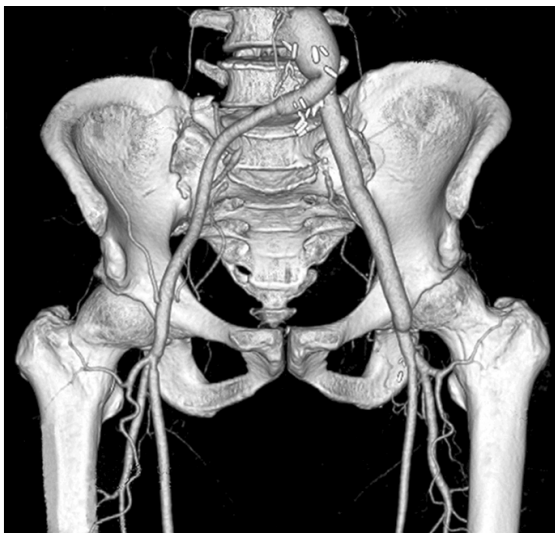
## Discussion

ET is an uncommon myeloproliferative disorder in which a proliferation of megakaryocytes in the bone marrow leads to an elevated platelet count. ET is defined by the following 4 major criteria [1]: (1) platelet count  $\geq 450 \times 10^3 / \mu\text{L}$ ; (2) megakaryocyte proliferation with large and mature morphology, and little to no granulocyte or erythroid proliferation; (3) not meeting the 2008 WHO criteria for chronic myelogenous leukemia, polycythemia vera, primary myelofibrosis, myelodysplastic syndromes, or any other myeloid neoplasm; and (4) demonstration of  $JAK2^{V617F}$  or other clonal markers, or no evidence of reactive thrombosis.

In general, common causes of aortic thrombosis include cardiac sources of embolism, hypercoagulable states, and other complications from atherosclerotic disease. Although ET remains an uncommon cause of



**Fig. 3.** (A) Intraoperative image of fresh white clots in the abdominal aorta (arrow). (B) Postoperative computed tomography.



**Fig. 4.** Follow-up computed tomography 2 years after the operation.

aortic pathology, some reports have discussed cases of ET-associated aortic mural thrombus [2,3]. To the best of our knowledge, this is the first such case report in Korea.

In our case, ET caused a chronic obstruction of the abdominal aorta and acute obstruction of the arteries. We encountered a fast recurrence of artery occlusion (3 days after thrombus removal). We would have been able to prevent the recurrence of popliteal artery occlusion if we had immediately controlled the platelet count. Thus, early diagnosis and prompt treatment is essential in cases of ET. Many options exist for managing ET, such as medical therapy with heparin anticoagulation, aspirin, and cytoreductive

chemotherapy [2,4], and surgical treatment with aortic thrombectomy [3,5] and/or endovascular surgery [6].

In order to ensure the optimal treatment of ET, the location of the thrombus, potential for embolism, individual risk of the patient, and the pathology of the thrombus should all be considered jointly [3,5]. We decided to perform surgical treatment due to the rapid formation of the thrombus, the location of the original chronic thrombus, and the insufficiency of endovascular treatment.

According to Harrison et al. [7], hydroxyurea and low-dose aspirin are superior to other combinations of drugs for patients with ET at high risk for vascular events, especially arterial thrombosis. In our case, once the diagnosis of ET was made, the patient was treated with hydroxyurea and low-dose aspirin for a goal platelet count of  $<400 \times 10^3 / \mu\text{L}$ . The patient's platelet count was normalized and maintained within a range of  $219 \times 10^3 / \mu\text{L}$  to  $252 \times 10^3 / \mu\text{L}$ .

In conclusion, although ET rarely presents in large vessels, early diagnosis and immediate management are essential.

### Conflict of interest

No potential conflict of interest relevant to this article was reported.

### References

1. Tefferi A, Thiele J, Orazi A, et al. *Proposals and rationale for revision of the World Health Organization diagnostic criteria for polycythemia vera, essential thrombocythemia,*

- and primary myelofibrosis: recommendations from an ad hoc international expert panel.* Blood 2007;110:1092-7.
2. Lorelli DR, Shepard AD. *Aortic mural thrombus embolization: an unusual presentation of essential thrombocytosis.* Ann Vasc Surg 2002;16:375-9.
  3. Morata Barrado PC, Blanco Canibano E, Garcia Fresnillo B, Guerra Requena M. *Acute lower limb ischemia in a patient with aortic thrombus and essential thrombocytosis.* Int J Hematol 2009;90:343-6.
  4. Oki M, Moriuchi M, Kawada H, Ogawa Y, Ando K. *A case of essential thrombocythemia presenting with aortic thrombosis.* Tokai J Exp Clin Med 2008;33:135-7.
  5. Sohn V, Arthurs Z, Andersen C, Starnes B. *Aortic thrombus due to essential thrombocytosis: strategies for medical and surgical management.* Ann Vasc Surg 2008;22:676-80.
  6. Luebke T, Aleksic M, Brunkwall J. *Endovascular therapy of a symptomatic mobile thrombus of the thoracic aorta.* Eur J Vasc Endovasc Surg 2008;36:550-2.
  7. Harrison CN, Campbell PJ, Buck G, et al. *Hydroxyurea compared with anagrelide in high-risk essential thrombocythemia.* N Engl J Med 2005;353:33-45.