

Delayed Surgery for Aortic Dissection after Intravenous Thrombolysis in Acute Ischemic Stroke

Nari Choi, M.D.¹, Jee-Eun Yoon, M.D.¹, Byoung-Won Park, M.D.²,
Won-Ho Chang, M.D.³, Hyun-Jo Kim, M.D.³, Kyung Bok Lee, M.D.¹

Departments of ¹Neurology, ²Cardiology, and ³Thoracic Surgery, Soonchunhyang University Hospital,
Soonchunhyang University School of Medicine

We report a case of aortic dissection masquerading as acute ischemic stroke followed by intravenous thrombolysis. A 59-year-old man presented with dizziness. After examination, the patient had a seizure with bilateral Babinski signs. Soon after identifying multiple acute infarctions in both hemispheres on diffusion-weighted brain magnetic resonance (MR) imaging, tissue plasminogen activator (t-PA) was administered. Both common carotid arteries were invisible on MR angiography, and subsequent chest computed tomography revealed an aortic dissection. The emergency operation was delayed for 13 hours due to t-PA administration. The patient died of massive bleeding.

Key words: 1. Aortic dissection
2. Stroke
3. Thrombolysis

Case report

A 59-year-old male patient visited emergency room of Soonchunhyang University Seoul Hospital for slight uneasiness in the chest and vertigo. He was fully conscious and no neurological findings were observed. The patient's blood pressure was 77/66 mmHg, which was quite low; however, it recovered to 102/65 mmHg with a heart rate of 40 beats per minute with fluid therapy. Second-degree atrioventricular block was observed in the electrocardiogram. No abnormalities were observed in myocardial enzyme levels or in a standard blood examination. The department of emergency medicine collaborated with the department of cardiology to treat this patient. The patient was scheduled to be hospitalized in the cardiology ward for coronary angiography because Mobitz type II at-

rioventricular block and unstable angina were suspected.

The patient had a sudden convulsive seizure while waiting to be hospitalized. The seizure did not stop for more than 5 minutes, during which lorazepam was administered. The patient did not have a history of seizure, heavy drinking, or trauma. After the seizure, while in a semicomatose state, quadriplegia and the Babinski sign were observed. In order to determine whether the convulsive seizure was accompanied by an acute stroke, diffusion-weighted magnetic resonance imaging was performed. Multiple cerebral infarctions were found in both the frontal and temporal lobes (Fig. 1A, B). Tissue plasminogen activator (t-PA) was administered promptly (within 90 minutes after symptom occurrence), and magnetic resonance angiography (MRA) was conducted while intravenous thrombol-

Received: January 20, 2016, Revised: April 26, 2016, Accepted: April 26, 2016, Published online: October 5, 2016

Corresponding author: Kyung Bok Lee, Department of Neurology, Soonchunhyang University Hospital, Soonchunhyang University School of Medicine, 59 Daesagwan-ro, Yongsan-gu, Seoul 04401, Korea
(Tel) 82-2-709-9026 (Fax) 82-2-709-9226 (E-mail) kblee@schmc.ac.kr

© The Korean Society for Thoracic and Cardiovascular Surgery. 2016. All right reserved.

© This is an open access article distributed under the terms of the Creative Commons Attribution Non-Commercial License (<http://creativecommons.org/licenses/by-nc/4.0>) which permits unrestricted non-commercial use, distribution, and reproduction in any medium, provided the original work is properly cited.

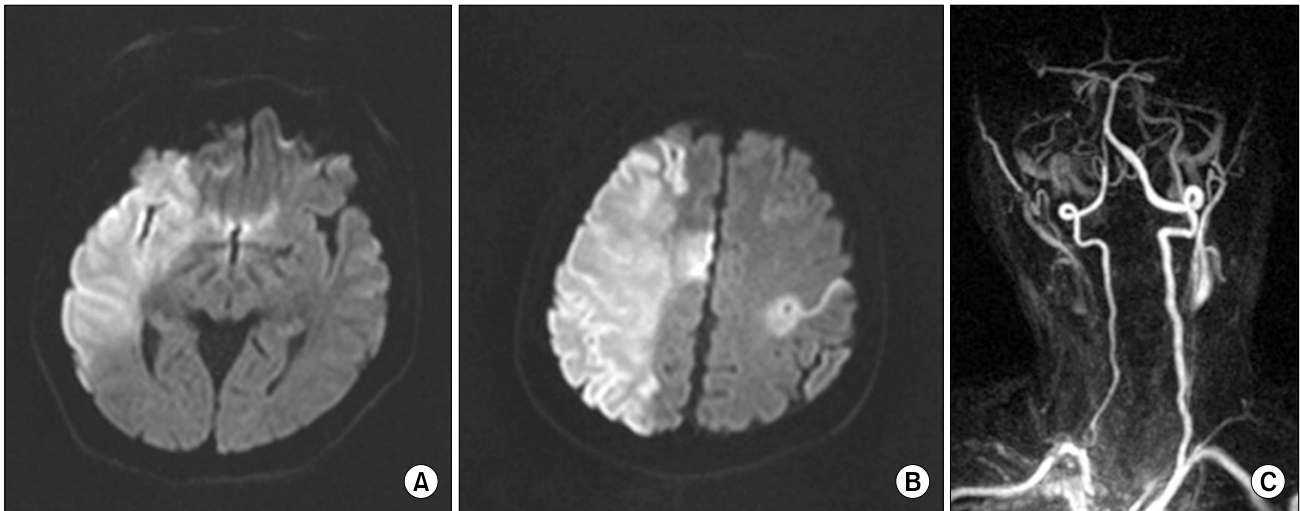


Fig. 1. (A, B) Diffusion-weighted imaging revealed multiple acute infarctions in the bilateral frontal and temporal lobes, especially in the territory of the in whole territory of the right middle cerebral artery. (C) On magnetic resonance angiography, both common carotid arteries were invisible.

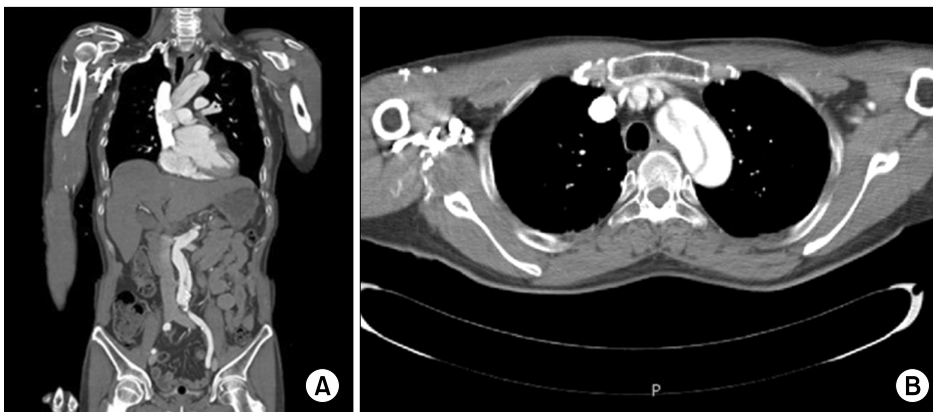


Fig. 2. A Stanford type A aortic dissection documented on (A) a coronal and (B) an axial chest computed tomography scan.

ysis was performed. Forty minutes after t-PA administration, the common carotid arteries on bilateral sides showed no contrast on the MRA (i.e., the arteries were invisible on the scan), and aortic dissection was suspected (Fig. 1C).

Stanford type A aortic dissection, which requires an immediate emergency operation, was observed on chest computed tomography (CT) (Fig. 2). However, the operation was postponed due to the high bleeding risk caused by the thrombolytic agent; the operation was finally conducted 13 hours later. The patient expired 4 hours after the termination of the operation due to excessive bleeding.

Discussion

Aortic dissection generally presents with sudden and severe pain. In the case where the aortic dissection invades the ascending aorta, mortality may be as high as 40%–50% if appropriate emergency medical treatment is not obtained promptly [1]. In an aortic dissection, various abnormal neurological findings can occur, and ischemic cerebral infarction is the most frequently observed such finding. However, 10%–55% of all aortic dissection cases are painless. When a patient seeks care for mental deterioration or language disturbance, the diagnosis of an aortic dissection can be quite difficult.

Thrombolysis, conducted to treat acute cerebral in-

farction, may sometimes be applied without understanding the secondary cause of cerebral infarction due to limited time. The effects of thrombolysis on aortic dissection patients have not been reported widely [2].

Carotid or vertebral dissection is not an absolute contraindication for intravenous thrombolysis. Intracranial hemorrhage and recurrent infarction in patients with carotid dissection were found to occur approximately as frequently as in patients without carotid dissection [3]. The Safe Implementation of Thrombolysis in Stroke-Monitoring Study also reported that the occurrence of adverse effects was similar with or without intravenous thrombolysis in patients with cerebral infarction caused by carotid or vertebral dissection [4].

Myocardial infarction in patients with an aortic dissection is a contraindication for intravenous thrombolysis. In previous studies, it was reported that thrombolysis could cause hemopericardium or cardiac tamponade by aortic rupture [5]. Thrombolysis could reduce the patient's possibility of survival by leading to the postponement of an emergency operation to treat a Stanford Type A aortic dissection [4].

Antiplatelet or anticoagulant agents, which have lower bleeding risks than t-PA, can have higher bleeding risks during aortic surgery. In the case of cardiac procedures such as coronary artery bypass grafting, the amount of bleeding and transfusion volume were higher in patients who continued antiplatelet medication than in those who had discontinued medication 7 days prior to the procedure [3]. The amount of bleeding during aortic surgery can be massive; usage of t-PA before surgery is likely to significantly increase hemorrhagic complications and mortality.

However, few reports have been published concerning cerebral infarction caused by aortic dissection. Cases in which intravenous thrombolysis were conducted without knowing that aortic dissection was present in patients with acute cerebral infarction are summarized in Table 1. Although many patients exhibit a tendency for increased bleeding, no consensus exists regarding the optimal timing for major cardiac surgery after the administration of t-PA. T-PA was administered to a total of 7 patients prior to diagnosis with an aortic dissection. Complete doses of t-PA were infused in 2 patients and administration

ceased in 5 patients because they were diagnosed with an aortic dissection. Of the 2 patients who received full dosages of t-PA, 1 of them underwent surgery within 3 days and recovered to independent ambulation (modified Rankin Score [mRS], 3 points). However, the other patient died without undergoing surgery. Among the 5 patients who received partial doses of t-PA, emergency operations were conducted for 3 patients, while 1 patient underwent surgery after 24 hours. The other patient did not undergo surgery due to the caregiver's refusal. The 3 patients who underwent surgery had a mRS of 0, 3, and 4 points, respectively, and the patient who underwent surgery after 24 hours recovered to a nearly normal status. Therefore, unlike previous cases that had a relatively positive prognosis, this case represents the first case in which a patient expired after aortic surgery and t-PA administration. Since a total dose of 63 mg of t-PA was applied, the operation was delayed for 13 hours, and excessive hemorrhage following the operation was the cause of death. Despite the fact that the half-life of t-PA in blood is short, it is possible that a tendency for increased bleeding persists for an additional 1-2 days. In this case, however, the increased size of the hemopericardium and the enlarged extent of the cerebral infarction made an emergency operation inevitable. All doses of t-PA were administered to this patient, and it is thought that the reduced time delay before the operation increased the patient's bleeding risk. Henceforth, t-PA usage in patients with cerebral infarction accompanied with an aortic dissection will not be recommended in treatment guidelines.

In an aortic dissection, cerebral infarctions can be caused by mechanical occlusion of the common carotid artery and vertebral artery, or by relatively low cerebral perfusion. Approximately 1 out of 3 patients who have neurologic symptoms from an aortic dissection do not feel chest pain [6]. A cerebral infarction caused by an aortic dissection usually occurs in the right hemisphere through infiltration into the right common carotid artery; however, it can also occur in both sides (as in this case) [7]. In order to diagnose an aortic dissection without symptoms in patients with acute cerebral infarctions, the pulse difference between both radial arteries should be confirmed, physical examinations including heart murmur auscultation should be performed, and observa-

Table 1. Summary of cases where intravenous thrombolysis without knowledge that an aortic dissection was present

Age (yr)/sex	Initial symptom	NIHSS	Tissue plasminogen activator dose	Surgery	Outcome	Reference
44/M	Lt. hemiparesis	18	Loading dose	Emergency operation	mRS 3	Chua et al. [11] (2005)
56/F	Lt. hemiparesis	16	Loading dose, 5 mg	Emergency operation	mRS 4	Uchino et al. [12] (2005)
81/F	Lt. hemiparesis	22	Total dose	Delayed operation (3 days)	mRS 3	Noel [13] (2010)
80/F	Decreased level of consciousness	16	15 mg	Refused	Death	Rodríguez-Luna et al. [14] (2011)
54/M	Right hemiparesis	-	Total dose, 72 mg	(-) ^{a)}	Death ^{b)}	Fessler and Alberts [15] (2000)
69/F	Lost consciousness	6	60% of total dose	Emergency operation	NIHSS 0	Hong et al. [16] (2009)
38/M	Lt. hemiparesis	13	Loading dose	Delayed operation (24 hours)	Near total recovery	Chinchure et al. [17] (2013)

NIHSS, National Institute of Health Stroke Scale; M, male; Lt., left; mRS, modified Rankin Score; F, female.

^{a)}The patient was a poor surgical candidate due to being in a comatose state. ^{b)}In accordance with the family's wishes, the patient was extubated and died 6 days after admission.

tions such as a ST segment increase in echocardiography and expanded mediastinum in simple chest radiography should be confirmed [8]. In cases of aortic dissection seen in practice, the pulse disappeared in only 15% of patients, a heart murmur was present in 31% of patients, and electrocardiography was normal in 31% of patients [1]. In addition, chest X-rays showed abnormal findings in 50% of patients [9]; thus, it is difficult to rely on simple examinations alone when diagnosing aortic dissection. Chest angiography using CT or magnetic resonance can acquire and confirm images around the aorta directly, and may be the only useful method for diagnosis if atypical symptoms are observed [10]. We initially performed transthoracic echocardiography on this patient with symptoms of dizziness in the emergency room, and we did not check the suprasternal view or carotid artery to rule out aortic dissection. We should have suspected aortic dissection during the first echocardiography.

In some cases, an intimal fragment is observed in the extracranial MRA in aortic dissection [10], and it is also possible that the bilateral sides of the common carotid artery are not seen simultaneously (as in this case). Findings such as these are rare in cardiac embolism or atherosclerosis. If there is a finding of occlusion of the common carotid artery along with multiple cerebral infarctions in both hemispheres, the physician must consider the possibility of aortic disease [7]. Additionally, the right side of the aorta tends to be more severely infiltrated. Aortic dissection should be suspected if a cerebral infarction is significantly more severe in the right hemisphere

than in the left hemisphere.

It is difficult to diagnose an aortic dissection before the administration of t-PA if the patient exhibits neither typical chest pains nor abnormal findings in laboratory tests. No consensus exists regarding the optimal timing of major cardiac surgery after thrombolysis. We recommend that emergency operations should be postponed for at least 24 hours after t-PA administration. Cardiac diseases such as aortic dissection must be ruled out before emergency thrombolysis is performed to treat acute ischemic stroke.

We report a case in which we encountered difficulties during emergency surgery. Aortic dissection was diagnosed after intravenous thrombolysis in a patient who presented to the emergency room for convulsive seizure and multiple cerebral infarctions without typical severe chest pain.

Conflict of interest

No potential conflict of interest relevant to this article was reported.

References

1. Hagan PG, Nienaber CA, Isselbacher EM, et al. *The International Registry of Acute Aortic Dissection (IRAD): new insights into an old disease.* JAMA 2000;283:897-903.
2. Grupper M, Eran A, Shifrin A. *Ischemic stroke, aortic dissection, and thrombolytic therapy: the importance of basic clinical skills.* J Gen Intern Med 2007;22:1370-2.
3. Badreldin A, Kroener A, Kamiya H, Lichtenberg A, Hekmat K. *Effect of clopidogrel on perioperative blood loss and transfusion in coronary artery bypass graft surgery.*

- Interact Cardiovasc Thorac Surg 2010;10:48-52.
4. Tsvigoulis G, Safouris A, Alexandrov AV. *Safety of intravenous thrombolysis for acute ischemic stroke in specific conditions.* Expert Opin Drug Saf 2015;14:845-64.
 5. Marian AJ, Harris SL, Pickett JD, Campbell E, Fromm RE. *Inadvertent administration of rtPA to a patient with type 1 aortic dissection and subsequent cardiac tamponade.* Am J Emerg Med 1993;11:613-5.
 6. Gaul C, Dietrich W, Friedrich I, Sirch J, Erbguth FJ. *Neurological symptoms in type A aortic dissections.* Stroke 2007;38:292-7.
 7. Gaul C, Dietrich W, Erbguth FJ. *Neurological symptoms in aortic dissection: a challenge for neurologists.* Cerebrovasc Dis 2008;26:1-8.
 8. Hiratzka LF, Bakris GL, Beckman JA, et al. *2010 ACCF/AHA/AATS/ACR/ASA/SCA/SCAI/SIR/STS/SVM Guidelines for the diagnosis and management of patients with thoracic aortic disease: a report of the American College of Cardiology Foundation/American Heart Association Task Force on Practice Guidelines, American Association for Thoracic Surgery, American College of Radiology, American Stroke Association, Society of Cardiovascular Anesthesiologists, Society for Cardiovascular Angiography and Interventions, Society of Interventional Radiology, Society of Thoracic Surgeons, and Society for Vascular Medicine.* J Am Coll Cardiol 2010;55:e27-e129.
 9. Khan IA, Nair CK. *Clinical, diagnostic, and management perspectives of aortic dissection.* Chest 2002;122:311-28.
 10. Hyland MH, Holloway RG. *Pearls & Oysters: a stroke of luck: detecting type A aortic dissection by MRA.* Neurology 2011;76:e31-3.
 11. Chua CH, Lien LM, Lin CH, Hung CR. *Emergency surgical intervention in a patient with delayed diagnosis of aortic dissection presenting with acute ischemic stroke and undergoing thrombolytic therapy.* J Thorac Cardiovasc Surg 2005;130:1222-4.
 12. Uchino K, Estrera A, Calleja S, Alexandrov AV, Garami Z. *Aortic dissection presenting as an acute ischemic stroke for thrombolysis.* J Neuroimaging 2005;15:281-3.
 13. Noel M, Short J, Farooq MU. *Thrombolytic therapy in a patient with acute ischemic stroke caused by aortic dissection.* Clin Neurol Neurosurg 2010;112:695-6.
 14. Rodríguez-Luna D, Vilar RM, Peinazo M, del Villar A, Claramonte B, Vilar C, Geffner D. *Intravenous thrombolysis in an elderly patient with acute ischemic stroke masking aortic dissection.* J Stroke Cerebrovasc Dis 2011;20:559-61.
 15. Fessler AJ, Alberts MJ. *Stroke treatment with tissue plasminogen activator in the setting of aortic dissection.* Neurology 2000;54:1010.
 16. Hong KS, Park SY, Whang SI, Seo SY, Lee DH, Kim HJ, Cho JY, Cho YJ, Jang WI, Kim CY. *Intravenous recombinant tissue plasminogen activator thrombolysis in a patient with acute ischemic stroke secondary to aortic dissection.* J Clin Neurol 2009;5:49-52.
 17. Chinchure SD, Goel G, Gupta V, Bansal AR, Singh D, Garg A, Jha AN. *Aortic dissection presenting as acute stroke: Careful selection of patients for intravenous thrombolysis.* Neurol India 2013;61:76-7.