

IMAGES

Kabuki Syndrome with Cleft Palate

Joo Myong Paik, So Young Lim

Department of Plastic Surgery, Samsung Medical Center, Sungkyunkwan University School of Medicine, Seoul, Korea

Correspondence: So Young Lim
 Department of Plastic Surgery, Samsung Medical Center, Sungkyunkwan University School of Medicine, 81 Irwon-ro, Gangnam-gu, Seoul 06351, Korea
 Tel: +82-2-3410-2239, Fax: +82-2-3410-0036
 E-mail: pslisy@naver.com

No potential conflict of interest relevant to this article was reported.

Received: 11 Apr 2016 • Revised: 22 Jun 2016 • Accepted: 28 Jun 2016
 pISSN: 2234-6163 • eISSN: 2234-6171
<http://dx.doi.org/10.5999/aps.2016.43.5.474>
 Arch Plast Surg 2016;43:474-476



Copyright © 2016 The Korean Society of Plastic and Reconstructive Surgeons
 This is an Open Access article distributed under the terms of the Creative Commons Attribution Non-Commercial License (<http://creativecommons.org/licenses/by-nc/4.0/>) which permits unrestricted non-commercial use, distribution, and reproduction in any medium, provided the original work is properly cited.

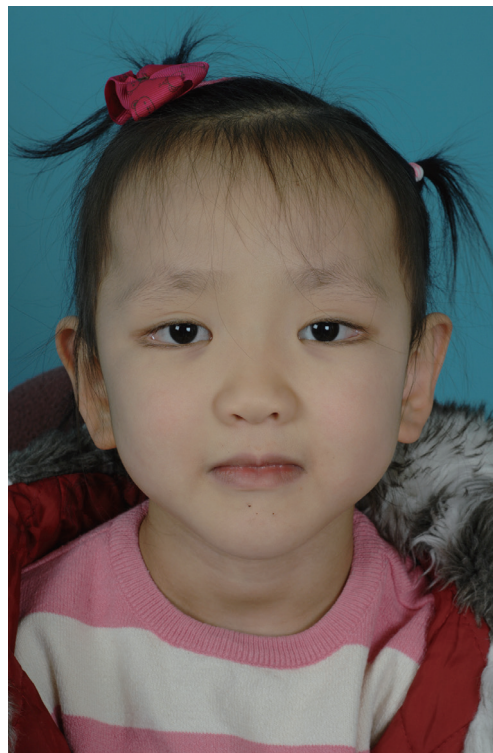Kabuki syndrome is a rare condition characterized by multiple congenital anomalies and intellectual disabilities [1]. The etiology of Kabuki syndrome is unclear, but the syndrome is known to have an autosomal dominant mode of inheritance. Furthermore, mutations in the *MLL2* and *KDM6A* genes have recently been suggested as causes of this

syndrome [2]. The five major clinical manifestations of this condition are distinctive facial features, skeletal anomalies, dermatoglyphic abnormalities, short stature, and intellectual disability.

Among these characteristics, the peculiar facial features that are common in all the patients presenting with Kabuki syndrome are the most striking and noticeable aspects of this syndrome. These include long palpebral fissures with lower lateral eyelid eversion, arched eyebrows with the lateral one-third dispersed or sparse, prominent ears, and a short columella with a depressed nasal tip. Because the facial appearance of a person with this syndrome resembles the makeup of Kabuki actors, this syndrome is called Kabuki syndrome.

Along with cardinal manifestations, many additional features have been reported. Among these anomalies, cleft palate is a common feature reported in about half of the patients with Kabuki syndrome [3]. However, thus far, only a few reports have discussed cleft palate in Kabuki syndrome patients. The aim of this study is to discuss the cases of five patients of Kabuki syndrome with cleft palate and describe their characteristic facial features.

Between March 2009 and February 2014, five patients (one boy and four girls) with cleft palate associated with Kabuki syndrome visited the plastic surgery clinic at our medical center. The age of the patients ranged from 10 months to 7 years. As shown in Figs. 1 and 2, all these patients had horizontally long palpebral fissures, eversion of the lower lateral eyelid, arched eyebrows with the lateral one-third dispersed, prominent ears, and a low nasal tip, which corresponded to the peculiar facial features of Kabuki syndrome. The patients were diagnosed with Kabuki syndrome on the basis of these facial features and the accompanying anomalies. All five patients presented with developmental delays and congenital heart disease: two patients had a congenital atrial septal defect and one of them underwent surgical correction. Another patient had a history of ventricular septal defects, and the other two had a combination of coarctation of the aorta and a ventricular septal defect, and they all underwent surgery. Other associated anomalies such as congenital scoliosis, diaphragmatic hernia, and multicystic dysplastic kidney were observed in one patient each. None of the patients underwent a genetic evaluation to determine whether there were any *MLL2* or *KDM6A* gene mutations. One patient underwent a genetic test of the *ELN* gene to rule out

**Fig. 1.**

Five-year-old girl with Kabuki syndrome. She underwent two-flap palatoplasty for incomplete cleft palate.

Williams syndrome, but the result was negative.

Of these five patients, two of them presented with overt incomplete cleft palate and another two presented with submucous cleft palate. The other patient had a combination of submucous and incomplete-type cleft palate. All patients had a history of swallowing difficulty and frequent otitis media in infancy. In two of the patients who underwent palatoplasty when they were 20 months and 7 years old, overt hypernasality could be heard. Palatoplasty was performed in all five cases. Two-flap palatoplasty was performed in the incomplete cleft palate cases, and double opposing Z-plasty was performed in the submucous cleft palate cases and the combination of submucous and incomplete-type cleft palate case. No postoperative complication occurred in any of the patients, but one developed velopharyngeal insufficiency that could not be expected to improve by speech therapy, so the patient underwent pharyngeal flap surgery four years after palatoplasty.

Kabuki syndrome is a rare genetic disorder that has been estimated to occur in every 32,000 to 86,000 people. The characteristic facial features of this syndrome make typical cases highly recognizable. We could also easily observe the typical facial features of Kabuki syndrome in this series.

Apart from the typical facial gestalt, this syndrome has such diverse systemic clinical manifestations that include craniofacial abnormalities, such as cleft lip and palate; visceral manifestations, such as cardiac malformation and urogenital abnormalities; skeletal abnormalities, such as scoliosis and abnormalities of the fingers; and immune deficiency [4].

In this study, we reviewed the cases of five patients with Kabuki syndrome who presented with cleft palate. Previous studies observed isolated cleft palate in 50% to 69.7% of the patients and submucous cleft palate in 15.2% to 50% of the patients. Similar to a previous study, our study showed a high ratio of submucous cleft palate among patients having Kabuki syndrome with cleft palate [5]. It should be noted that submucous cleft palate, which can be easily misdiagnosed, should be routinely checked in patients with Kabuki syndrome, due to a high proportion of this population.

Cardiovascular anomalies are known to affect approximately 50% of the patients with Kabuki syndrome [4]. In contrast, a notable finding in this series is that every patient has a history of congenital cardiac defects with varying severity from a simple atrial septal defect that does not necessitate surgical

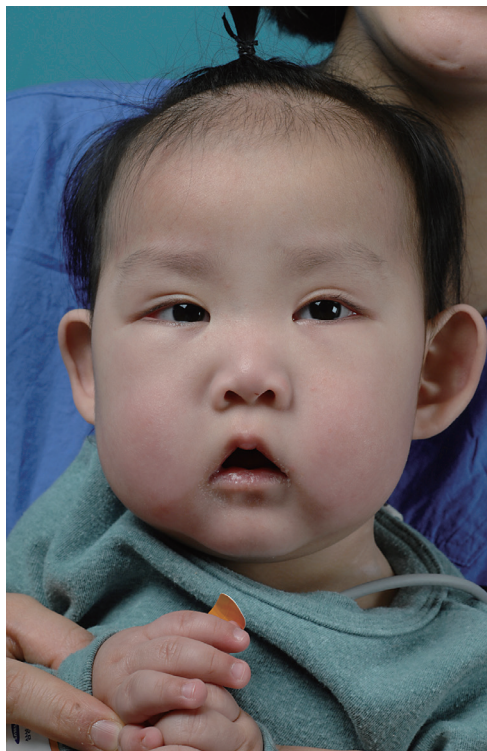

Fig. 2. Twenty-month-old girl with Kabuki syndrome. She underwent two-flap palatoplasty for incomplete cleft palate.

intervention to a combination of multiple cardiac anomalies. This high ratio of cardiac manifestations in patients with Kabuki syndrome with cleft palate may be attributed to a small number of cases studied, and further genetic or molecular studies are necessary to reveal the relationship between different clinical manifestations.

In these five cases of Kabuki syndrome with cleft palate, the facial features are the key aspects that aid the diagnosis of this rare syndrome. In particular, cleft palate is not an unusual presentation in patients with Kabuki syndrome, accounting for up to 50% of the patients with Kabuki syndrome. It is important for pediatricians and plastic surgeons to always be aware of Kabuki syndrome when patients present peculiar and characteristic facial features of this syndrome, to rule out other associated anomalies including cleft palate.

References

1. Niikawa N, Matsuura N, Fukushima Y, et al. Kabuki make-up syndrome: a syndrome of mental retardation, unusual facies, large and protruding ears, and postnatal growth deficiency. *J Pediatr* 1981;99:565-9.
2. Ng SB, Bigham AW, Buckingham KJ, et al. Exome sequencing identifies MLL2 mutations as a cause of Kabuki syndrome. *Nat Genet* 2010;42:790-3.

3. Schrandner-Stumpel CT, Spruyt L, Curfs LM, et al. Kabuki syndrome: clinical data in 20 patients, literature review, and further guidelines for preventive management. *Am J Med Genet A* 2005;132:234-43.
4. Adam MP, Hudgins L. Kabuki syndrome: a review. *Clin Genet* 2005;67:209-19.
5. Iida T, Park S, Kato K, et al. Cleft palate in Kabuki syndrome: a report of six cases. *Cleft Palate Craniofac J* 2006;43:756-61.

Hydrocele of the Canal of Nuck in a Female Adult

Kwang Seog Kim, Jun Ho Choi, Hong Min Kim, Kyung Pil Kim, Yu jin Kwon, Jae Ha Hwang, Sam Yong Lee

Department of Plastic and Reconstructive Surgery, Chonnam National University Medical School, Gwangju, Korea

Correspondence: Kwang Seog Kim
Department of Plastic and Reconstructive Surgery, Chonnam National University Medical School, 42 Jebong-ro, Dong-gu, Gwangju 61469, Korea
Tel: +82-62-220-6363/6352, Fax: +82-62-220-6357
E-mail: pskim@chonnam.ac.kr

No potential conflict of interest relevant to this article was reported.

Received: 14 Jun 2016 • Revised: 22 Aug 2016 • Accepted: 31 Aug 2016
pISSN: 2234-6163 • eISSN: 2234-6171
<http://dx.doi.org/10.5999/aps.2016.43.5.476>
Arch Plast Surg 2016;43:476-478



Copyright © 2016 The Korean Society of Plastic and Reconstructive Surgeons
This is an Open Access article distributed under the terms of the Creative Commons Attribution Non-Commercial License (<http://creativecommons.org/licenses/by-nc/4.0/>) which permits unrestricted non-commercial use, distribution, and reproduction in any medium, provided the original work is properly cited.

The canal of Nuck is a small evagination of the parietal peritoneum, which is attached to the uterus by the round ligament through the internal inguinal ring into the inguinal canal. This structure is homologous to the processus vaginalis of the male anatomy [1].

Although the canal of Nuck normally disappears without a trace in the first year of life, it can cause an

indirect inguinal hernia or hydrocele of the canal of Nuck when, in rare cases, it does not disappear completely. Hydrocele of the canal of Nuck is a rare disease that occurs in the inguinal area or labium as a painless edema before adolescence [2]. We report the case of a hydrocele of the canal of Nuck in a female adult.

A 51-year-old female patient visited our hospital with a complaint of 7 × 4-cm painless swelling in her right groin that had first appeared 4 months previously and had grown in size since then. The mass had not been present in infancy or adolescence. The patient showed severe atrophic changes in her right thigh, groin, and buttocks due to poliomyelitis and had undergone tendon transfer surgery to fix the tendon of the right external oblique muscle to the greater trochanter of the right femur 20 years prior. In addition, a 20-cm oblique scar was observed in the right lower abdomen (Fig. 1). Although the patient did not present with clinical symptoms such as fever, nausea, or vomiting, the swelling in the right groin protruded in the standing position and disappeared in the lying position. Thus, abdominal computed tomography (CT) was performed to distinguish the swelling from hernia. An abdominal CT scan showed a 7.1 × 3.8-cm cystic mass in the right inguinal canal, and lymphangioma or hydrocele of the canal of Nuck was suspected. Abdominal magnetic resonance imaging (MRI) was performed to examine the communication between the cystic mass and peritoneal cavity, and the precise anatomy around the cystic mass. It was found that the cystic mass in the inguinal canal included thin septa, and hydrocele of the canal of Nuck was suspected because of the low and high signal intensities observed on the T₁- and T₂-weighted images, respectively. Only the wall and septa were contrast-enhanced (Fig. 2). The cystic mass was examined histopathologically after high ligation and hydrocelectomy were performed. Then, a diagnostic test was performed by using a fluid sample from the mass (Fig. 3).

The histopathological examination revealed that the tissue was positive for creatine kinase, Wilms tumor protein 1 (WT-1), and D2-40, as well as mesothelial cells (Fig. 4). According to the results of the diagnostic test, the fluid included cellular components similar to those of peritoneal fluid. Based on the imaging, histopathology, and diagnostic testing, we made a diagnosis of hydrocele of the canal of Nuck.

The canal of Nuck was first described by a Dutch

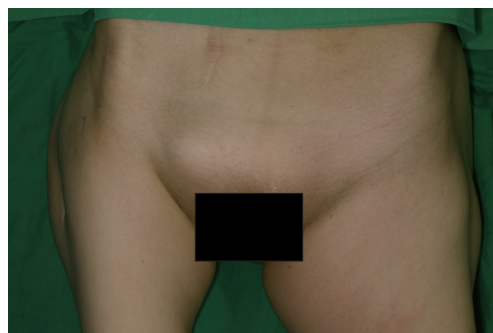


Fig. 1.
Preoperative photograph. A 7 × 4-cm painless swelling is visible in the right groin of the 51-year-old female patient.