

Panner's Disease Occurred in a Five-year-old Child: A Preliminary Case Report

Doo Hyun Kim, Tae Gyun Kim, Youn Moo Heo, Cheol Mog Hwang¹, June Bum Jun, Jin Woong Yi[✉]

Departments of Orthopedic Surgery and ¹Radiology, Konyang University College of Medicine, Daejeon, Korea

Panner's disease, osteonecrosis of the capitellum of the elbow, was first reported by Panner in 1927. The disease occurs mainly in boys between 6 and 15 years old and shows unilateral distribution. Pain, stiffness, localized tenderness over the lateral condyle of the elbow, and decreased range of motion are the typical clinical symptoms. Conservative treatment is generally recommended for patients in the early stage of this disease. A few cases of Panner's disease have been reported and few are related to long-term follow-up results. To the best of our knowledge, all reported cases were over six years. Therefore, we report on a five-year-old boy diagnosed as Panner's disease that showed resorption and regeneration of the humeral capitellum with no limitation of motion over three years. The current study was exempted from review by the institutional review board because it was a single retrospective case report. Informed consent was obtained from the patient's guardian.

(Clin Shoulder Elbow 2016;19(3):176-178)

Key Words: Osteochondrosis; Elbow; Case reports

Panner's disease is rare osteonecrosis of the capitellum of the elbow. The clinical symptoms typically include pain, stiffness, and localized tenderness over the lateral condyle of the elbow, and decreased range of motion.¹⁾ In general, conservative treatment is advised for Panner's disease.²⁾ The disease occurs mainly in boys between 6 and 15 years old and shows unilateral distribution.³⁾ We report on the case of a 5-year-old boy who was younger than the other patients with Panner's disease.

Case Report

A five-year-old boy presented to the outpatient clinic with the complaint of persistent right elbow pain for approximately five days. There was no past history of elbow pain, trauma, throwing injury related to osteochondritis dissecans (OCD), or similar symptoms in other joints or medical illness. On physical examination, the pain was found to be localized to the lateral aspect of the right elbow. His elbow showed full range of motion. He had

no redness, swelling, or local heating around the right elbow. X-ray examination of the elbow showed shell like ossification of the capitellum with a subchondral lesion at the distal metaphysis of the right humerus (Fig. 1A, B). An arm sling was applied as a conservative treatment for two weeks under the impression of Panner's disease. Seventeen days later, magnetic resonance imaging examination was performed because of sustained pain of the right elbow lateral aspect (Fig. 1C-F). Two months later, he had no tenderness on the right elbow. Range of motion of both elbows showed a full extension. However, the right elbow showed slightly decreased flexion compared to the left elbow (right 140 degree, left 150 degree). Plain radiographs showed demineralization and resorption of the capitellum (Fig. 2A, B). Five months later, after the first visit, he showed no pain or tenderness on the right elbow and showed no limitation of both elbow motion. Plain radiographs showed more resorption of bony fragments at the capitellum of the right humerus (Fig. 2C, D). He did not visit the hospital because he had no discomfort of

Received November 2, 2015. **Revised** December 21, 2015. **Accepted** February 28, 2016.

[✉]**Correspondence to:** Jin Woong Yi

Department of Orthopedic Surgery, Konyang University College of Medicine, 158 Gwanjeodong-ro, Seo-gu, Daejeon 35365, Korea

Tel: +82-42-600-6902, **Fax:** +82-42-600-9793, **E-mail:** oeo-oeo@hanmail.net

IRB approval (No. KYUH 2016-08-017).

Financial support: None. **Conflict of interests:** None.

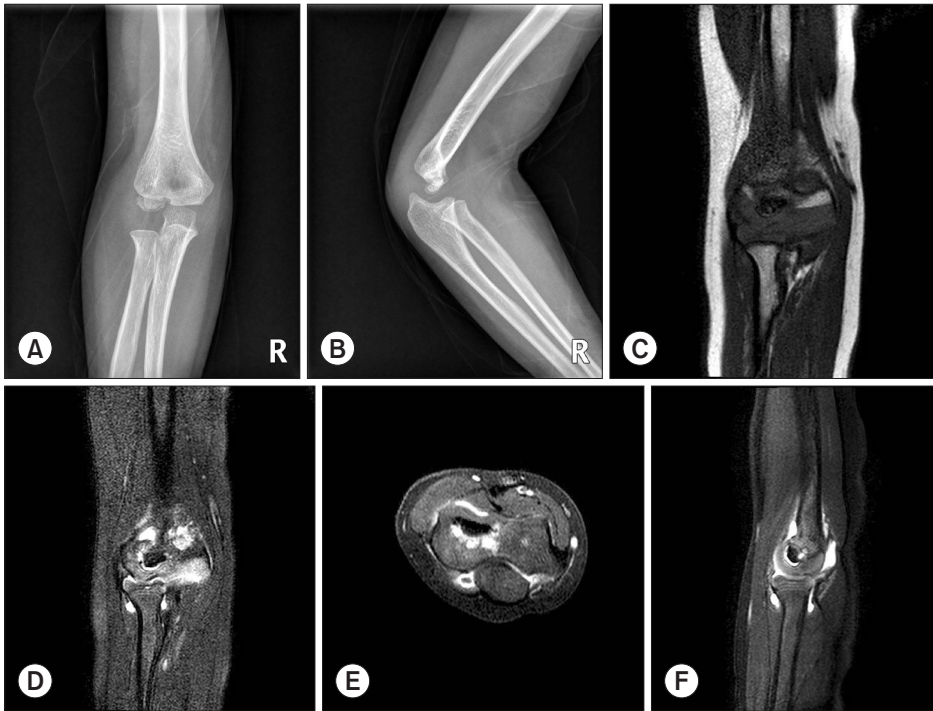

Fig. 1. Initial radiographic examination of the 5-year-old male patient. (A, B) Sclerosis within the capitellar ossification center is seen on this anteroposterior and lateral plain radiographs. (C, D) A T1-weighted and a T2-weighted fat suppressed coronal image show a dark signal throughout the capitellum. (E, F) A T1-weighted fat suppressed axial and a T2-weighted fat suppressed sagittal images show decreased signal throughout the capitellum. The overlying articular cartilage appears intact with smooth articular surface.

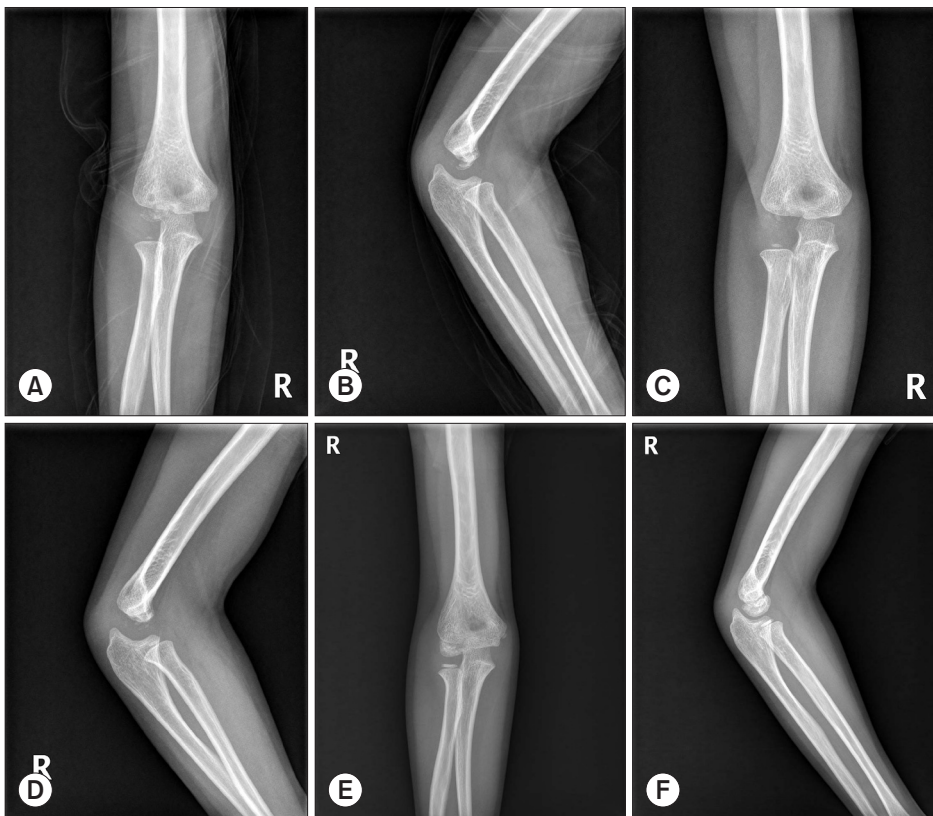


Fig. 2. (A, B) At 2 months, follow-up anteroposterior and lateral plain radiographs show demineralization and bone resorption of the capitellum. (C, D) At 5 months follow-up, plain radiographs show more progression of demineralization and bone resorption and disappearance of the capitellum. (E, F) At 31 months follow-up, plain radiographs show the healing process of Panner's disease of the right elbow. The re-ossification of the capitellum is shown. The volume of the re-ossified capitellum is relatively enlarged.

his elbow. After 26 months, he visited the hospital to check the radiographs of the elbow. He was asymptomatic with full range of motion of his elbow. His elbow was healed with reossification of the capitellum on plain radiographs (Fig. 2E, F).

Written informed consent was obtained from the patient for publishing this case report, including the images.

Discussion

Panner's disease, osteonecrosis of the capitellum of the elbow, was first reported by Panner in 1927.⁴⁾ Claessen et al.³⁾ reported an article reviewing 23 cases of Panner's disease. According to their findings, most cases of Panner's disease were unilateral in distribution and occurred in boys between 6 and 15 years of age and self-limiting disease healing without clinical impairments. It is doubtful that trauma could be a major cause of this disease. Thus, Panner's disease has sometimes been confused with OCD of humerus. In certain aspects, Panner's disease and OCD show a similar clinical course. For examples, 1) sex ratio, 2) location of the lesion, 3) dominant hand, 4) treatment and the resultant prognosis (early diagnosis facilitating full recovery) are similarities between the two diseases. We found some studies that reported the same entities.⁵⁾

However, Panner's disease is generally idiopathic, although some disturbances in the osteochondral growth process have known causes such as steroids, sickle cell disease. OCD of the capitellum could be considered in patients with a history of repetitive overuse of the elbow. Thus, most authors believe that the primary etiological factor of Panner's disease is an endocrine disturbance; however the exact nature of the disturbance is far from settled.

Radiographs of Panner's disease show demineralization of the capitellum and poorly defined cortical margins. Sclerosis, fissuring, and fragmentation of the capitellum are also frequently observed. Matsuura et al.⁶⁾ classified osteochondrosis of the humeral capitellum according to three stages. Stage I was characterized by translucency. Stage II was characterized by the presence of nondisplaced fragments. Loose bodies and sclerotic change indicated stage III. They concluded that osteochondrosis of the humeral capitellum could be successfully treated conservatively if treatment is begun at an early stage of the disease. In our case, initially, the patient experienced pain and stiffness with translucency and shell like ossification of the capitellum (stage I).

Ossification center of the capitellum appears radiographically at approximately 2 years of age. As mentioned above, if Panner's disease is due to a disturbance of the endocrine or circulation, the trochlea should be affected by any disturbance because the trochlea is derived from the same cartilaginous mass as the

capitellum. However, we found no studies reporting spontaneous avascular necrosis of trochlea. We think that the ossification time of the trochlea is slower than that of the capitellum, thus the trochlea is not affected by disturbance of the endocrine or circulation.

Osteochondrosis of the humeral capitellum could be successfully treated conservatively if treatment is begun at an early stage of the disease. Treatment results for Panner's disease could be better than those for Legg-Calve-Perthes Disease because the elbow is not the weight bearing part. When we thought about our case, clinical pain disappeared approximately two weeks later with elbow stabilization. And, reconstitution of the capitellum in the elbow took approximately 31 months. We could not know the exact time taken for recovery to nearly normal appearance in radiographs. However, we could explain to the patient and his guardian the approximate time to recovery to normal in radiographs.

Panner's disease is the most common cause of lateral sided elbow pain in children younger than 10 years. It is characterized by abnormal resorption, necrosis, and reossification of the capitellum. It may or may not be associated with athletic activity. To the best of our knowledge, most reported cases are under six years. We report the case of a five-year-old boy who was confirmed as Panner's disease, which was treated successfully with conservative treatment.

References

1. Stoane JM, Poplausky MR, Haller JO, Berdon WE. Panner's disease: X-ray, MR imaging findings and review of the literature. *Comput Med Imaging Graph.* 1995;19(6):473-6.
2. Smith MG. Osteochondritis of the humeral capitulum. *J Bone Joint Surg Br.* 1964;46:50-4.
3. Claessen FM, Louwerens JK, Doornberg JN, van Dijk CN, Eygendaal D, van den Bekerom MP. Panner's disease: literature review and treatment recommendations. *J Child Orthop.* 2015;9(1):9-17.
4. Heller CJ, Wiltse LL. Avascular necrosis of the capitellum humeri (Panner's disease). A report of a case. *J Bone Joint Surg Am.* 1960;42:513-6.
5. Wróblewski R, Urban M, Michalik D, Zakrzewski P, Langner M, Pomianowski S. Osteochondrosis of the capitellum of the humerus (Panner's disease, Osteochondritis Dissecans). Case study. *Ortop Traumatol Rehabil.* 2014;16(1):79-90.
6. Matsuura T, Kashiwaguchi S, Iwase T, Takeda Y, Yasui N. Conservative treatment for osteochondrosis of the humeral capitellum. *Am J Sports Med.* 2008;36(5):868-72.