

# Clinical and Structural Outcomes of Arthroscopic Intraarticular Knotless Fixation for Upper Subscapularis Tendon Tears: A Preliminary Report

Nam Su Cho<sup>✉</sup>, Hee Seok Shim, Ju Hyun Nam, Yong Girl Rhee

Shoulder & Elbow Clinic, Department of Orthopedic Surgery, College of Medicine, Kyung Hee University, Seoul, Korea

**Background:** A novel technique for the repair of tears of the upper subscapularis tendon—*intraarticular knotless fixation*—has been introduced recently. The purpose of this study was to evaluate the clinical and structural outcomes of arthroscopic *intraarticular knotless fixation* for the treatment of upper subscapularis tendon tears.

**Methods:** We retrospectively analyzed the clinical and radiological outcomes of 27 patients who underwent arthroscopic *intraarticular knotless fixation* for upper subscapularis tendon tears. Finally, a total of 10 patients who could participate in at least a 6 month follow-up of magnetic resonance imaging evaluation and in a least 1-year follow-up on an outpatient basis were enrolled in our study. The mean age at the time of operation was 60.7 years, and the mean duration of follow-up was 14.7 months. Two patients had concomitant tears of the supraspinatus tendon and 8 patients had concomitant tears of the supraspinatus and the infraspinatus tendons.

**Results:** The clinical and radiological outcomes improved after the patients had undertaken arthroscopic *intraarticular knotless fixation*. The mean visual analogue scale score for pain during motion improved from 6.7 preoperatively to 1.4 at the final follow-up ( $p < 0.001$ ). The mean Constant score improved from 59.3 preoperatively to 79.6 at the final follow-up, and the mean the University of California at Los Angeles score, from 21.7 to 30.2, respectively ( $p < 0.001$  and  $p < 0.001$ ). The upper subscapularis tendon tear was healed in every patient except one (90%), for the patient had suffered from a postoperative trauma that resulted in a retear.

**Conclusions:** We found that arthroscopic *intraarticular knotless fixation* gives good clinical and structural outcomes for the repair of upper subscapularis tendon tears. Arthroscopic *intraarticular knotless fixation* provided such a reliable and efficient restoration of the subscapularis tendon footprint that we anticipate it will become a widely-used procedure for upper subscapularis tendon tears.

(Clin Shoulder Elbow 2016;19(3):130-136)

**Key Words:** Shoulder; Subscapularis; Arthroscopy; Intraarticular knotless fixation; Treatment outcome

## Introduction

Although subscapularis tendon tears in the past were believed to be rare, it is now a commonly lesion of the subscapularis.<sup>1-4)</sup> This is attributable to advances in shoulder arthroscopy that has enabled tears of the the articular side of the rotator cuff which were previously gone undetected to be diagnosed. The detection is so common that they are detected during nearly 30% of

all arthroscopic shoulder procedures and during approximately 50% of arthroscopic rotator cuff repairs.<sup>1,2,5,6)</sup> This necessitates surgeons to familiarize themselves with techniques relating to the accurate diagnosis and to the effective treatment of subscapularis tears.

Arthroscopic repairs of the subscapularis tendon tears can be technically challenging. Aspects that are unique to the subscapularis make arthroscopic repairs particularly difficult: a small ante-

**Received** September 27, 2015. **Revised** December 3, 2015. **Accepted** December 24, 2015.

<sup>✉</sup>**Correspondence to:** Nam Su Cho

Department of Orthopedic Surgery, Kyung Hee University Hospital at Gangdong, 892 Dongnam-ro, Gangdong-gu, Seoul 05278, Korea

**Tel:** +82-2-440-6154, **Fax:** +82-2-440-7498, **E-mail:** nscos1212@empas.com

IRB approval (No. KHNMC IRB 2016-08-018).

**Financial support:** This research was supported by the Sports Scientification of Convergent R&D Program run by the National Research Foundation of Korea (NRF) and funded through the Ministry of Science, ICT & Future Planning (NRF-2014M3C1B1033319).

**Conflict of interests:** None.

rior space overlying the subscapularis, difficulties in ascertaining a sufficient visualization window, and difficulties in instrument manipulation and in tying a knot within a tightly constricted subcoracoid space. Since its first description by Burkhart and Tehrani<sup>7</sup> in 2002, several authors have reported attempts of an arthroscopic repair of subscapularis tendon tears.<sup>2,8-12</sup> Most early techniques for this repair have required arthroscopic knot tying.<sup>2,7-10,13</sup>

Recently, Denard and Burkhart<sup>11</sup> have introduced a new knotless fixation technique for subscapularis repair that is effective for the treatment of the upper-third subscapularis tendon tears. The clinical significance is most apparent in the fact that most tears of the subscapularis are partial- or full-thickness tears that occur in the upper third of the tendon.<sup>14</sup> Therefore, arthroscopic intraarticular knotless fixation is anticipated to be an effective treatment that is applicable to most subscapularis tendon tears. However, to our knowledge, no study has yet reported the clinical outcomes of arthroscopic intraarticular knotless fixation for upper subscapularis tendon tears.

The purpose of the present study was to fill this gap in our knowledge by evaluating the clinical and structural outcomes of arthroscopic intraarticular knotless fixation for upper subscapularis tendon tears. We hypothesized that this mode of treatment for upper subscapularis tendon tears would be effective, in terms of clinical outcome and retear rate, at a level comparable to that of arthroscopic knot tying reported in the literature.

## Methods

### Patient Selection

We retrospectively analyzed the clinical and radiological outcomes of 27 patients who underwent an arthroscopic in-

traarticular knotless fixation for upper subscapularis tendon tears between May 2013 and May 2014. The upper subscapularis tendon tears presented by the patients were either type IIB tears or of lower severity according to the classification system described by Yoo et al.<sup>6</sup> The inclusion criteria had those who could participate in at least a 6-month follow-up magnetic resonance imaging (MRI) evaluation and in a least a year of follow-up performed on an outpatient basis. The following exclusion criteria was applied: patients with a larger than type IIB tear or a more retracted subscapularis tear, acromioclavicular arthritis that required distal clavicle resection, advanced glenohumeral arthritis, rotator cuff tears that involved workers' compensation claim, and undergoing revision procedures. After these criteria were fulfilled, the patients eligible for our study numbered 10 out of a possible 27. The study population comprised of 4 men and 6 women. The mean age of the patients at the time of operation was 60.7 years (range, 49–73 years), and the mean duration of follow-up was 14.7 months (range, 12–18 months). The upper subscapularis tendon tear involved the right shoulder in 8 patients and the left in 2. The tear involved the dominant side in 8 patients and the non-dominant side in 2. Every patient was found to have a concomitant rotator cuff tear other than the subscapularis tendon: 2 patients had tears of the supraspinatus tendon and 8 patients had tears of the supraspinatus and infraspinatus tendons. Patient demographic details are summarized in Table 1.

### Preoperative and Postoperative Evaluations

All preoperative evaluations were performed a day before operation, and postoperative evaluations were performed regularly on an outpatient basis. The patients were evaluated for several physical examinations. We assessed the subjective pain score us-

Table 1. Patient Demographics

Case No.	Sex	Age (yr)	SSC tear type*	Associated cuff tear	Associated biceps lesion	Repair technique for the associated cuff tear	Surgery for the associated biceps lesion	Acromioplasty	Retear in SST/IST	Retear in SSC
1	M	56	IIB	SST+IST	Partial rupture (75%)	SB	Intra-cuff tenodesis	+	+	-
2	F	49	IIA	SST+IST	-	SB	-	-	-	-
3	M	62	IIB	SST+IST	-	SB	-	+	-	-
4	F	63	IIA	SST	-	SB	-	-	-	-
5	F	65	IIB	SST+IST	Nearly complete rupture	SB	Tenotomy	+	-	-
6	F	61	IIA	SST	Partial rupture (75%)	SB	Tenotomy	-	-	-
7	F	67	IIB	SST+IST	Complete rupture	SB	-	+	-	-
8	F	73	IIB	SST+IST	Partial rupture (75%)	SB	Tenotomy	-	-	-
9	M	50	IIB	SST+IST	Partial rupture (50%)	SB	Supraperacrotal tenodesis	+	+	+
10	M	61	IIB	SST+IST	Partial rupture (50%)	SB	Supraperacrotal tenodesis	-	-	-

SSC: subscapularis, SST: supraspinatus, IST: infraspinatus, M: male, F: female, SB: suture-bridge.

\*According to Yoo and Rhee's classification of subscapularis tendon tears.<sup>6</sup>

ing the visual analogue scale (VAS). We measured the following shoulder range of motions (ROM): forward flexion, external rotation at the side, internal rotation to the back, and abduction. We carried out the belly press test and the lift-off test. From the pre- and postoperative values derived from these examinations, we made a comparative analysis between the preoperative and the last follow-up results. The Constant score,<sup>15</sup> the Shoulder Rating Scale of the University of California at Los Angeles (UCLA),<sup>16</sup> and the patient satisfaction score were used for the clinical assessment of the patients.

### Operative Techniques

All operations were performed by the single surgeon with the patient in a beach chair position with the back of the bed flexed about 70°. We used the standard arthroscopic portals: the posterior viewing portal and the anteroinferior and the anterosuperior working portals. First, we inspected the subscapularis tendon for tears; since most tears begin at the upper articular surface, a bare footprint within the lesser tuberosity is indicative of a subscapularis tear. The patient's arm was placed in abduction and in internal rotation when viewing the subscapularis insertion. The biceps was also examined thoroughly because a tear of the upper subscapularis is usually accompanied by a disruption of

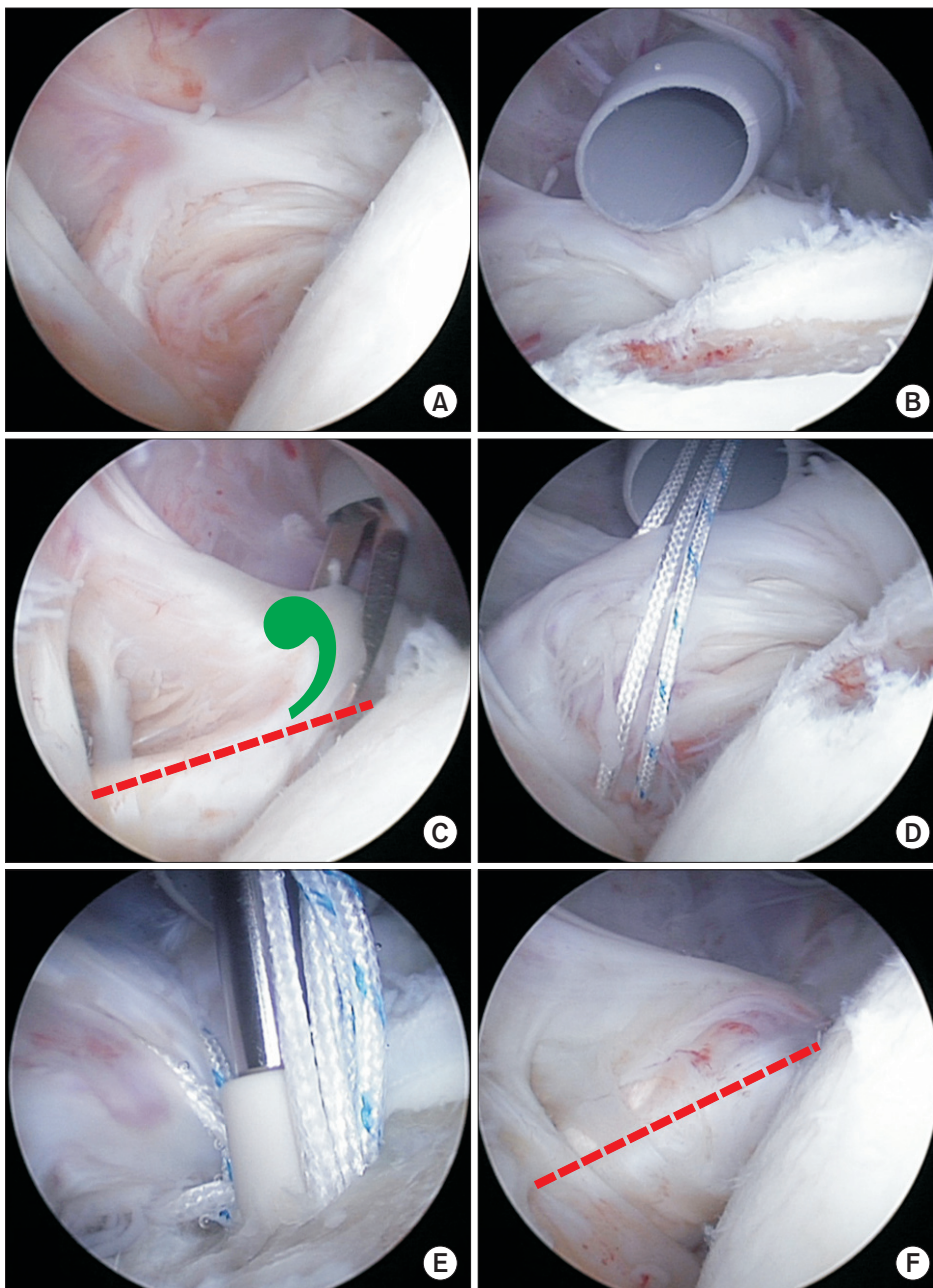


Fig. 1. Arthroscopic intraarticular knotless fixation for an upper subscapularis tendon tear in the right shoulder, viewed from the posterior portal. (A) A partial articular-sided tear of the upper subscapularis tendon. (B) An exposed upper subscapularis footprint. (C) The comma sign is visible at the superolateral border of the retracted subscapularis tendon. (D) High strength sutures were passed in the antegrade direction across the upper subscapularis with a straight suture hook. (E) A tensioning suture was made with the Bio-PushLock. (F) Repair of upper subscapularis tear was completed and a restored anatomic footprint can be seen without any arthroscopic knots.

the adjacent insertion of the medial sling, which causes medial subluxation of the biceps. If indicated, a tenodesis or tenotomy was performed in conjunction with the repair of the subscapularis tear. Then, we identified the coracoid tip, which can be palpated anterior to the upper border of the subscapularis tendon. And because all important neurovascular structures are found around 2.5 cm away from this particular structural landmark, we kept this landmark in mind throughout the arthroscopic procedure to prevent accidental damage in any of the nerves. We used a combination of electrocautery, a shaver, and a burr to prepare the lesser tuberosity bone bed into a bleeding base. From the anteroinferior portal, a #2 Hi-Fi high strength suture (ConMed Linvatec, Largo, FL, USA) was passed in the antero-grade direction through the upper subscapularis with a straight suture hook. The Hi-Fi suture end was retrieved out through the anterosuperior portal. Another Hi-Fi suture was fed through the upper subscapularis and retrieved out the anterosuperior portal. A suture retriever device was used to bring the ends of two Hi-Fi sutures out through the anteroinferior portal. A punch was placed through the anteroinferior portal to prepare the bone for anchor insertion. All the Hi-Fi sutures were retrieved and threaded through the Bio-PushLock (Arthrex, Naples, FL, USA) eyelet on the distal end of the driver. The distal tip of the Bio-PushLock was brought to the edge of the pilot hole in order to reduce the tendon to its desired position on the footprint all the while holding onto the suture tails. The driver was then advanced into the pilot hole until the anchor body made contact with the bone. The anchor body was tapped into the pilot hole while exerting adequate tension on the tissue by pulling on the suture strands individually. Finally, the sutures were cut flush (Fig. 1). The arm was immobilized in a sling after performing a routine closure of the portals.

### Postoperative Rehabilitation

All patients followed a standard postoperative rehabilitation program. Postoperatively, the patient's arm was immobilized in a sling for 6 weeks. No overhead motion was allowed during this period, while elbow flexion, wrist exercises, and hand exercises were encouraged. The patients were permitted to perform passive forward flexion up to 90° from the 3rd postoperative week. But passive external rotation was not permitted until the 6th postoperative week, and active movements in all directions was not permitted until the 3rd postoperative month. Muscle strengthening exercises were introduced thereafter gradually. A return to recreational activity that demands heavy strain on the shoulder or to manual labor was made by 6 months of rehabilitation.

### Assessment of Tendon Healing

A postoperative MRI scan was performed at a mean of 7.4 months (range, 6–11 months) after surgery. All scans were ob-

tained with a 1.5-T unit (Signa; GE Medical Systems, Chicago, IL, USA) by use of routine pulse sequences. The radiographic images were reviewed by an experienced senior radiologist who was informed that the patients had undergone a cuff repair but was blinded to the size and to the location of the tear. Continuity and re-rupture of the tendon were assessed on MRI scans in accordance to established MRI criteria.<sup>17</sup> When we found a fluid equivalent signal or could not visualize the subscapularis tendon on at least one T2-weighted or proton density-weighted image, a full-thickness retear (i.e., anatomically failed healing) was diagnosed.

### Statistical Analysis

We assessed the statistical significance of the differences in the preoperative and the postoperative results using the Wilcoxon signed rank test. The comparative analysis of the preoperative and postoperative proportions of patients with positive signs for the physical test that evaluates subscapularis strength was made with the Pearson chi-square test. Statistical significance was set to an  $\alpha$  level of 0.05 with its associated 95% confidence interval. The PASW software package ver. 18.0 (IBM Co., Armonk, NY, USA) was used for all statistical analyses.

## Results

We found that the mean VAS for pain both during motion and during rest decreased after patients underwent intraarticular knotless fixation. The mean VAS during rest improved from 1.8 (range, 1–6) preoperatively to 0.2 (range, 0–2) at the last follow-up ( $p < 0.001$ ). The mean VAS during motion also improved from 6.7 (range, 5–9) to 1.4 (range, 0–3), respectively ( $p < 0.001$ ). We also found that the following mean active ROMs improved after patients underwent intraarticular knotless fixation: forward flexion improved from 164° (range, 140°–180°) preoperatively to 173° (range, 160°–180°) at the last follow-up; external rotation at the side, from 60° (range, 40°–80°) to 63° (range, 45°–80°); internal rotation to the posterior, from L3 (range, T10–S1) to L1 (range, T10–L4); and abduction, from 153° (range, 135°–180°) to 167° (range, 150°–180°) ( $p = 0.038, 0.531, 0.154,$  and  $< 0.001$ , respectively). To evaluate the impact of intraarticular knotless fixation on subscapularis function, we measured the subscapularis strength of the patients preoperatively and postoperatively using the belly-press test and the lift-off test. We found that the proportion of patients with a positive outcome for the belly-press test, which is indicative of poor subscapularis strength, decreased from 60% preoperatively to 0% at the last follow-up ( $p < 0.001$ ). Likewise the proportion of patients with a positive outcome for the lift-off test decreased from 40% preoperatively to 0% at the last follow-up ( $p < 0.001$ ).

To assess the impact of intraarticular knotless fixation on clinical factors, we assessed the change in clinical variables before

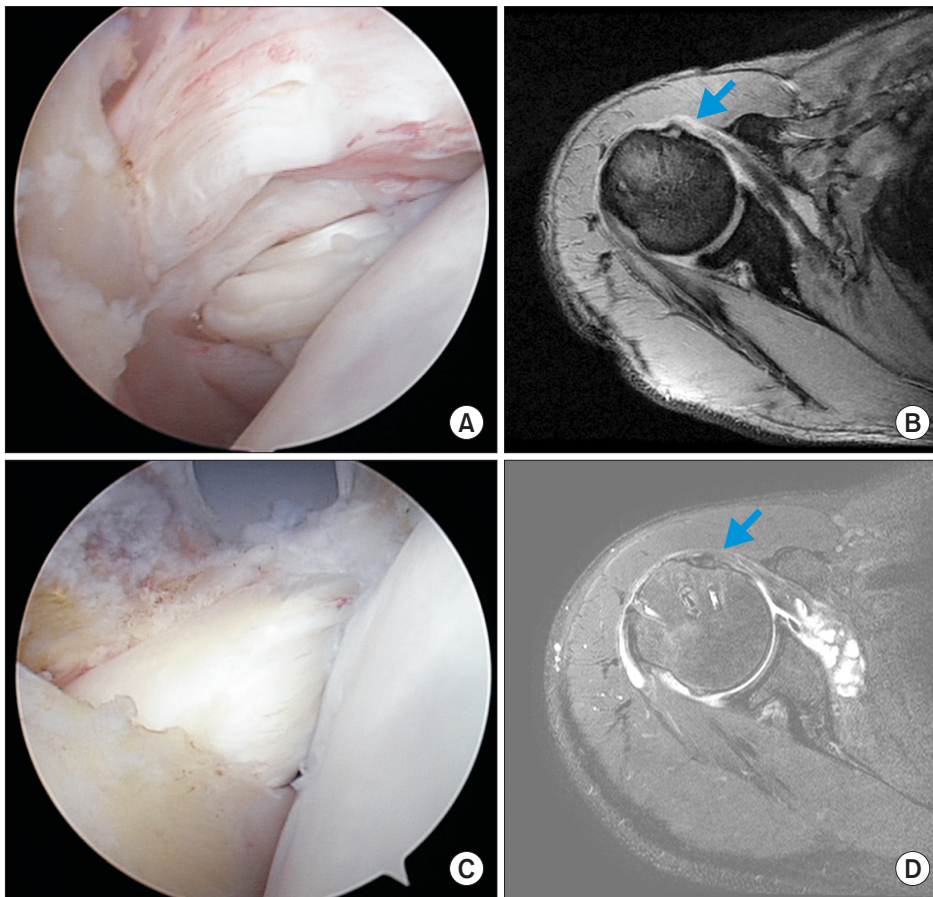


Fig. 2. Arthroscopic images from a 62-year-old male patient. (A) A partial articular-sided tear of the upper subscapularis tendon can be seen. (B) Preoperative magnetic resonance imaging shows a subscapularis tendon tear (arrow). (C) An anatomically restored upper subscapularis tendon tear. (D) Postoperative magnetic resonance imaging shows a normal tendon (arrow).

and after the operation using the Constant score and the UCLA score. At the last follow-up we asked patients to take a subjective satisfaction survey and using that assessed the patient's self-surveyed satisfaction score. We found that the mean Constant score improved from 59.3 points preoperatively (range, 38–75 points) to 79.6 points (range, 54–89 points) at the last follow-up ( $p < 0.001$ ), the UCLA score improved from 21.7 points (range, 14–29 points) to 30.2 points (range, 24–35 points), respectively ( $p < 0.001$ ). The patient satisfaction score was 92 points (range, 85–100 points) at the last follow-up.

We assessed the structural outcomes after the knotless repair of the upper subscapular tendon tears using radiographic findings. We found through the postoperative MRI scans, 9 or 10 subscapularis tendon tears (90%) was completely repaired (Fig. 2), only one patient who suffered from postoperative trauma presented with a partial retear (Table 1). With regards to the repair of the tears that had occurred concomitantly with the upper subscapular tendon tear, 2 of the combined tears (20%) showed retears, both of which were tears that encompassed both the supraspinatus tendon and the infraspinatus tendon and that were combined with a partial rupture of the biceps. A detailed comparison of the preoperative and postoperative variables can be seen in Table 2.

Table 2. Clinical Outcomes of Arthroscopic Intraarticular Knotless Fixation

Variable	Preoperative	Postoperative	<i>p</i> -value*
VAS (at rest)	1.8 ± 2.0	0.2 ± 0.7	<0.001
VAS (during motion)	6.7 ± 2.1	1.4 ± 1.5	<0.001
Range of motion			
FF (°)	164 ± 25	173 ± 19	0.038
ERs (°)	60 ± 23	63 ± 21	0.531
IRp (level)	L3 (T10–S1)	L1 (T10–L4)	0.154
Abd (°)	153 ± 23	167 ± 14	<0.001
Constant score	59.3 ± 10.2	79.6 ± 8.0	<0.001
UCLA score	21.7 ± 2.1	30.2 ± 2.9	<0.001

Values are presented as mean ± standard deviation or level (range).

VAS: visual analogue scale, FF: forward flexion, ERs: external rotation at the side, IRp: internal rotation to the posterior, Abd: abduction, UCLA: the University of California at Los Angeles.

\*Statistically significant ( $p < 0.05$ ).

## Discussion

The purpose of this study was to evaluate the short-term clinical and functional outcomes of knotless repairs for upper

subscapularis tendon tears. We hypothesized that the outcomes of arthroscopic intraarticular knotless fixation for an upper subscapularis tears, specifically clinical outcome and retear rate that are reported in the literature, will be equivalent to those of arthroscopic knot tying repair. We found this hypothesis to be supported by our findings.

Given the importance of the subscapularis tendon in shoulder function, which has been exemplified in several studies,<sup>10,18-20</sup> the need to properly recognize and treat subscapularis tendon tears cannot be underscored. The subscapularis, being the largest and most powerful of the rotator cuff muscles, alone provides approximately 50% of the rotator cuff force,<sup>21</sup> and is important for arm elevation.<sup>20</sup> Intriguingly, the subscapularis muscle has been shown to be more active in patients with asymptomatic cuff tears implying that the subscapularis tendon may play a compensatory role during posterosuperior cuff tears.<sup>19</sup> When a reparable subscapularis tendon tear is left unrepaired, anterior cable detachment places additional strain and stress on the subscapularis that predisposes it permanent, irreversible damage of the posterosuperior rotator cuff tendon.<sup>18</sup>

The effectiveness of arthroscopic technique in treating isolated subscapularis tears has been already documented in previous studies. In 2002, Burkhart and Tehrani<sup>7</sup> first reported promising short-term outcomes of arthroscopic subscapularis repair in 25 patients. A subsequent report of 45 patients with a median 5-year follow-up showed that they retained favorable results till the intermediate-term.<sup>9</sup> Overall, 80% of patients had a good or excellent result and 83% of patients returned to work or sports. Encouraging arthroscopic results have also been reported by several other authors.<sup>2,8</sup> Recently, Bartl et al.<sup>13</sup> similarly reported substantial improvement of shoulder function and a low retear rate of 4.8% (1 patient) in 21 isolated tears repaired arthroscopically.

Despite the fact several studies have reported good clinical results of arthroscopic repairs of subscapularis tears, repairs of the subscapularis present with unique challenges that are absent with repairs of the superior rotator cuff tears. One of the primary difficulties in treating subscapularis tears arthroscopically is the tight subcoracoid space overlying the tendon. Previous techniques have used a single double-loaded anchor, a suture that is passed in a simple pattern, and arthroscopic knotting to repair upper subscapularis tendon tears.<sup>10</sup> The novelty of the current technique, arthroscopic intraarticular knotless fixation, is that it eliminates and simplifies several steps in the repair alleviating some of the previous difficulties with working in a tight subcoracoid space. Because the majority of tears of the subscapularis are partial-thickness, articular-sided tears of the upper tendon (footprint or full-thickness tears of less than 50% of the length of the footprint),<sup>14</sup> the technique is applicable in many instances. To our knowledge, our study is the first to report the clinical and structural outcomes of arthroscopic intraarticular knotless fixa-

tion for upper subscapularis tendon tears.

We found that arthroscopic intraarticular knotless repair for the upper subscapularis tendon tears in the majority of cases led to good or excellent clinical and functional results. An anatomic restoration of the tear was achieved in all but one case, in which a minor postoperative trauma induced a retear. We believe that the knotless technique is more effective than previous techniques without compromising the quality of repair. Regarding these previous techniques, Bartl et al.<sup>13</sup> had reported that in 25% of the patients despite receiving treatment and despite excellent clinical and structural results the postoperative subscapularis strength remained at a sub-contralateral level and atrophy of the upper subscapularis muscle was present. Yet in our study, we found that the postoperative subscapularis strength, though not quantitatively measured but measured through physical examinations such as the belly press test and the lift-off test, were negative indicating improvement. This may be attributable to good anatomic results after using the intraarticular knotless technique or to the fact that only study subjects with upper subscapularis tendon tears were enrolled in our study. It means that the possibility of severe muscle insufficiency was never a serious issue among our sample of patients.

Our study has few limitations. First, although our data were collected through a prospective approach, our findings are based on a retrospective analysis of data. Second, because only patients who partook in at least a 6 month follow-up of MRI examination and in more than a year follow-up on an outpatient basis were included in our study, there is potential for selection bias in our method of patient recruitment. Although some may argue that the cuff tears that were associated with subscapularis tears may likely be an influencing factor of the variable under investigation, one can argue that even if it has an effect, which was undefined in this study, this would not detract from the clinical relevance of the study since most subscapularis tears do not occur in isolation anyway. Finally, a substantial weakness in our study was the small patient sample and a lack of a control group. Subsequent studies are required with longer follow-ups and a greater sample population to increase the statistical power of this study. Despite these limitations, we believe our study deserves to receive spotlight for providing the much needed information on the clinical outcomes of arthroscopic intraarticular knotless fixation for upper subscapularis tears and for demonstrating the effectiveness of this technique.

## Conclusion

In conclusion, we found that favorable clinical and structural outcomes can be anticipated with arthroscopic intraarticular knotless fixation of upper subscapularis tendon tears. Since this treatment returned a consistently reliable and effective restoration of the subscapularis tendon footprint, we believe that

arthroscopic intraarticular knotless fixation may in the future become an acceptable procedure for tears of the upper subscapularis tendon.

## References

1. Arai R, Sugaya H, Mochizuki T, Nimura A, Moriishi J, Akita K. Subscapularis tendon tear: an anatomic and clinical investigation. *Arthroscopy*. 2008;24(9):997-1004.
2. Lafosse L, Jost B, Reiland Y, Audebert S, Toussaint B, Gobezie R. Structural integrity and clinical outcomes after arthroscopic repair of isolated subscapularis tears. *J Bone Joint Surg Am*. 2007;89(6):1184-93.
3. Ticker JB. Subscapularis and biceps tendon pathology encountered during arthroscopic posterosuperior rotator cuff repair. Paper presented at: Arthroscopy Association of North America 26th Annual Meeting; 2007 Apr 26-29; San Francisco (CA).
4. Walch G, Nové-Josserand L, Boileau P, Levigne C. Subluxations and dislocations of the tendon of the long head of the biceps. *J Shoulder Elbow Surg*. 1998;7(2):100-8.
5. Barth JR, Burkhart SS, De Beer JF. The bear-hug test: a new and sensitive test for diagnosing a subscapularis tear. *Arthroscopy*. 2006;22(10):1076-84.
6. Yoo JC, Rhee YG, Shin SJ, et al. Subscapularis tendon tear classification based on 3-dimensional anatomic footprint: a cadaveric and prospective clinical observational study. *Arthroscopy*. 2015;31(1):19-28.
7. Burkhart SS, Tehrany AM. Arthroscopic subscapularis tendon repair: Technique and preliminary results. *Arthroscopy*. 2002;18(5):454-63.
8. Bennett WF. Arthroscopic repair of isolated subscapularis tears: A prospective cohort with 2- to 4-year follow-up. *Arthroscopy*. 2003;19(2):131-43.
9. Adams CR, Schoolfield JD, Burkhart SS. The results of arthroscopic subscapularis tendon repairs. *Arthroscopy*. 2008;24(12):1381-9.
10. Burkhart SS, Brady PC. Arthroscopic subscapularis repair: surgical tips and pearls A to Z. *Arthroscopy*. 2006;22(9):1014-27.
11. Denard PJ, Burkhart SS. A new method for knotless fixation of an upper subscapularis tear. *Arthroscopy*. 2011;27(6):861-6.
12. Gilmer BB, Crall TS, Guttmann D. Knotless arthroscopic repair of subscapularis tendon tears using looped suture. *Arthrosc Tech*. 2015;4(3):e267-71.
13. Bartl C, Salzmänn GM, Seppel G, et al. Subscapularis function and structural integrity after arthroscopic repair of isolated subscapularis tears. *Am J Sports Med*. 2011;39(6):1255-62.
14. Sakurai G, Ozaki J, Tomita Y, Kondo T, Tamai S. Incomplete tears of the subscapularis tendon associated with tears of the supraspinatus tendon: cadaveric and clinical studies. *J Shoulder Elbow Surg*. 1998;7(5):510-5.
15. Constant CR, Murley AH. A clinical method of functional assessment of the shoulder. *Clin Orthop Relat Res*. 1987;(214):160-4.
16. Ellman H, Hanker G, Bayer M. Repair of the rotator cuff. End-result study of factors influencing reconstruction. *J Bone Joint Surg Am*. 1986;68(8):1136-44.
17. Gusmer PB, Potter HC, Donovan WD, O'Brien SJ. MR imaging of the shoulder after rotator cuff repair. *AJR Am J Roentgenol*. 1997;168(2):559-63.
18. Ticker JB, Burkhart SS. Why repair the subscapularis? A logical rationale. *Arthroscopy*. 2011;27(8):1123-8.
19. Kelly BT, Williams RJ, Cordasco FA, et al. Differential patterns of muscle activation in patients with symptomatic and asymptomatic rotator cuff tears. *J Shoulder Elbow Surg*. 2005;14(2):165-71.
20. Kuechle DK, Newman SR, Itoi E, Morrey BF, An KN. Shoulder muscle moment arms during horizontal flexion and elevation. *J Shoulder Elbow Surg*. 1997;6(5):429-39.
21. Keating JF, Waterworth P, Shaw-Dunn J, Crossan J. The relative strengths of the rotator cuff muscles. A cadaver study. *J Bone Joint Surg Br*. 1993;75(1):137-40.