

Laparoscopic Splenectomy in Two Dogs Using Sonicision™

Tae-Yeong Park*, Hyun-Jin Kim*, Jung-Hoon Kim*, Jun-Min Kim*, Seong-Hoon Seok*,
Dong-In Jung***, Il-Hwa Hong****, Hee-Chun Lee** and Seong-Chan Yeon*¹

*Laboratory of Veterinary Surgery & Behavior, College of Veterinary Medicine,
Gyeongsang National University, Jinju 52828, Republic of Korea

**Laboratory of Veterinary Medical Imaging, College of Veterinary Medicine,
Gyeongsang National University, Jinju 52828, Republic of Korea

***Laboratory of Veterinary Internal Medicine, College of Veterinary Medicine,
Gyeongsang National University, Jinju 52828, Republic of Korea

****Laboratory of Veterinary Pathology, College of Veterinary Medicine,
Gyeongsang National University, Jinju 52828, Republic of Korea

(Received: June 02, 2016 / Accepted: August 16, 2016)

Abstract : A 10-year-old, 24.1 kg, intact female Siberian husky dog (case 1) and 11-year-old, 5.0 kg, intact male Shih-tzu dog (case 2) presented with chief complaints of polydipsia, anorexia, vomiting and exercise intolerance (case 1) and stranguria (case 2). Splenic nodule (case 1) and mass (case 2) were identified in these patients through ultrasonographic examination. Laparoscopic splenectomy was conducted for the histopathologic evaluation. In addition, laparoscopic ovariohysterectomy, liver biopsy (case 1) and castration (case 2) were performed for treatment or diagnosis of primary symptoms. Under general anesthesia, 5 mm three-portal access laparoscopic splenectomy was performed using the Sonicision™ equipment. The dogs were rotated onto right lateral recumbency. The spleen was elevated using a fan or goldfinger retractor, which revealed the ventral aspect of the spleen. Resection of vessels was started at the caudal aspect of the spleen using the Sonicision™. The excised spleen was removed from the abdominal cavity using a 12 mm endo-bag via the enlarged instrument portal. There were no post-operative complications in either patient. Histopathologic diagnoses were splenic lymphoid hyperplasia (case 1) and splenic nodular hyperplasia (case 2). Based on our experience, laparoscopic splenectomy is sufficient to replace traditional splenectomy in small animal surgery. The use of the Sonicision™ could be a novel surgical technique for three-portal laparoscopic splenectomy, regardless of patient size.

Key words : dog, laparoscopic splenectomy, Sonicision™.

Introduction

Complete splenectomy is performed for canine patients with suspected malignant neoplasia, as well as for treatment of splenic torsion, rupture or generalized splenic enlargement from infiltrative diseases (12). Laparoscopic splenectomy, which is the gold standard for treatment of hematologic disorders of the spleen in humans (4), has clear advantages compared with laparotomy including lower morbidity rates, faster recovery, reduced surgical trauma and postoperative pain and shorter hospitalization (1,6,10).

Hemostasis can be achieved in various ways, such as the use of clips, sutures, monopolar, bipolar, and ultrasound coagulation, LigaSure™, SonoSurge and Sonicision™ (7,8). LigaSure seals the vessel by applying precise pressure and bipolar energy to the tissue. The vessel walls are fused into a single structure, which removes the lumen (7). This allows for easier access to the splenic hilum and reduces the risk of hemorrhage compared to other techniques. Sonicision™ provides better cuts with its ultrasonic blade, while the Sono-

Surge gives more precise coagulation by heating slowly. Emissivity varies for different instruments and produces varying results. Some instruments may be more suitable than others depending on the operation (8).

Laparoscopic surgery techniques developed for dogs; however, laparoscopic splenectomy as described in humans and goats has not yet been reported in dogs (1,3,4,14). Here, we report our experience with laparoscopic splenectomy using the Sonicision™ system in two dogs with splenic nodule and mass.

Case

Case 1

A 10-year-old, 24.1 kg, intact female Siberian husky was admitted with a chief complaint of polydipsia, anorexia, vomiting and exercise intolerance. A 3 cm nodule was found in the mid body of the spleen during abdominal ultrasonography. There were no specific diagnostic results that would indicate splenic nodules upon 3-view thoracic radiograph, complete blood cell count (CBC) and biochemistry.

The dog was premedicated with 0.02 mg/kg acepromazine (Sedaject, Samu Median, Korea) and 0.2 mg/kg butorphanol

¹Corresponding author.
E-mail : scyeon@gnu.ac.kr

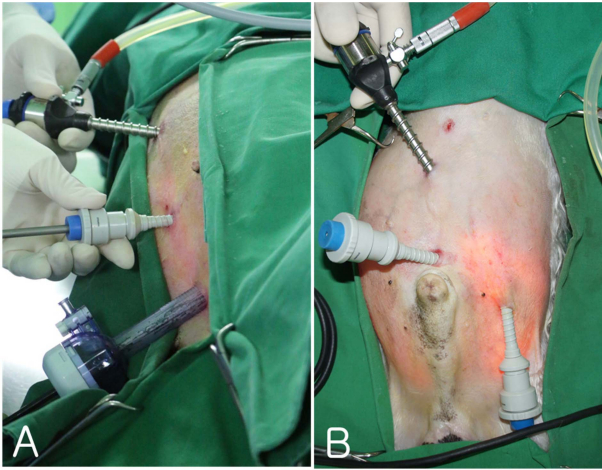


Fig 1. Location of trocar-cannular in dogs. The camera port was in Portal 1 and Portal 2 was positioned on the mid line, 2 cm caudal to portal 1. After rotating the patient to her right side, portal 3 was inserted 5 cm caudal to portal 2 (A). Portal 2 was placed on the mid line, 1 cm cranial to the prepuce. Portal 3 was inserted 5 cm lateral and caudal to portal 2 while the dog was rotated onto his right (B).

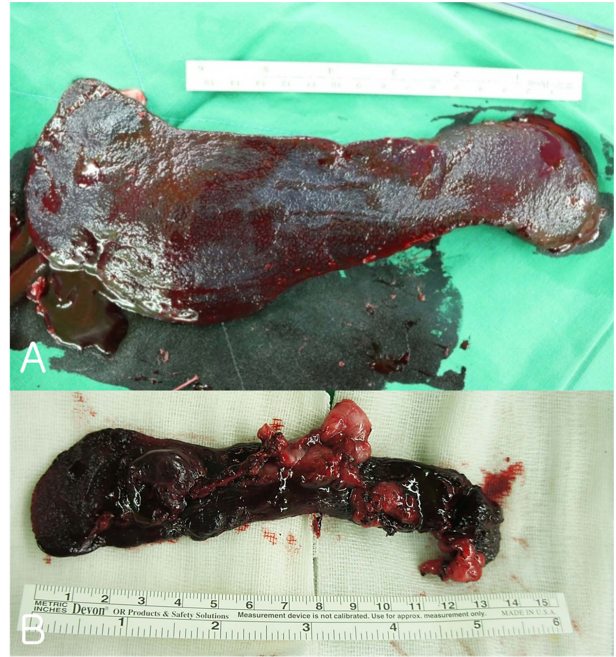

Fig 3. Detached spleens were removed from the abdominal cavity. Slight hemorrhage, nodule (A) and mass (B) in the spleen.

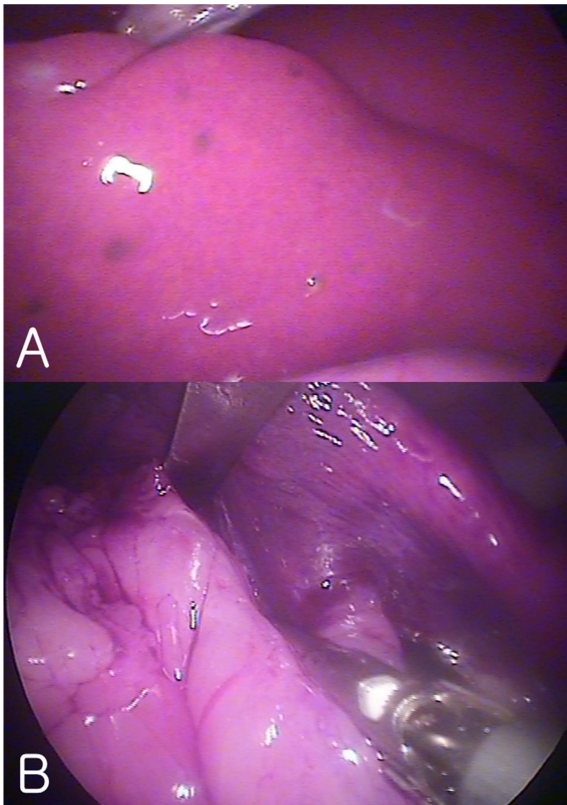


Fig 2. Laparoscopic image of the caudal part of the spleen. Splenic nodule (A) and mass (B) in the spleen.

(Butophan, Myungmoon Pharm, Korea). Preoperatively, 25 mg/kg cefazolin (Cefazolin, Chongkundang Pharm, Korea) and 0.2 mg/kg meloxicam (Metacam, Boeringer Ingelheim, USA) were administered intravenously. General anesthesia was induced with 3 mg/kg propofol (Provive, Myungmoon Pharm, Korea) and maintained with isoflurane (Ifran, Hana

Pharm, Korea) in 100% oxygen through an endotracheal tube in a circle rebreathing system. Lactated Ringer's solution was administered intravenously during the entire procedure at a rate of 10 mL/kg/h.

The dog was located in dorsal recumbency on a regular surgical table. To identify the linea alba, a 5 mm stab incision was made in the skin and subcutis through the umbilicus. A Verres needle was inserted through the abdominal wall and pulling the forces upward to prevent damage to the viscera. CO₂ pneumoperitoneum was then established with an insufflator (Richard Wolf, Knittlingen, Germany) to 10-12 mmHg with the Verres needles in the correct position. The Verres needle was swapped with a 5 mm trocar and a 30° forward-oblique, 5 mm laparoscope (Panoview Plus, Richard Wolf GmbH, Germany) was inserted. Under laparoscopic observation, two accessory portals (5 mm, Richard Wolf) were created. The camera port was portal 1 and portal 2 was positioned on the mid line, 2 cm caudal to portal 1. After rotating the patient to her right side, portal 3 was inserted 5 cm caudal to portal 2 (Fig 1A). Sonicision™ was introduced through portal 2 and atraumatic grasping forceps through portal 3. The splenic mass needs to be localized immediately to avoid damage during manipulation and localization is accomplished by elevating the splenic tail using grasping forceps, which allows ventral observation of the spleen (Fig 2A). Minor hemorrhage during mobilization with grasping forceps occurred due to splenic capsular tear; therefore, a fan retractor was enabled to lift the spleen as much as possible to allow better exposure of the splenic attachments. Starting at the caudal side of the spleen, vessels and attachments were closed and divided as narrowly as possible to the parenchyma. The fan retractor was then inserted through portal 2 and the Sonicision™ through portal 3 after dissecting the tail of the spleen. Hilar vessels and short gastric vessels were

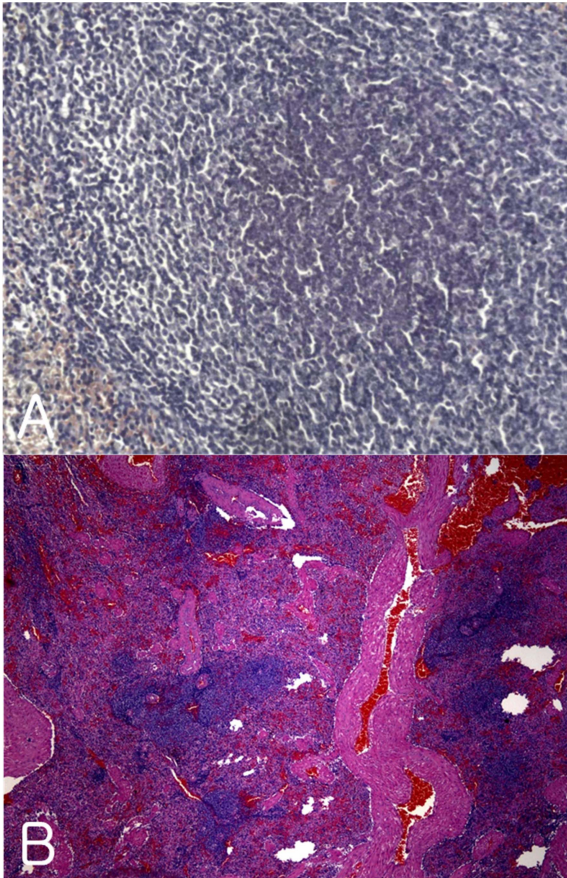


Fig 4. Histopathological images of resected masses (H&E-stained). Various sizes of lymphocytes (A: $\times 100$) and splenic lymph follicle fibrosis (B: $\times 40$) in spleen.

sealed as close to the spleen as possible, then cut with the SonicisionTM. Portal 2 was exchanged with a 12 mm trocar to insert an Endo-bag. Due to its small capacity, only the tail of the spleen and the mass is placed in the bag to minimize the risk of bleeding and seeding of the peritoneal cavity. Therefore, the detached spleen was carried out of the abdominal cavity using the Endo-bag. All portals were removed after turning off the insufflator, after which the incision was extended to 5 cm to allow the Endo-bag to be removed (Fig 3A) and submitted for histologic examination. Lymphoid hyperplasia was found in the detached spleen upon histopathological examination (Fig 4A).

Case 2

An 11-year-old, 5.0 kg, intact male Shih-tzu dog, was referred to the teaching animal hospital with stranguria with unremarkable findings upon evaluation for complete blood count, electrolytes and serum biochemistry. Splenic mass was identified upon ultrasonographic examination. The same anesthetic protocol was used as for case 1 after 12 hours of fasting and no water. The surgeon and the assistant operated while standing on the right side of the dog and looking at the monitor on the opposite side. A Verres needle was inserted through the abdominal wall. Pneumoperitoneum was established with CO₂ gas using an automatic high flow pressure and maintained at 12 mmHg. A 5-mm trocar-cannula was then positioned 2 cm cranial to the umbilicus (portal 1). Via this

cannula, 30° forward-oblique, a 5 mm laparoscope (Panoview Plus, Richard Wolf GmbH, Germany) was introduced into the peritoneal cavity from umbilical portal 1. With the laparoscope in place, the location, proximal and distal ends of the spleen was identified (Fig 2B). Portal 2 was placed on the midline, 1 cm cranial to the prepuce. Portal 3 was inserted 5 cm lateral and caudal to portal 2 while the dog was rotated onto his right (Fig 1B). The surgery was performed as for case 1 and the spleen was detached (Fig 3B) and submitted for histologic analysis. Histopathologic examinations of the resected spleen revealed splenic mass with nodular hyperplasia.

Both dogs recovered uneventfully after surgery. Abdominal incisions were closed with three separate sutures, one each in the abdominal musculature, subcutaneous tissue, and skin. After surgery, dogs were monitored for signs of pain and discomfort, administered butorphanol (0.02 mg/kg IV) and discharged within 3 days with courses of 0.1 mg/kg meloxicam (Metacam, Boehringer Ingelheim, USA) once a day for 3 days and 22 mg/kg cefadroxil (Uricef, Sungwon Adcock Pharm, Korea) twice a day for 6 days. The total duration of anesthesia was 1 hour and 47 minutes (case 1) and 1 hour and 28 minutes (case 2), while the surgical time was 1 hour (case 1) and 53 minutes (case 2). The time from portal insertion to splenic removal was 42 minutes (case 1) and 36 minutes (case 2).

Discussion

The laparoscopic procedure is beneficial for splenectomy in dogs, being valuable in terms of blood loss, surgical stress and surgical wounds. However, it requires more surgical time and causes a temporary increase in hepatic and muscular enzymes (11).

Despite the fact that laparoscopic splenectomy using SonicisionTM caused minor hemorrhage from splenic capsule tears as commonly reported in human cases (5), neither patients showed serious postoperative complications and both recovered rapidly from surgical removal of splenic nodules and mass. In a previous case of goats, use of gauze sponges inside atraumatic grasping forceps was found to greatly reduce complications (14). Specifically, splenic scratching can be avoided or reduced by operating on the spleen using a blunt probe or the body of an instrument such as a fan retractor. Hemoclip and intracorporeal ligatures, ultrasonic dissectors, diathermy and LigaSureTM have been found to be acceptable for vessel dissection (1,5,14). Laparoscopic procedures were performed with various instruments that require effective hemostasis, dissecting, cutting properties.

Ultrasonic technology is commonly used to accomplish these functions. This method uses microscopic longitudinal oscillation movements of the titanium blade to achieve the cutting mechanism (2). The Ultracision Ultrasonic Scalpel was the first generation ultrasonic blade. The next generation blade can be considered the Harmonic ACETM (2004), which was built upon the Ultracision technology. By using a slower frequency, the Olympus SonoSurgTM (1998) was able to achieve more precise hemostatic control than the Harmonic blade.

A third generation of devices is now emerging with the latest ultrasonic technology. Covidien Sonicision™ (2011) is the first cordless laparoscopic instrument that uses batteries instead of generators. This device has improved cutting speed relative to the previous generation devices, which were already much faster than bipolar technology (13). The cutting temperature was also higher than that of previous generation devices.

Sonicision™ provides better cuts with its hotter blade, while the SonoSurge gives more precise coagulation by heating slowly. Some instruments may be more suitable than others depending on the operation (9).

Conclusion

Despite the cost of Sonicision™, laparoscopic splenectomy using this device resulted in better outcome; therefore, it may be considered a suitable replacement for traditional splenectomy surgery, regardless of the size of a patient. The laparoscopic splenectomy technique could be useful in dogs with non-neoplastic splenic diseases and small splenic masses.

References

1. Brunt LM, et al., Comparative analysis of laparoscopic versus open splenectomy. *Am J Surg* 1996; 172: 596-601.
2. Cimino WW and LJ Bond, Physics of ultrasonic surgery using tissue fragmentation: Part I. *Ultrasound Med Biol* 1996; 22: 89-100.
3. Delaitre B and B Maignien, Laparoscopic splenectomy: One case. *Press Med* 1991: 20.
4. Gelmini R, et al., Sutureless and stapleless laparoscopic splenectomy using radiofrequency: LigaSure device. *Surg Endosc* 2006; 20: 991-994.
5. Glasgow RE and SJ Mulvihill, Laparoscopic splenectomy. *World J Surg* 1999; 23: 384-388.
6. Katkhouda N, et al., Laparoscopic splenectomy: Outcome and efficacy in 103 consecutive patients. *Ann Surg* 1998; 228: 568-578.
7. Kennedy JS, et al., High-burst-strength, feedback-controlled bipolar vessel sealing. *Surg Endosc* 1998; 12: 876-878.
8. Kim FJ, et al., Temperature safety profile of laparoscopic devices: Harmonic ACE (ACE), Ligasure V (LV), and plasma trisector (PT). *Surg Endosc* 2008; 22: 1464-1469.
9. Kim FJ, et al., Evaluation of emissivity and temperature profile of laparoscopic ultrasonic devices (blades and passive jaws). *Surg Endosc* 2015; 29: 1179-1184.
10. Park A, EM Targarona, and M Trías, Laparoscopic surgery of the spleen: State of the art. *Langenbeck's Archives of Surgery* 2001; 386: 230-239.
11. Stedile R, et al., Laparoscopic versus open splenectomy in dogs. *Pesq Vet Bras* 2009; 29: 653-660.
12. Tillson DM, Spleen. *Textbook of Small Animal Surgery* 2003: 1046-1062.
13. Tsirlina VB, et al., Evaluation of an innovative, cordless ultrasonic dissector. *Sur Innov* 2013; 20: 524-529.
14. Zhang JT, et al., Laparoscopic splenectomy in goats. *Vet Surg* 2009; 38: 406-410.