

A Thoracic Surgical Case Presented at the First Academic Meeting of the Chosun (Korean) Medical Association Held in 1947

Won-Gon Kim, M.D.

*Department of Thoracic & Cardiovascular Surgery, Seoul National University Hospital,
Seoul National University College of Medicine*

The late Prof. Kyeok Boo Han (1913–2005) was one of the pioneers in the early stages of the establishment of thoracic surgery in Korea. He was in charge of thoracic surgery at Seoul National University Hospital from 1948 to the outbreak of the Korean War in 1950. He presented a thoracic surgical case entitled “Adhesive (constrictive) pericarditis: one surgical case” at the first academic meeting of the Chosun (an old name for Korea) Medical Association, held in 1947. This presentation is considered to be the first thoracic surgical case presented by a Korean surgeon at a domestic medical meeting after the National Liberation from Japanese colonial rule in 1945. In this regard, this study was intended to analyze the content and the meaning of the case, published in a journal in 1948.

Key words: 1. History
2. Adhesive (constrictive) pericarditis

Currently, a variety of medical papers are presented annually, as talks or as posters, at many academic meetings both domestic and overseas. The field of thoracic and cardiovascular surgery is no exception.

However, the situation of about 70 years ago was completely different from that of today. Korea had just been liberated from Japanese colonial rule on Aug 15, 1945. At that time, Korea was in great turmoil due to social and political instability.

Because the medical profession could not exist separately from society as a whole, many medical activities were also marked by instability, irrespective of the joy of National Liberation.

Particularly thoracic and cardiovascular surgery, which demanded more defined surgical skill and cutting-edge equipment, was presented with more difficult challenges on the road toward the early domes-

tic establishment of the profession.

With this background, a thoracic surgical case was presented orally in May 1947, less than two years after National Liberation Day. Dr. KB Han in collaboration with Dr. KL Seo of the then Department of Surgery of Seoul National University Hospital presented a thoracic surgical case entitled “Adhesive pericarditis: one surgical case” at the first academic meeting of the Chosun (an old name for Korea) Medical Association held in the auditorium of Seoul National University Medical School in 1947 [1]. This presentation is considered to be the first thoracic surgical case presented by a Korean surgeon in a domestic medical meeting since National Liberation from Japanese colonial rule.

The content of the presentation and discussion at the meeting was formally published in the first issue of the “Journal of the Korean Medical Association(조

Received: February 12, 2016, Revised: March 8, 2016, Accepted: March 8, 2016, Published online: August 5, 2016

*Corresponding author: Won-Gon Kim, Department of Thoracic and Cardiovascular Surgery, Seoul National University Hospital, 101 Daehak-ro, Jongno-gu, Seoul 03080, Korea
(Tel) 82-2-2072-2346 (Fax) 82-2-762-3664 (E-mail) wongon@plaza.snu.ac.kr*

© The Korean Society for Thoracic and Cardiovascular Surgery. 2016. All right reserved.

© This is an open access article distributed under the terms of the Creative Commons Attribution Non-Commercial License (<http://creativecommons.org/licenses/by-nc/4.0>) which permits unrestricted non-commercial use, distribution, and reproduction in any medium, provided the original work is properly cited.

선의학협회보)” in 1948 (Fig. 1).

The paper itself was very brief, using the Korean alphabet mingled with Chinese characters. The content was as follows in literal fidelity to the original (Fig. 2).

Brief English translation: We performed pericardiectomy for a 30-year-old adhesive pericarditis patient.

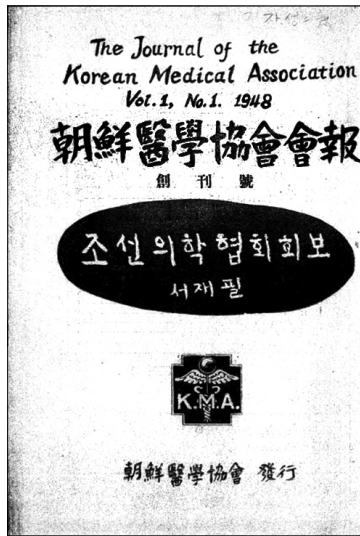


Fig. 1. Cover page of the “Journal of the Korean Medical Association” vol. 1, no. 1, 1948.

Operative findings showed the pericardium adhered externally to the pleura, internally to the myocardium. Adhesion was completely cicatricial. The post-operative course was good, but the long-term prognosis cannot be determined right now.

This text was followed by the content of the discussion between the two discussants (Dr. JG Lee and Dr. KS Min), as follows:

This published paper was in reality no more than a very short communication. No other significant information was found except brief personal data of the patient and operative findings of adhesive pericarditis. However, the surgical procedure (pericardiectomy) had a very important meaning, considering the general level of medicine in Korea at that time.

In order to find out more detailed information, I personally interviewed Dr. KB Han (then 87 years old) about this case in the year 2000. However, unfortunately, no helpful relevant material remained, and the personal memory of Dr. Han could not be depended on with the passing of a long period of time.

The operation was performed under local rather than general anesthesia, which is not easily understood by current standards. However, application of general anesthesia at that time was less safe than in




Fig. 2. (A, B) The page containing the paper “Adhesive pericarditis-one surgical case” published in the journal.

the present day. Therefore, if technically possible, it was desirable that a surgical procedure be performed under local anesthesia. In this case, it seems that the surgeon safely opened the pleural cavity without fear of massive air influx into the pleural cavity, even under local anesthesia, due to the strongly adhered pleural-peritoneal cavity.

Although the paper noted that no tuberculous or other particular pathologic change was identified at the time of operation, the cause of disease was considered tuberculosis under all possible circumstances of that time. This presumption was reinforced by another operative finding, in which pericardial adhesion proceeded to the status of complete 'Narbe' (a German word meaning 'scar'). The fact that the patient had a medical history of tuberculous peritonitis was taken as further evidence in support of a tuberculous origin of the disease.

The paper described the postoperative course as good. However, they had reservations about the long-term prognosis. In this regard, there is a possibility that pericardiectomy was not completely or successfully accomplished, except in terms of short-term postoperative survival. Perhaps this is not strange, considering that the surgical procedure was performed under local anesthesia and with limited surgical experience of pericardiectomy.

At the end of this short paper, comments by two discussants were added. It was noted that the two discussants mentioned their past experience of bullet removal from the pericardial cavity and partial pericardial resection for tuberculous pericardial disease, respectively. It was also noted that one discussant commented as follows: "general anesthesia presents more risk of the occurrence of postoperative pulmonary infection than local anesthesia." This kind of comment also reflects the technical status of anesthesiology at that time.

In addition to the content, another interesting thing about this paper from the present viewpoint is found in the form of the paper.

First of all, it may be noted that almost all the content of the paper was written in Chinese characters, and German medical terms were used instead of English. This also seems to reflect the situation of the medical profession in those days. And it is evident that the word spacing in this writing is terrible.

The Korean Medical Association, which was in-

augurated on May 10, 1947, published the first issue of the "Journal of the Korean Medical Association(조선의학협회회보-朝鮮醫學協會會報)" on May 10, 1948. This journal changed its Korean name to "대한의학협회회보(大韓醫學協會會報)" with the same English title in the second annual issue, the next year (1949). But the publication of the third annual issue was postponed to 1958 following the outbreak of the Korean War. The Korean name of third issue was changed again to "대한의학협회잡지(大韓醫學協會雜誌)."

The late Dr. KB Han (1913-2005) was born at Jeongpyeong in Hamgyongpukdo (now in North Korea). He graduated from Gyeongseong Imperial University Medical College(경성제국대학, the old Seoul National University Medical School) during the Japanese colonial era [2,3]. After graduation, he worked in the Department of Surgery at Gyeongseong Imperial University Hospital. After National Liberation from Japanese imperial rule in 1945, he took office as an assistant professor of surgery at Seoul National University Hospital. But the outbreak of the Korean War altered his career, one way or another. He opened a private clinic in Busan in 1952.

Thereafter, his professional career was mainly based at the private clinic located in Seoul except for a short period of work as a professor at Pusan National University and as Director of Thoracic & Cardiovascular Surgery at the National Medical Center. His private clinic was very successful. And his ability in medical administration led him to serve as the first chairmen of the Korean Association of Thoracic & Cardiovascular Surgery (1966) and as two-time chairman of the Korean Medical Association



Fig. 3. A photo of the late Prof. KB Han with his family taken at the Yeoyido Airport, leaving for Sweden in 1956.

(the 20th, in 1970, and the 23rd, in 1976).

Dr. KB Han was first involved in thoracic and cardiovascular surgery after National Liberation from the Japanese rule, when the surgical specialty was subdivided within the Department of Surgery at the Seoul National University Hospital. He also had the experience of overseas training between June 1956 and May 1957 in Stockholm, Sweden under the tutorship of the famous cardiac surgeon Dr. Clarence Crafoord (1899–1983) at that time (Fig. 3).

But regrettably, after opening the private clinic, his contribution to the development of thoracic and cardiovascular surgery was not remarkable.

Conflict of interest

No potential conflict of interest relevant to this article was reported.

References

1. Han KB, Seo KL. *Adhesive pericarditis-one surgical case*. Korean J Med Assoc 1948;1:32.
2. Han KB. *The road of life in which I have lived like a dead stone*. Seoul: Jinyoungsa; 1990.
3. Seoul National University. *History of Department of Thoracic & Cardiovascular Surgery, Seoul National University Medical School*. Seoul: Seoul National University; 2000.