



Two cases of *TSC2/PKD1* contiguous gene deletion syndrome

Jihye You¹, Eungu Kang¹, Yoonmyung Kim¹, Beom Hee Lee¹, Tae-Sung Ko^{1,2}, Gu-Hwan Kim², Jin-Ho Choi¹, and Han-Wook Yoo^{1,2,*}

¹Department of Pediatrics, Asan Medical Center Children's Hospital, University of Ulsan College of Medicine, Seoul, Korea

²Medical Genetics Center, Asan Medical Center, University of Ulsan College of Medicine, Seoul, Korea

Tuberous sclerosis complex (TSC, MIM#191100) is an autosomal dominant neurocutaneous syndrome caused by mutation or deletion of *TSC1* encoding hamartin or *TSC2* encoding tuberin and characterized by seizure, mental retardation, and multiple hamartomas or benign tumors in the skin, brain, retina, heart, kidney, and lungs. The *TSC2* gene on chromosome 16p13.3 lies adjacent to the *PKD1* gene which is responsible for autosomal dominant polycystic kidney disease (MIM#173900). The *TSC2/PKD1* contiguous gene syndrome (*TSC2/PKD1* CGDS, MIM#600273) is caused by deletion of both *TSC2* and *PKD1* gene. We recently experienced a 15 month-old boy and a 26 month-old girl with *TSC2/PKD1* CGDS confirmed by multiplex ligation-dependent probe amplification (MLPA) analysis. They showed not only typical neurologic manifestations of TSC such as epilepsy, subependymal nodules, and subcortical tubers, but also polycystic kidney disease. The contiguous gene syndrome involving *PKD1* and *TSC2* should be suspected in children with enlarged polycystic kidneys and TSC. MLPA analysis is a useful method for the genetic confirmation of *TSC2/PKD1* CGDS.

Key words: Tuberous sclerosis, Autosomal dominant polycystic kidney disease, Polycystic kidneys, severe infantile with tuberous sclerosis, Multiplex polymerase chain reaction.

Introduction

Tuberous sclerosis complex (TSC, MIM#191100) is an autosomal dominant syndrome characterized by seizure, mental retardation, and multiple hamartomas in the brain, heart, skin, retina, kidneys, or liver. Random distributions of tumorous lesions cause variable features such as neurologic deficits, renal impairment, skin lesions, or retinal hamartomas. The gene mutation can be identified in 85% of patients: *TSC1* on chromosome 9q34, encoding hamartin, or *TSC2* on 16p13.3, encoding tuberin [1]. The incidence of TSC is estimated to be 1 in 6,000-11,000 births

[2]. Sporadic cases constitute two thirds of tuberous sclerosis cases. *TSC2* mutations are about four times more frequent in sporadic cases compared to *TSC1* mutations and cause a more severe phenotype [3].

Autosomal dominant polycystic kidney disease (ADPKD, MIM#173900) is a common renal disorder, occurring in approximately 1 in every 1,000 live births [4]. It is characterized by progressive bilateral renal cysts leading to renal failure in the fifth to seventh decade of life. Occasionally, liver cysts and intracranial aneurysm may occur. Mutations in *PKD1* on 16p13.3, encoding polycystin 1, or *PKD2* on 4q22, encoding

Received: 28 April 2016, Revised: 30 May 2016, Accepted: 31 May 2016, Published: 30 June 2016

*Corresponding author: Han-Wook Yoo, M.D., Ph.D.

Department of Pediatrics, Asan Medical Center Children's Hospital, University of Ulsan College of Medicine, 88 Olympic-ro 43-gil, Songpa-gu, Seoul 05505, Korea.

Tel: +82-2-3010-3374, Fax: +82-2-473-3725, E-mail: hwyoo@amc.seoul.kr

Conflict of interest: The authors declare that they do not have any conflicts of interest.

© This is an open-access article distributed under the terms of the Creative Commons Attribution Non-Commercial License (<http://creativecommons.org/licenses/by-nc/4.0/>) which permits unrestricted non-commercial use, distribution, and reproduction in any medium, provided the original work is properly cited.

© Copyright 2016 by the Korean Society of Medical Genetics

www.e-kjgm.org

polycystin 2, have been confirmed to cause ADPKD. *PKD1* gene mutations have been reported in 85% of patients, and 2-3% of these mutations are caused by large deletions [5].

TSC2/PKD1 contiguous gene deletion syndrome (*TSC2/PKD1* CGDS, MIM#600273) was first recognized by Brook-Carter et al. [6] in 1994 in a patient with tuberous sclerosis and cystic renal disease by identifying the deletion of both *TSC2* and *PKD1* genes. *TSC2/PKD1* CGDS can occur due to the adjacent location of the *TSC2* and *PKD1* genes. More cases have been reported in TSC patients with enlarged polycystic kidneys [7-14]. Although 5% of patients with TSC have *TSC2/PKD1* CGDS, there have been no report of patients with *TSC2/PKD1* CGDS in the Korean population. This study describes two cases of tuberous sclerosis with severe cystic renal disease, which were diagnosed with *TSC2/PKD1* CGDS by multiplex ligation-dependent probe amplification (MLPA) analysis.

Case

1. Case 1

The patient is the first baby of non-consanguineous Korean parents. He was born after 39 weeks of gestation with a birth weight of 3.12 kg, without any perinatal problems. At 5 months of age, he was brought to the outpatient clinic due to heart murmur and multiple cardiac masses. Two cardiac masses were located in the right ventricular outflow tract and right ventricular free wall at the anterior leaflet of the tricuspid valve (Fig. 1A). In addition, bilateral multiple renal cysts were found on the renal ultrasound (Fig. 1B).

At age 12 months, generalized tonic-clonic seizure developed, which was provoked by fever. The seizure persisted over 15 minutes with cyanosis, followed by postictal sleep. It was clustered, with 5 seizures occurring in one episode. His blood pressure was 103/45 mmHg, and his pulse rate was 108 beats per minute. His height and weight were 85.4 cm (standard deviation [SD], 0.87) and 12.7 kg (SD, 0.73), respectively. His head circumference was 48 cm (SD, 0.17). He had a hypopigmented nevus on the nape, but did not have palpable abdominal mass. Complete blood counts, serum electrolytes, liver enzymes, and routine urinalysis were all normal. Brain magnetic resonance imaging (MRI) revealed multiple subependymal nodules in the foramen of Monro and multiple cortical tubers with subcortical white matter changes in both cerebral hemispheres (Fig. 1C). Multiple retinal tumors were found upon ophthalmologic examination. There was no familial history of tuberous sclerosis and ADPKD. Phenobarbital was administered to control the seizures, but was discontinued after 14 days because of adverse events such as skin rash and pruritus. He did not experience an additional seizure until age 30 months, when his height and weight were 95.6 cm (SD, 1.54) and 14.8 kg (SD, 0.85), respectively. His development was also normal.

For genetic testing, informed consent was obtained from both parents. Genomic DNA was isolated from the patient's peripheral leukocytes. MLPA analysis using probe-mixes for *TSC2* and *PKD1*, P046-B2 and P351-B2 (MRC-Holland, Amsterdam, The Netherlands), identified a large deletion of *PKD1* from exons 39 to 46 and *TSC2* from exons 26 to 41 (Fig. 2A).

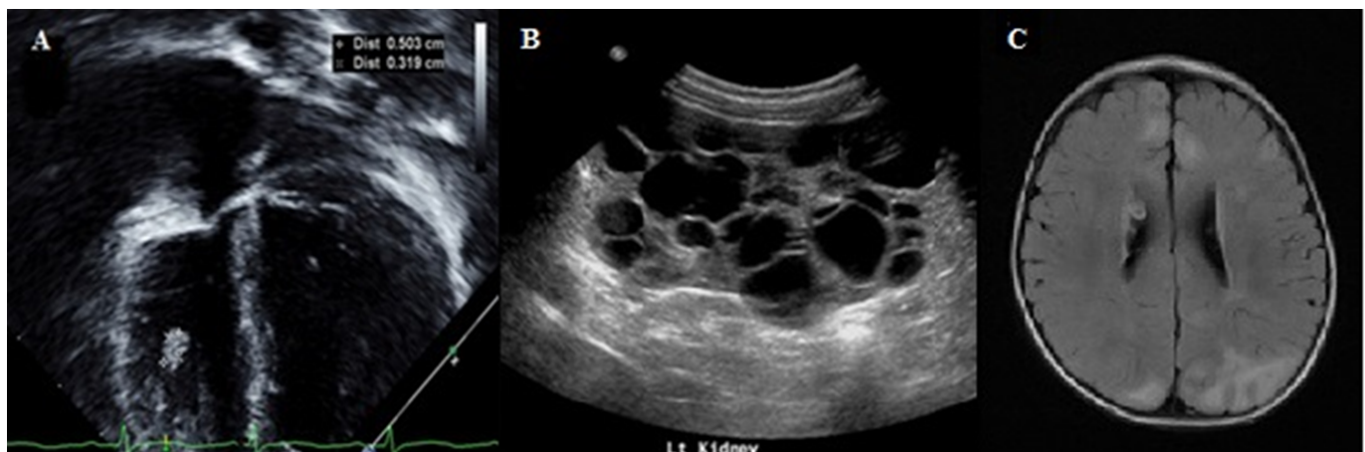


Fig. 1. Cardiac, renal and neurological findings of patient 1. (A) Echocardiography shows two cardiac masses on the right ventricular free wall. (B) Bilateral enlarged kidneys with multiple cysts are noted in renal ultrasonography (left kidney length, 11.8 cm). (C) Brain magnetic resonance image reveals multiple cortical tubers with high signal intensities in subcortical white matter and radial white matter bands in both cerebral hemispheres and multiple subependymal nodules with or without calcifications in axial T2 fluid-attenuated inversion recovery (FLAIR) image.

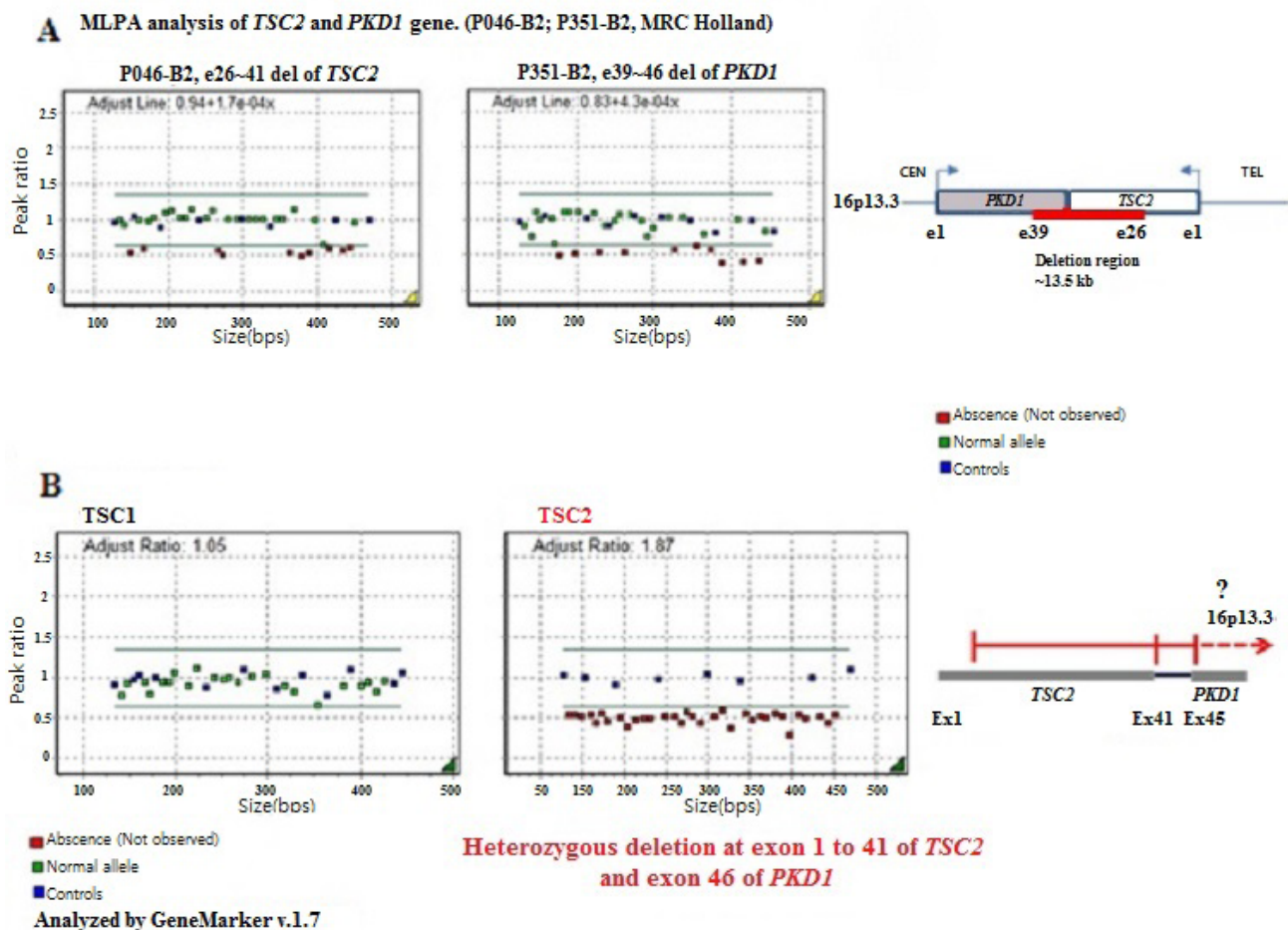


Fig. 2. The genetic findings of patient 1 and 2. (A) Multiplex ligation-dependent probe amplification (MLPA) analysis of Case 1 shows large deletion of *PKD1* from exon 39 to exon 46 and contiguous *TSC2* deletion from exon 26 to 41 by probe-mixes for *TSC2* and *PKD1*, P046-B2 and P351-B2 (MRC-Holland, Amsterdam, The Netherlands). (B) Whole exonic deletions of *TSC2* and *PKD1* are showed in MLPA analysis in Case 2.

2. Case 2

The patient was born prematurely after 35 weeks of gestation with a birth weight of 2.3 kg due to preterm premature rupture of membrane. At 2 months of age, β -blocker was administered because of left forearm hemangioma. At 5 months of age, an atrial septal defect was observed by echocardiography, without a cardiac mass. Hypopigmented macules were detected on the left lower leg and anterior chest. At 8 months of age, generalized tonic-clonic seizure developed with fever, and redeveloped at age 10 months. At 26 months of age, she was referred to the emergency room because of recurrent seizures with cyanosis and loss of consciousness, which repeated 6 times within a day. On physical examination, blood pressure was 98/56 mmHg and pulse rate was 132 beats per minute. Height and weight were 90.0 cm (SD, 0.45) and 14.4 kg (SD, 1.74), respectively. Facial dysmorphism or adenoma sebaceum was not found. She had hemangioma on the left forearm and hypopigmented patches on the anterior chest, left shoulder, and left leg. There was no palpable abdominal mass. Complete blood counts, liver enzymes,

and other blood chemical tests were normal. Brain MRI revealed multiple cortical and subcortical tubers in bilateral hemispheres and several tiny subependymal hamartomas along the wall of both lateral ventricles (Fig. 3A). On the electroencephalogram, occasional theta or delta slow wave discharges from left fronto-temporo-parietal areas were detected (Fig. 3B). No anatomical anomaly was detected by echocardiography. Abdominal sonogram demonstrated small echogenic oval lesions without increased vascularity, suggesting angiomyolipoma in the left kidney middle pole, and multiple small (<1 cm) cysts in both kidneys (Fig. 3C). Ophthalmologic examination detected yellowish elevated lesions near the superior temporal vascular arcade on the right fundus, suggesting retinal hamartoma. There was no familial history of tuberous sclerosis and ADPKD.

MLPA analysis identified heterozygous deletion at all 41 exons of *TSC2* and at exon 46 of *PKD1* (Fig. 2B). Since whole *PKD1* MLPA was not conducted, the exact extent of exon deletion was not identified. However, we can guess that the deletion may disrupt parts of the *PKD1* gene, as the deletion of exon 46 in

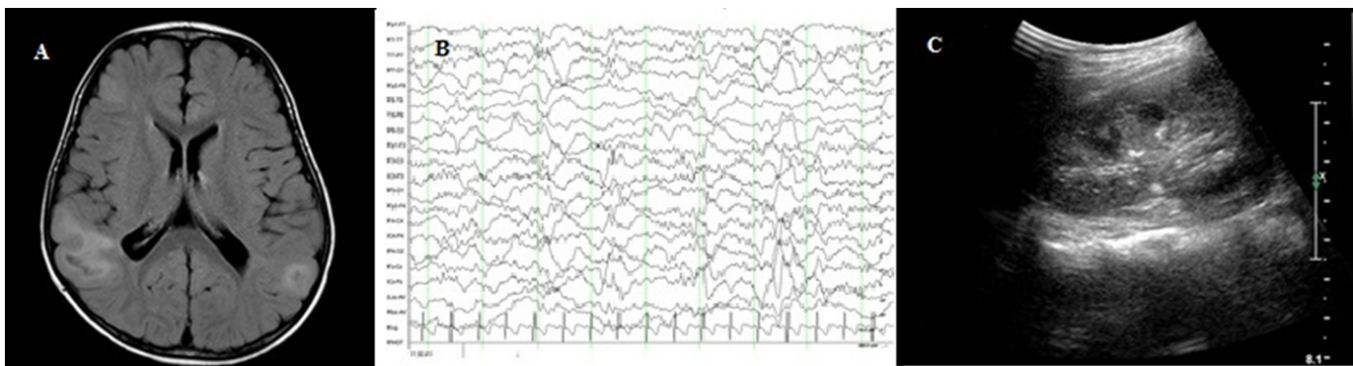


Fig. 3. Neurological and renal findings of patient 2. (A) Brain magnetic resonance image demonstrates multiple cortical and subcortical tubers with high signal intensities expanding gyri in bilateral hemisphere and multiple small subependymal nodules along wall of both ventricles without ventriculomegaly in axial T2 fluid-attenuated inversion recovery (FLAIR) image. (B) Occasional theta or delta slow wave discharges from left fronto-temporo-parietal areas were detected on electroencephalogram. (C) Kidney ultrasonography shows multiple small cysts in both kidneys. A small angiomyolipoma is seen in the middle pole of left kidney (left kidney length, 6.1 cm).

PKD1 has been identified.

Discussion

In the current report, we described two cases of gross deletions in the *TSC2* and *PKD1* genes in Korean patients with TSC and ADPKD. This is the first report of *TSC2/PKD1* CGDS in the Korean population. The large deletion involved exons 39 to 46 of *PKD1* and exons 26 to 41 of *TSC2*, as revealed in Case 1 by MLPA. Although the precise length of deletion of the *PKD1* gene was not identified, Case 2 also showed the large deletion involved *TSC2* and *PKD1*. As the *TSC2* gene and the *PKD1* gene lie adjacent to each other in a tail-to-tail arrangement, it is possible that deletion of *TSC2* can occur together with *PKD1* deletion, leading to contiguous gene deletion syndrome.

Neurologic manifestation is the most common cause of morbidity and mortality in patients with tuberous sclerosis, followed by renal involvement. Renal angiomyolipoma is a common feature of tuberous sclerosis and leads to hemorrhage or torsion. In comparison to the renal manifestation of tuberous sclerosis, renal cystic disease is more common in ADPKD, causing hypertension, proteinuria and end-stage renal disease. In *TSC2/PKD1* CGDS, severe, infantile or childhood onset polycystic kidney disease is more frequent than isolated TSC or ADPKD [15]. The cysts are larger and space-occupying, subsequently causing hypertension and early onset end-stage kidney disease. More importantly, the regular radiological follow-up should be recommended because of the risk of malignant transformation [7]. Five percent of patients with tuberous sclerosis and nearly 10% of patients with ADPKD were reported to have renal cell carcinoma at a young age [16]. Although the frequency of renal

cell carcinoma in *TSC2/PKD1* CGDS is unknown, the risk of renal cell carcinoma is expected to be high.

The mechanism for renal cyst formation remains elusive, though hamartin, tuberin, and polycystin-1 have been known to play a role in maintaining cellular polarity and the length of primary cilia in pre-cystic renal tubule cells [17]. The mutations in *TSC2* and *PKD1* seem to produce a truncated tuberin which activates guanosine triphosphatase (GTPase), leading to a reduction in mammalian target of rapamycin (mTOR) stimulation. The disruption of these genes was expected to result in cyst enlargement through mTOR activation [9]. In recent studies, however, mTOR inhibitors were not successful in treating the renal involvement of TSC and ADPKD. Instead, mTOR inhibitor was effective in reducing angiomyolipoma volume in patients with TSC [18]. In patients with *TSC2/PKD1* CGDS as well, mTOR inhibitor was not effective for improving renal function, but produced the satisfactory effect of renal angiomyolipoma size reduction [9]. Renal involvement was shown in our patients even at the age of 12 months.

The extrarenal manifestations of *TSC2/PKD1* CGDS are not clearly identified. One report suggests that the pathological features of skin lesions from patients with contiguous gene syndrome were similar to those from patients with tuberous sclerosis [13]. It remains to be seen whether the neurologic, ocular, or cardiac manifestations in patients with this contiguous gene syndrome differ from those in patients with isolated tuberous sclerosis. A few case reports described the extrarenal manifestations of ADPKD, such as intracranial aneurysm with clinical manifestations of TSC [19]. Therefore, *TSC2/PKD1* CGDS should be suspected in those with extrarenal symptoms of ADPKD, such as visceral organ cysts, or intracranial aneurysms

additional to the clinical signs of TSC.

In conclusion, the contiguous gene syndrome involving *PKD1* and *TSC2* should be considered in patients with ADPKD and TSC. MLPA analysis has a confirmatory role in the diagnosis of *TSC2/PKD1* CGDS.

Acknowledgements

This study was supported by a grant from the National Research Foundation of Korea, funded by the Ministry of Education, Science, and Technology (2011-0019674).

References

- European Chromosome 16 Tuberous Sclerosis Consortium. Identification and characterization of the tuberous sclerosis gene on chromosome 16. *Cell* 1993;75:1305-15.
- Osborne JP, Fryer A, Webb D. Epidemiology of tuberous sclerosis. *Ann N Y Acad Sci* 1991;615:125-7.
- Dabora SL, Jozwiak S, Franz DN, Roberts PS, Nieto A, Chung J, et al. Mutational analysis in a cohort of 224 tuberous sclerosis patients indicates increased severity of *TSC2*, compared with *TSC1*, disease in multiple organs. *Am J Hum Genet* 2001;68:64-80.
- Gabow PA. Autosomal dominant polycystic kidney disease. *N Engl J Med* 1993;329:332-42.
- Fick GM, Gabow PA. Hereditary and acquired cystic disease of the kidney. *Kidney Int* 1994;46:951-64.
- Brook-Carter PT, Peral B, Ward CJ, Thompson P, Hughes J, Maheshwar MM, et al. Deletion of the *TSC2* and *PKD1* genes associated with severe infantile polycystic kidney disease--a contiguous gene syndrome. *Nat Genet* 1994;8:328-32.
- Paul E, Thiele EA, Shailam R, Rosales AM, Sadow PM. Case records of the Massachusetts general hospital. Case 26-2011. A 7-year-old boy with a complex cyst in the kidney. *N Engl J Med* 2011;365:743-51.
- Back SJ, Andronikou S, Kilborn T, Kaplan BS, Darge K. Imaging features of tuberous sclerosis complex with autosomal-dominant polycystic kidney disease: a contiguous gene syndrome. *Pediatr Radiol* 2015;45:386-95.
- Cabrera-López C, Bullich G, Martí T, Català V, Ballarín J, Bissler JJ, et al. Insight into response to mTOR inhibition when *PKD1* and *TSC2* are mutated. *BMC Med Genet* 2015;16:39.
- Longa L, Scolari F, Brusco A, Carbonara C, Polidoro S, Valzorio B, et al. A large *TSC2* and *PKD1* gene deletion is associated with renal and extrarenal signs of autosomal dominant polycystic kidney disease. *Nephrol Dial Transplant* 1997;12:1900-7.
- Oyazato Y, Iijima K, Emi M, Sekine T, Kamei K, Takanashi J, et al. Molecular analysis of *TSC2/PKD1* contiguous gene deletion syndrome. *Kobe J Med Sci* 2011;57:E1-10.
- Llamas Velasco S, Camacho Salas A, Vidales Moreno C, Ceballos Rodríguez RM, Murcia García FJ, Simón de la Heras R. *TSC2/PKD1* contiguous gene deletion syndrome. *An Pediatr (Barc)* 2013;79:42-5.
- Kacerovska D, Vrtel R, Michal M, Vanecek T, Vodicka R, Kreuzberg B, et al. *TSC2/PKD1* contiguous gene syndrome: a report of 2 cases with emphasis on dermatopathologic findings. *Am J Dermatopathol* 2009;31:532-41.
- Ismail NF, Nik Abdul Malik NM, Mohseni J, Rani AM, Hayati F, Salmi AR, et al. Two novel gross deletions of *TSC2* in Malaysian patients with tuberous sclerosis complex and *TSC2/PKD1* contiguous deletion syndrome. *Jpn J Clin Oncol* 2014;44:506-11.
- Sampson JR, Maheshwar MM, Aspinwall R, Thompson P, Cheadle JP, Ravine D, et al. Renal cystic disease in tuberous sclerosis: role of the polycystic kidney disease 1 gene. *Am J Hum Genet* 1997;61:843-51.
- Hajj P, Ferlicot S, Massoud W, Awad A, Hammoudi Y, Charpentier B, et al. Prevalence of renal cell carcinoma in patients with autosomal dominant polycystic kidney disease and chronic renal failure. *Urology* 2009;74:631-4.
- Bonnet CS, Aldred M, von Ruhland C, Harris R, Sandford R, Cheadle JP. Defects in cell polarity underlie TSC and ADPKD-associated cystogenesis. *Hum Mol Genet* 2009;18:2166-76.
- Walz G, Budde K, Mannaa M, Nürnberger J, Wanner C, Sommerer C, et al. Everolimus in patients with autosomal dominant polycystic kidney disease. *N Engl J Med* 2010;363:830-40.
- Bisceglia M, Galliani C, Carosi I, Simeone A, Ben-Dor D. Tuberous sclerosis complex with polycystic kidney disease of the adult type: the *TSC2/ADPKD1* contiguous gene syndrome. *Int J Surg Pathol* 2008;16:375-85.