

Evaluation of canalis basilaris medianus using cone-beam computed tomography

Ali Z. Syed^{1,*}, Samir Zahedpasha¹, Sonali A. Rathore², Mel Mupparapu³

¹Department of Oral and Maxillofacial Medicine and Diagnostic Sciences, CWRU School of Dental Medicine, Cleveland, OH, USA

²Department of Oral Diagnostic Sciences, VCU School of Dentistry, Richmond, VA, USA

³Division of Radiology, University of Pennsylvania School of Dental Medicine, Philadelphia, PA, USA

ABSTRACT

The aim of this report is to present two cases of canalis basilaris medianus as identified on cone-beam computed tomography (CBCT) in the base of the skull. The CBCT data sets were sent for radiographic consultation. In both cases, multi-planar views revealed an osseous defect in the base of the skull in the clivus region, the sagittal view showed a unilateral, well-defined, non-corticated, track-like low-attenuation osseous defect in the clivus. The appearance of the defect was highly reminiscent of a fracture of the clivus. The borders of osseous defect were smooth, and no other radiographic signs suggestive of osteolytic destructive processes were noted. Based on the overall radiographic examination, a radiographic impression of canalis basilaris medianus was made. Canalis basilaris medianus is a rare anatomical variant and is generally observed on the clivus. Due to its potential association with meningitis, it should be recognized and reported to avoid potential complications. (*Imaging Sci Dent* 2016; 46: 141-4)

KEY WORDS: Cone-Beam Computed Tomography; Skull Base; Anatomical Variation; CBM

Clinicians are increasingly utilizing Cone-Beam Computed Tomography (CBCT) in the field of dentistry for various diagnostic tasks.^{1,2} It provides volumetric information, orthogonal reconstruction, and cross-sectional image data.³ Reconstructed orthogonal images provide geometrically concordant linear measurements which is not possible with conventional 2D imaging.^{3,4} CBCT scans can be obtained with different fields of view (FOVs).² CBCT scans typically cover a larger FOV and capture not only the dentoalveolar region, but also the extragnathic region.² This leads to the possibility of identifying incidental findings outside the region of interest, such findings may sometimes be overlooked by untrained eye.^{2,6,7} Previous data from literature suggests that approximately 25% of CBCT images obtained for various maxillofacial diagnostic tasks displayed incidental findings.^{6,8}

The clivus is a very important part of the skull base and

is usually captured in large FOV scans. The clivus may be associated with multiple anatomical variations and pathologies, such as canalis basilaris medianus (CBM), chondroma etc. CBM is an uncommon anatomical variant of the basiocciput.⁹ Jacquemin et al.⁹ stated that Gruber was the first to describe about CBM. Clinically asymptomatic, it is a congenital defect that has been observed in approximately 2% of dry skulls.^{9,10} CBM has been broadly classified into complete or incomplete channel types.⁹ Two theories have been proposed regarding the origin of this transclivial defect. One is vascular theory and another one is notochordal theory. Vascular theory states that it could have originated from emissary vein. Notochord theory predicates that this defect could be reminiscent part of notochord.^{9,10} Previous studies have evaluated CBM using dry skulls, computed tomography (CT) and magnetic resonance imaging (MRI).^{9,10}

This report describes two presumed cases of CBM detected utilizing the CBCT imaging modality along with a review of the literature. To the best of our knowledge, this is the first case series to be reported using CBCT imaging.

Received December 10, 2015; Revised February 14, 2016; Accepted February 24, 2016

*Correspondence to : Dr. Ali Z. Syed

Department of Oral and Maxillofacial Medicine and Diagnostic Sciences, CWRU School of Dental Medicine, 10900 Euclid Avenue, Cleveland, OH 44106, USA
Tel) 1-216-368-6802, Fax) 1-215-573-7853, E-mail) azs16@case.edu

Copyright © 2016 by Korean Academy of Oral and Maxillofacial Radiology

This is an Open Access article distributed under the terms of the Creative Commons Attribution Non-Commercial License (<http://creativecommons.org/licenses/by-nc/3.0>) which permits unrestricted non-commercial use, distribution, and reproduction in any medium, provided the original work is properly cited.

Imaging Science in Dentistry · pISSN 2233-7822 eISSN 2233-7830

Case Report

Case 1

The CBCT data of a 11-year-old female was referred to evaluate radiolucency in the apical area of the maxillary left lateral incisor. The patient presented with no clinical symptoms and had a non-contributory medical history. The CBCT scan was obtained with i-CAT unit (Imaging Science, Hatfield, PA, USA). The Digital Imaging and Communications in Medicine (DICOM) deidentified data was sent through a Health Insurance Portability and Accountability Act-compliant secure email (Brightsquid, Ross Technology Centre, Calgary, Alberta, Canada) and the data was evaluated using InVivo5.4.3 (Anatomage, San Jose, CA, USA).

All data was evaluated by two board-certified oral and maxillofacial radiologists (SAZ, SAR). The orthogonal views of the large FOV revealed an incidental finding in the clivus. It was observed that the sagittal view was optimal for the visualization of this entity because of its extension in the anteroposterior direction across the clivus. Radiographically CBM can be described as a well-defined, corticated and channel-like hypodense radiolucency extending from the pharyngeal aspect of the basiocciput to the intracranial aspect of the clivus. This radiographic pre-

sentation is pathognomonic representation of CBM. No other advanced imaging was advised since the patient was asymptomatic (Fig. 1).

Case 2

A 63-year-old female patient with a significant medical history of arthritis, thyroid disease, sinusitis, and gastrointestinal disease was referred for a CBCT scan. The volumetric scan was acquired via a CS9300 machine (Carestream Inc., Atlanta, GA, USA), and the patient was referred for the evaluation of a proposed implant site in the maxillary region. The data was analyzed using multiplanar reformatted slices by a board-certified oral and maxillofacial radiologist (MM). The volumetric data set revealed an unusual finding on the basiocciput of the clivus. In the sagittal view the intracranial part of the clivus showed discontinuity, the radiographic presentation of this osseous defect presentation can be described as a well-corticated, hypodense channel extending in the superior-inferior direction along the intracranial aspect of the clivus (Fig. 2). On initial inspection it appeared to be a fracture of the clivus. However, further close inspection revealed no other signs of osteolytic destruction on the posterior aspect of the clivus (intracranial surface). Based on the volumetric appearance of the defect, a radiographic impression of

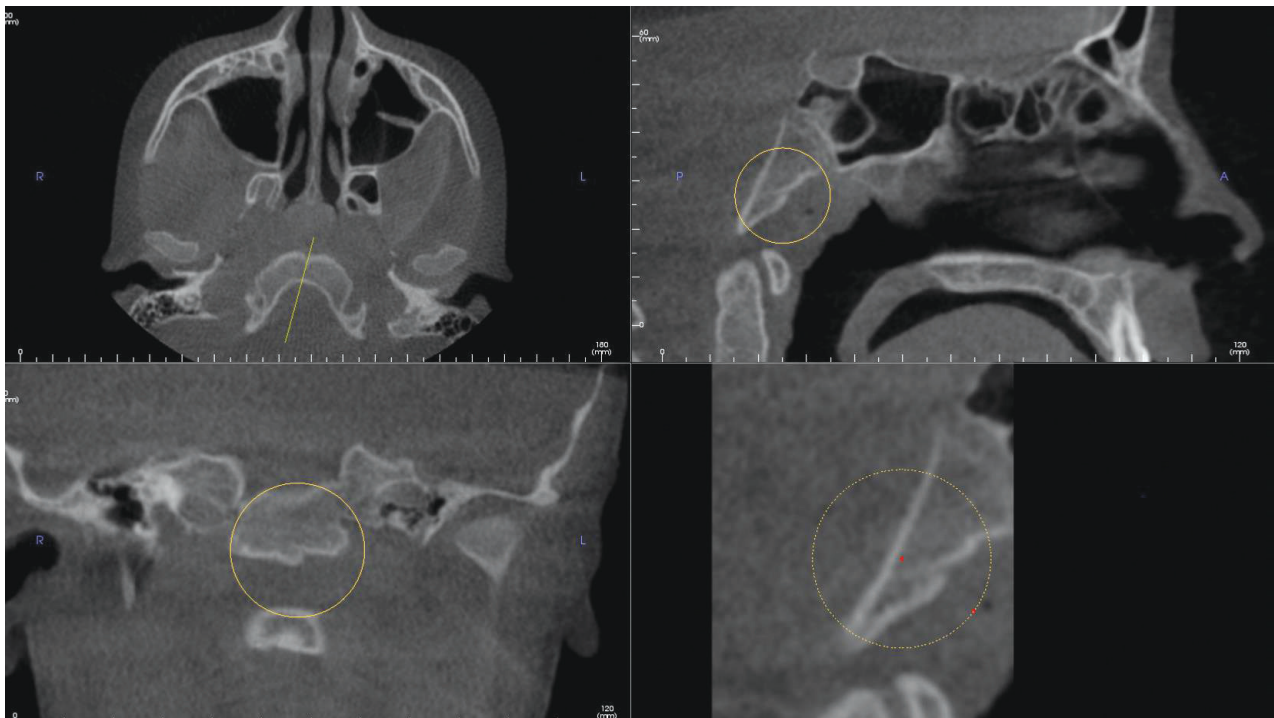


Fig. 1. Multiplanar reconstruction images demonstrate a defect on the basiocciput of the clivus consistent with canalis basilaris medianus in an 11-year-old female.

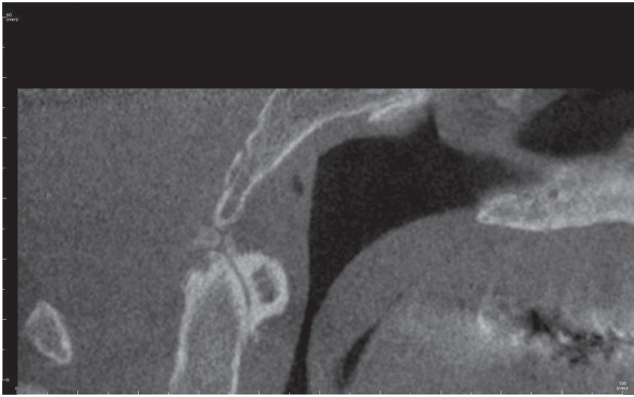


Fig. 2. A sagittal image demonstrates canalis basilaris medianus of the complete type on the superior aspect of the clivus.

CBM was made. This transclival defect can be best appreciated on the sagittal view. This entity depicted is an example of the complete type of CBM.

Discussion

The term CBM is used to describe transclival defect of the basicoccipt of the clivus. CBM presents itself in various configurations such as keyhole defect, transverse or longitudinally fissures in the clivus.¹² Radiological features of CBM can be described as a well-defined, corticated, osseous transclival defect located in the basiocciput of the clivus. In the axial view it is located in close approximation to the anterior rim of the foramen magnum.¹⁰ CBM's reported prevalence in the literature is 2%-3% for adults and 4%-5% in children.^{9,10}

Six varieties of CBM (Fig. 3) were described in the literature: three complete varieties (superior, inferior, and bifurcated) and three incomplete varieties (a thin, long channel; and either a superior recess; or an inferior recess).^{9,10} The complete type of CBM is characterized by the presence of a channel or tract like hypodense region extending either antero-posteriorly or superior-inferior direction occasionally, connecting the intracranial and pharyngeal portions of the clivus. Incomplete type will traverse partially within the clivus and they fail to communicate with pharyngeal portion or intracranial of the portion of the clivus.

CBM in general is considered an anatomical variant without any clinical significance.^{8,9} However, few studies indicate that they could serve as potential pathways for the progression of the disease such as meningitis.¹³ Hemphill et al.¹¹ and Martinez et al.¹² reported a transclival bony defect that was associated with a meningocele and caused

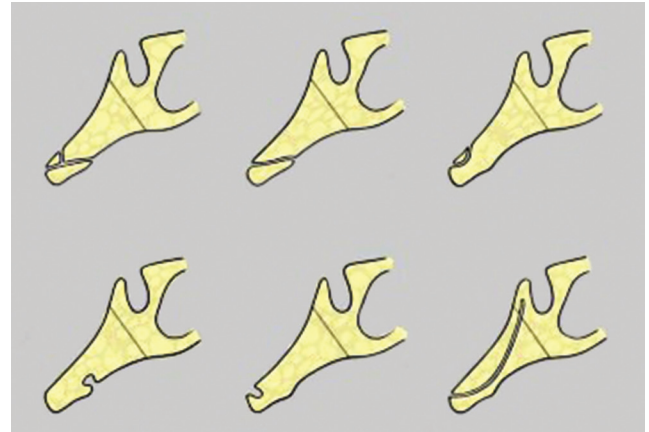


Fig. 3. A schematic diagram depicting the different types of canalis basilaris medianus (CBM). The top row illustrates the complete forms of CBM and the bottom row illustrates incomplete forms of CBM. Top row: bifurcating type (left) CBM inferior type (middle), superior type (right), and. Bottom row: inferior recess (left), superior recess (middle), and channel (right). (Adapted from Currano)

recurrent meningitis.

Jacquemin et al.⁹ presented a case of the incomplete inferior type of CBM. The osseous defect was located at the level of pharyngeal fossa. Their patient presented with atypical bacterial meningitis. However, authors argued that a mere coexistence of CBM and meningitis may not have caused detrimental effects such as optic neuropathy and the episode of sterile meningitis as noted in their case.⁹

Lohman et al.¹³ reported a CBM in association with a Tornwaldt cyst for the first time in the literature. Their case demonstrated the potential overlap of these entities.

Literature is providing conflicting reports about CBM's association with other pathological entities such as meningitis, Tornwaldt's cyst and its detrimental effects as noted in the above description. Further future studies are recommended to find its association with other pathological entities.

We reported two cases of CBM. First case described was incomplete type and second case was complete type of CBM, both cases were assessed using CBCT. In both the cases, the occurrence of CBM was not associated with meningitis or other problems. Our experience, as well as the literature as a whole, emphasizes the need for thorough analysis of skulls regardless of whether defects are detected or not when diagnostic tools such as CBCT, CT, and MRI are readily available.^{2,5} We recommend that all data should be interpreted by a board-certified oral and maxillofacial radiologist to prevent misdiagnoses and to avoid potential complications.⁷

Acknowledgements

We thank Ms. Sarah G. Jawhari, senior dental student from CWRU School of Dental Medicine for helping with the illustrating the diagram depicting six types of canalis basilaris medianus.

References

1. Horner K. Cone-beam computed tomography: time for an evidence-based approach. *Prim Dent J* 2013; 2: 22-31.
2. Syed AZ, Sin C, Rios R, Mupparapu M. Incidental occurrence of an unusually large mastoid foramen on cone-beam computed tomography and review of the literature. *Imaging Sci Dent*. 2016; 46: 39-45.
3. Haney E, Gansky SA, Lee JS, Johnson E, Maki K, Miller AJ, et al. Comparative analysis of traditional radiographs and cone-beam computed tomography volumetric images in the diagnosis and treatment planning of maxillary impacted canines. *Am J Orthod Dentofacial Orthop* 2010; 137: 590-7.
4. Liang X, Jacobs R, Hassan B, Li L, Pauwels R, Corpas L, et al. A comparative evaluation of cone beam computed tomography (CBCT) and multi-slice CT (MSCT) Part I. On subjective image quality. *Eur J Radiol* 2010; 75: 265-9.
5. Syed AZ, Mendes RA, Alnakhli TM, Pinto A. Thyroid papillary microcarcinoma: an incidental finding in a patient with coronoid hyperplasia. *BMJ Case Rep* 2015; 2015. pii: bcr2015212628
6. Newaz ZA, Barghan S, Katkar RA, Bennett JA, Nair MK. Incidental findings of skull-base abnormalities in cone-beam computed tomography scans with consultation by maxillofacial radiologists. *Am J Orthod Dentofacial Orthop* 2015; 147: 127-31.
7. Zinman EJ, White SC, Tetradis S. Legal considerations in the use of cone beam computer tomography imaging. *J Calif Dent Assoc* 2010; 38: 49-56.
8. Cha JY, Mah J, Sinclair P. Incidental findings in the maxillofacial area with 3-dimensional cone-beam imaging. *Am J Orthod Dentofacial Orthop* 2007; 132: 7-14.
9. Jacquemin C, Bosley TM, al Saleh M, Mullaney P. Canalis basilaris medianus: MRI. *Neuroradiology* 2000; 42: 121-3.
10. Currarino G. Canalis basilaris medianus and related defects of the basiocciput. *AJNR Am J Neuroradiol* 1988; 9: 208-11.
11. Hemphill M, Freeman JM, Martinez CR, Nager GT Long DM, Crumrine P. A new, treatable source of recurrent meningitis: basioccipital meningocele. *Pediatrics* 1982; 70: 941-3.
12. Martinez CR, Hemphill JM, Hodges FJ 3rd, Gayler BW, Nager GT, Long DM, et al. Basioccipital meningocele. *AJNR Am J Neuroradiol* 1981; 2: 100-2.
13. Lohman BD, Sarikaya B, McKinney AM, Hadi M. Not the typical Tornwaldt's cyst this time? A nasopharyngeal cyst associated with canalis basilaris medianus. *Br J Radiol* 2011; 84: e169-71.