

ORCIDMohammed Ahmed Hussein: orcid.org/0000-0002-5807-6628Yong Oock Kim: orcid.org/0000-0002-3756-4809

The Versatility of Cervical Vertebral Segmentation in Detection of Positional Changes in Patient with Long Standing Congenital Torticollis

Mohammed Ahmed Hussein, M.D., M.Sc.¹, Yong Oock Kim, M.D., Ph.D.²¹Department of Plastic and Reconstructive Surgery, Cairo University, Cairo, Egypt²Department of Plastic and Reconstructive Surgery, Institute of Human Tissue Restoration, Yonsei University, Seoul, Korea

Background Congenital muscular torticollis (CMT) is a benign condition. With early diagnosis and appropriate management, it can be cured completely, leaving no residual deformity. However, long-standing, untreated CMT can lead to permanent craniofacial deformities and asymmetry.

Methods Nineteen patients presented to the author with congenital muscular torticollis. Three dimensional computed tomography (3-D CT) scans was obtained upon patient's admission. Adjustment of skull's position to Frankfort horizontal plan was done. Cervical vertebral segmentation was done which allowed a 3D module to be separately created for each vertebra to detect any anatomical or positional changes.

Results The segmented vertebrae showed an apparent anatomical changes, which were most noticeable at the level of the atlas and axis vertebrae. These changes decreased gradually till reaching the seventh cervical vertebra, which appeared to be normal in all patients. The changes in the atlas vertebra were mostly due to its intimate relation with the skull base, while the changes of the axis were the most significant

Conclusion Cervical vertebral segmentation is a reliable tool for isolation and studying cervical vertebral pathological changes of each vertebra separately. The accuracy of the procedures in addition to the availability of many software that can be used for segmentation will allow many surgeons to use segmentation of the vertebrae for diagnosis and even for preoperative simulation planning.

Key Words Congenital muscular torticollis · Cervical vertebrae · Bone segmentation.

Received: June 14, 2016 / **Revised:** June 15, 2016 / **Accepted:** June 16, 2016

Address for correspondence: Yong Oock Kim, M.D., Ph.D.

Department of Plastic and Reconstructive Surgery, Institute of Human Tissue Restoration, Yonsei University, 50-1 Yonsei-ro, Seodaemun-gu, Seoul 03722, Korea

Tel: 82-2-2228-2218, **Fax:** 82-2-362-5680, **E-mail:** SGM625@YUHS.AC

Introduction

Torticollis is an old Latin term means "twisted neck" which is a symptom that represents various underlying diseases. CMT is one of the commonest causes of such condition. CMT defines as neck deformity that can be detected at the birth or immediately after birth due to shortening of the sternocleido-

mastoid muscle (1).

Although craniofacial deformities in CMT have been frequently studied from different perspectives, cervical spine changes in CMT have not been well studied because of the technical difficulties associated with isolation of the cervical vertebrae from the CT scans and even the MRI. Therefore, our study was focused on exploring the changes that might occur to the cervi-

This is an Open Access article distributed under the terms of the Creative Commons Attribution Non-Commercial License (<http://creativecommons.org/licenses/by-nc/3.0/>) which permits unrestricted non-commercial use, distribution, and reproduction in any medium, provided the original work is properly cited.

cal vertebrae of patients with known untreated CMT using the bone segmentation.

Materials and Methods

Nineteen patients diagnosed with CMT with clinically ap-

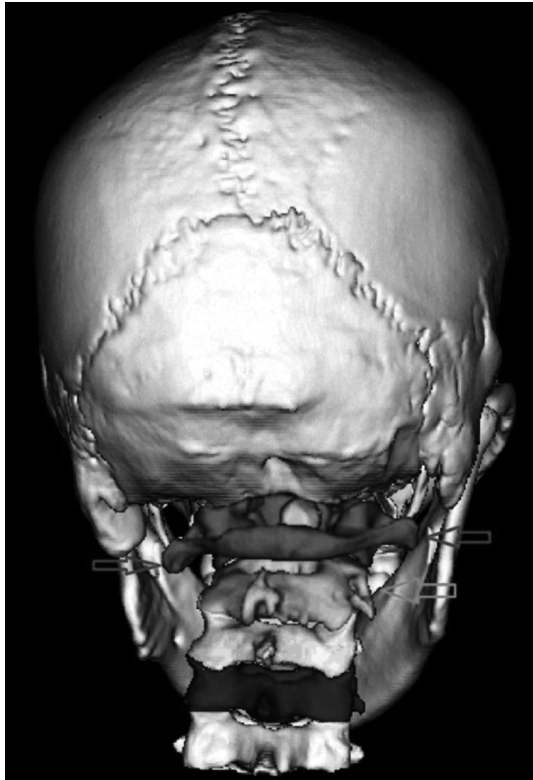


Fig. 1. Posterior view of the skull and cervical spine showing segmentation of the upper five cervical vertebrae with growth changes, most apparent on the level of the atlas and axis; red: atlas, green: axis, yellow: third vertebra, blue: fourth vertebra, and grey: fifth vertebra. The red arrow points to the level of the transverse process of the atlas vertebra, and the green arrow points toward the rotational deformity of the axis vertebra.

parent tight Sternocleidomastoid muscle on one side. Patients' ages ranged from 5 months to 38 years. Exclusion of other causes of torticollis had been done to confirm the CMT. Upon presentation, 3-D CT scans of the skull and cervical spine were obtained for further investigation. CT scans were obtained using Siemens TM CT scanner, Germany (Somatom Sensation 64, matrix size 512×512, Facial 1/1 mm pac). DICOM files of CT scan were obtained to be utilized through the software. All CT scans were adjusted to Frankfort horizontal plan (FHP) prior to segmentation process using the coordinate system. Segmentation of the cervical vertebrae was done using Analyze Direct AVW™, Mayo clinic, USA as showing in Fig. 1. Segmentation process was performed using the threshold based technique in which the bone was selected to be segmented either manually or semi-automated in each 2-D axial CT. A separate 3-D reconstructed module was created for each vertebra to be studied separately. This 3-D reconstruction enabled each vertebra to be translated and rotated freely. For each vertebra, the volumes of each side were measured to detect any significant change. In order to avoid any bias or error, adjustment of the position of vertebrae were adjusted before division to be vertically and horizontally aligned. The volume measurement was done utilizing the volume render measurement tool in Analyze Direct AVW™ software, also both sides were segmented initially to be divided and measured at the same threshold to avoid any bias due to different thresholds.

Results

There was change in the vertical height of the vertebral bodies, as showing in Fig. 2. The greatest difference was noticed at the level of the atlas and decrease gradually toward the seventh vertebra which had equal vertical height. The atlas vertebra showed significant bending deformity that matched the skull

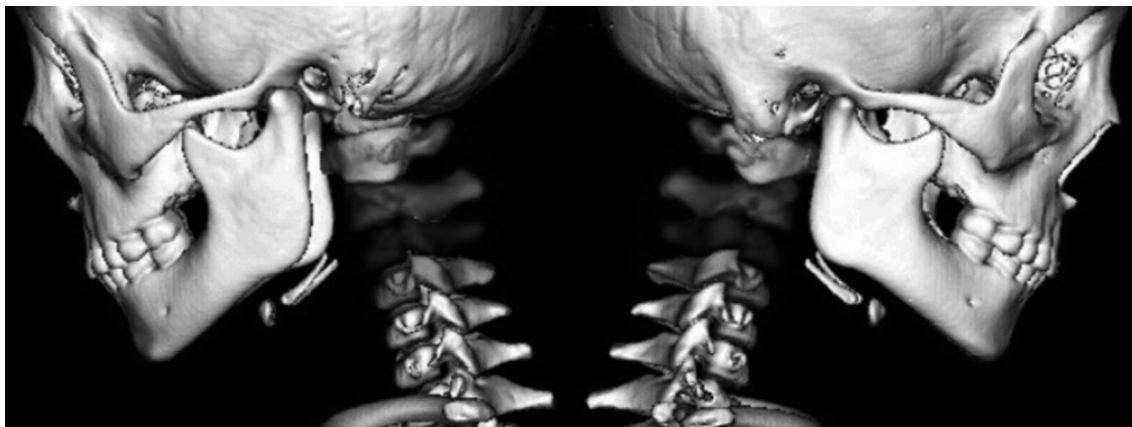


Fig. 2. Lateral view of 5 years old patient with segmentation of the upper 4 cervical vertebrae, showing difference in the vertical height of the upper 4 cervical vertebrae.

base shape. There was significant changes in the direction and level of transverse processes, which were more severe in the

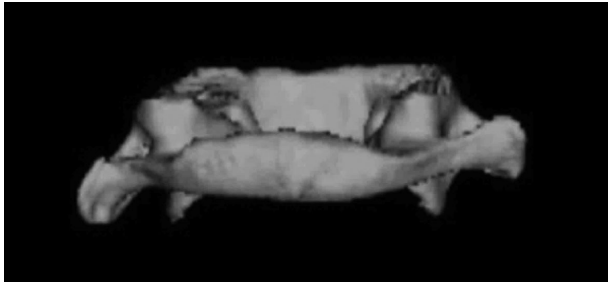


Fig. 3. Back view of the atlas vertebra, showing apparent changes in the level and the direction of the transverse processes; it is directed downwards on the affected side.

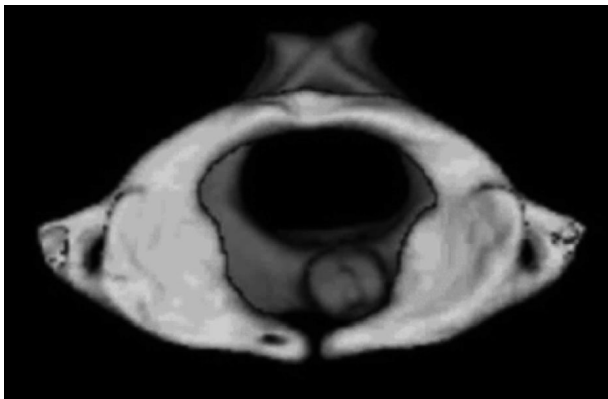


Fig. 4. Top view of both atlas and axis vertebrae of 8 years old boy, showing the relation between the atlas and axis with tilted odontoid process towards the unaffected side.

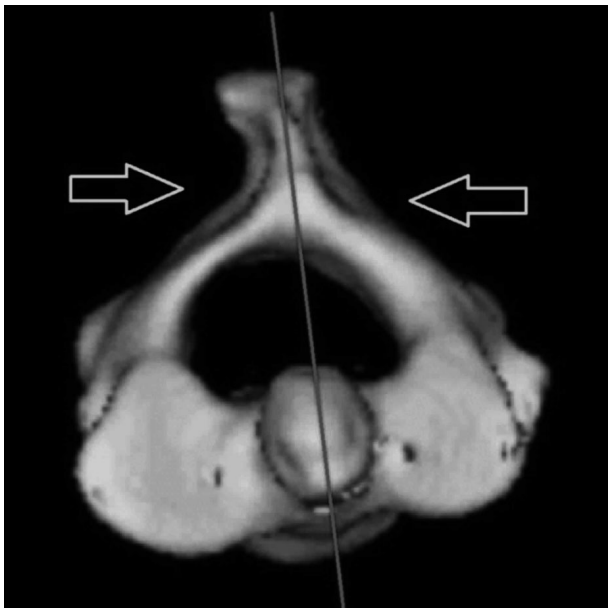


Fig. 5. Top view of the axis vertebra, with the midsagittal plane showing changes in the morphology of the lamina on both sides (yellow arrows), changes in the direction of the spinous processes, and changes in the shape and surface area of the superior articular facet.

older patient. There was also mild rotational deformity in comparison to the axis, as showing in Fig 3 and 4.

The axis vertebra showed the most significant deformity. Almost all of its components exhibited change. The odontoid process showed apparent tilting, and there was significant changes in the shape, slope, and size of the superior articular facet. The facet on the affected side showed a larger surface area and more sloping. Also, the lamina showed changes in its direction and curvature, since it appeared convex on the unaffected side and concave on other side, as showing in Figs. 5-8.

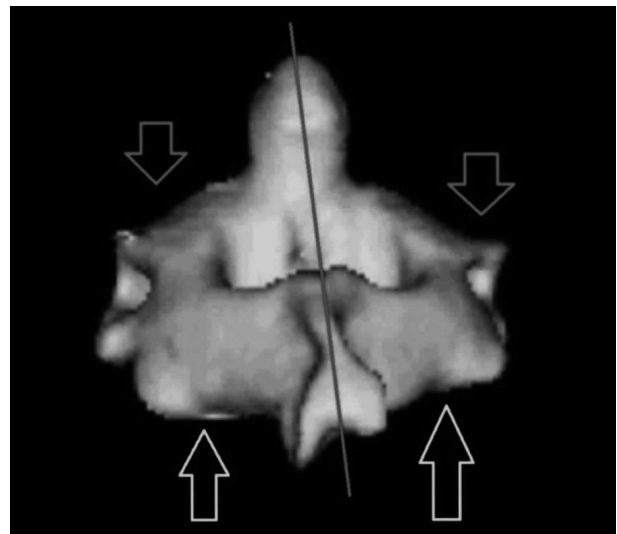


Fig. 6. Posterior view of the axis vertebra, with the midsagittal plane showing changes in the sloping of the superior articular facet (red arrows) and changes in the vertical height of the lamina (yellow arrows).

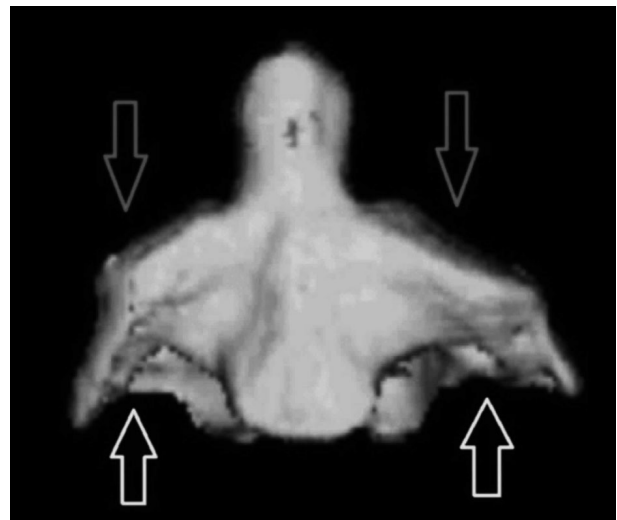


Fig. 7. Anterior view of the axis vertebra, showing changes in the sloping of the superior articular facet (red arrows) and changes of the vertical height on either side of the body of the vertebra (yellow arrows).

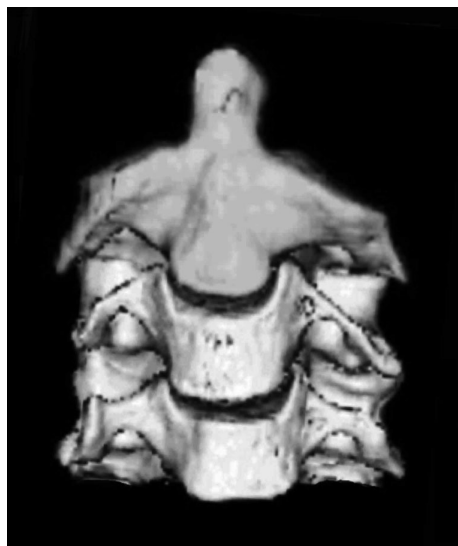

Fig. 8. Anterior view of the axis vertebra (green), with the third and fourth vertebrae showing sliding of the axis vertebra to the opposite side of the tilting along the C2-3 junction, as well as decreasing deformities along the third and fourth vertebrae.

Discussion

CMT is a benign condition, and with early diagnosis and appropriate management, it can be cured completely without any residual deformity. However, long-standing, untreated CMT can lead to permanent cranial and facial deformities and asymmetry (2). In addition to pain and a limitation of neck movement that might last forever (3), typical facial deformities include frontal bone depression, zygomatic bones asymmetry, a posteriorly positioned ear on the affected side, and deviation of the chin to the other side. On the cranial level, positional plagiocephaly is frequently detected in patients with CMT (4, 5).

Despite previously many authors reported some cervical vertebra changes in CMT, none of them were able to describe the full deformity that might occur in those patients, since most of those authors depended on the 3-D reconstructed images of the whole spine in the CT scans rather than studying the isolated vertebrae (6-8). For that the author underwent segmentation of the cervical vertebrae and reconstructed a 3-D module for each vertebra to be rotated and studied separately.

The bone segmentation in a CT scan is always considered as an important component of image-based computer assisted surgery. Despite the wide use of segmentation procedures, as well as the large number of research about the development of a fully automated software, this is remained a significant challenge. Many factors are contributing for such challenge including the inhomogeneous structure of bone, pathologies, and the inherent blurring of CT data.

Current approaches to bone segmentation in the CT images

can be classified as intensity-based, edge-based, region-based, or deformable. The simplest of the intensity-based methods is the manual segmentation, which has long been used to extract bone contours by manually selecting threshold value (9). Edge-based methods allow the separation of regions through the location of their contours as points of high values in an intensity gradient field (10) while Region-based methods divide images into regions that satisfy a given homogeneity criterion.

In cases where the output of segmentation is used to plan or even directly execute surgeries, segmentation errors could be critical. As result of that, the manual threshold base techniques still the gold standards for bone segmentation, however it is time consuming (11).

The CT scan segmentation of the cervical vertebrae had proved to be an accurate and efficient process. However, the manual segmentation technique for the spine is time consuming and need learning curve due to the poor or missing boundary interfaces across the vertebrae especially in adults, as well as the similarities in the radiological density of bone and surrounding tissues. This is exacerbated near joints, where the porous structure of the bone tissue lowers its density.

Conclusion

Cervical vertebral segmentation is a reliable tool for isolation and studying cervical vertebral pathological changes of each vertebra separately. The accuracy of the procedures in addition to the availability of many software that can be used for segmentation will allow many surgeons to use segmentation of the vertebrae for diagnosis and even for preoperative simulation planning.

References

1. Canasle ST, Griffin Dw and Hubbard CN. "Congenital muscular torticollis." *J Bone Joint Surg*, Vols. 64-A, pp. 810-6, 1982.
2. Jeong KY, Min KJ, Woo J, Yim SY. "Craniofacial Asymmetry in Adults With Neglected Congenital Muscular Torticollis." *Annals of Rehabilitation Medicine* 2015;39(3):440-450
3. Lim KS, Shim JS, Lee YS. "Is sternocleidomastoid muscle release effective in adults with neglected congenital." *Clin Orthop Relat Res* 2014;472:1271-1278
4. Seo SJ, Yim SY, Lee IJ, Han DH, Kim CS, Lim H, et al. "Is craniofacial asymmetry progressive in untreated congenital muscular torticollis?" *Plast Reconstr Surg* 2013;132:407-413
5. Yu CC, Wong FH, Lo LJ, Chen YR. "Craniofacial deformity in patients with uncorrected congenital muscular torticollis: an assessment from three-dimensional computed tomography imaging." 2004;113:24-33
6. Ozer T, Uzun L, Numanoğlu V, Savranlar A, Hoşnüter M, G. S. "3D-CT investigation of craniofacial and cervical spine anomalies in congenital muscular torticollis." *Tani Girişim Radyol Journal* 2004;10(4):272-279

7. Chen CE, Ko JY. "Surgical treatment of muscular torticollis for patients above 6 years of age." *Arch Orthop Trauma Surg* 2002;120:149-151
8. Oh I, Nowacek CJ. "Surgical release of congenital torticollis in adults." *Clin Orthop* 1978;131:141-145
9. Kang Y, Engelke K, Kalender WA. "A new accurate and precise 3-D segmentation method for skeletal structures in volumetric CT data." *IEEE Trans Med Imag* 2003;22:586-598
10. Pardo XM, Carreira MJ, Mosquera A, Cabello D. "A snake for CT image segmentation integrating region and edge information." *Image Vis Comput* 2001;19:461-475
- Sebastian TB, Tek H, Crisco JJ, Kimia BB. "Segmentation of carpal bones from CT images using skeletally coupled deformable models." *Med Image Anal* 2003;7:21-45