

ORCIDMohammed Ahmed Hussein: orcid.org/0000-0002-5807-6628Yong Oock Kim: orcid.org/0000-0002-3756-4809

The Reliability of Preoperative Simulation Surgery Planning for Distraction Osteogenesis in Craniosynostosis Patients

Mohammed Ahmed Hussein, M.D., M.Sc.¹, Yong Oock Kim, M.D., Ph.D.²¹Department of Plastic and Reconstructive Surgery, Cairo University, Cairo, Egypt²Department of Plastic and Reconstructive Surgery, Institute of Human Tissue Restoration, Yonsei University, Seoul, Korea

Background Craniosynostosis management using distraction osteogenesis represent a challenge for surgeons due to the great variability of the skull deformity even within the same etiology. The ability to apply the simulation surgery for improving the preoperative planning for distraction osteogenesis could improve the results.

Planning and Simulation 14 patients presented with craniosynostosis had been subjected to simulation surgery prior to real surgery. 3D CT scans was obtained upon patient admission. Adjustment of all skull position to Frankfort horizontal plane was done. 3 different distraction osteogenesis plans were done for each patient according to the skull morphology. For each plane, movement for each bone segment was done according to the pre-planned distraction vectors. Also the distances of distractions were pre-determined according to the cephalic index as well as brain volume. Intraoperatively, we choose the most appropriate plan for the patient by the surgeon. At the end of distraction, 3D CT scan was obtained, and was compared to the simulation plan. Also the distance and the direction of distraction was compared to that of the plan. Accordingly, the distance was almost matching that of the simulation surgery, however the vector of distraction was not matched.

Conclusion Preoperative stimulation planning for craniosynostosis patient is very valuable tool in the surgical management of craniosynostosis patients.

Key Words Simulation surgery · Craniocynostosis · Distraction osteogenesis.

Received: June 14, 2016 / **Revised:** June 15, 2016 / **Accepted:** June 16, 2016

Address for correspondence: Yong Oock Kim, M.D., Ph.D.

Department of Plastic and Reconstructive Surgery, Institute of Human Tissue Restoration, Yonsei University, 50-1 Yonsei-ro, Seodaemun-gu, Seoul 03722, Korea

Tel: 82-2-2228-2218, **Fax:** 82-2-362-5680, **E-mail:** SGM625@YUHS.AC

Introduction

The introduction of many advances as well as new simplified softwares in the field of basic scientific research within the field of computer assisted craniofacial surgery, had enabled the surgeons to introduce features of these techniques into routine clinical practice (2, 3). In order to simulate complex craniosynostosis surgery with the aid of a computer, various diagnostic image data should be included; computer tomography (CT), magnetic resonance imaging (MRI). This type of data should

be arranged in relation to each other, thus enabling a relevant switching between these various modalities as well as the viewing of superimposed results (6). Segmentation techniques of the calvarium as well as three dimensional reconstruction modules are usually a cornerstone for successful simulation planning (10). For that the author tried to develop ergonomic planning techniques, thus allowing for a precise and fast entry of the planned surgical procedure.

The aim of operation planning in oral and maxillofacial surgery is the optimization of the surgical result with regard to

This is an Open Access article distributed under the terms of the Creative Commons Attribution Non-Commercial License (<http://creativecommons.org/licenses/by-nc/3.0/>) which permits unrestricted non-commercial use, distribution, and reproduction in any medium, provided the original work is properly cited.

function and aesthetic aspects. However, for the distraction surgery of the cranium, the accurate distance and vectors of distraction can be aim of simulation surgery.

Planning and Simulation

The existence of suitable image data in the form of two- and

three-dimensional data sets is critical for successful preoperative planning. The CT offers the advantages of a precise reproducible local presentation as well as the high contrast presentation of osseous structures. The CT scans were obtained using the Siemens TM CT scanner (Germany; Somatom Sensation 64, matrix size 512×512, Facial 1/1 mm pac). The process of simulation planning started with obtaining DICOM files of

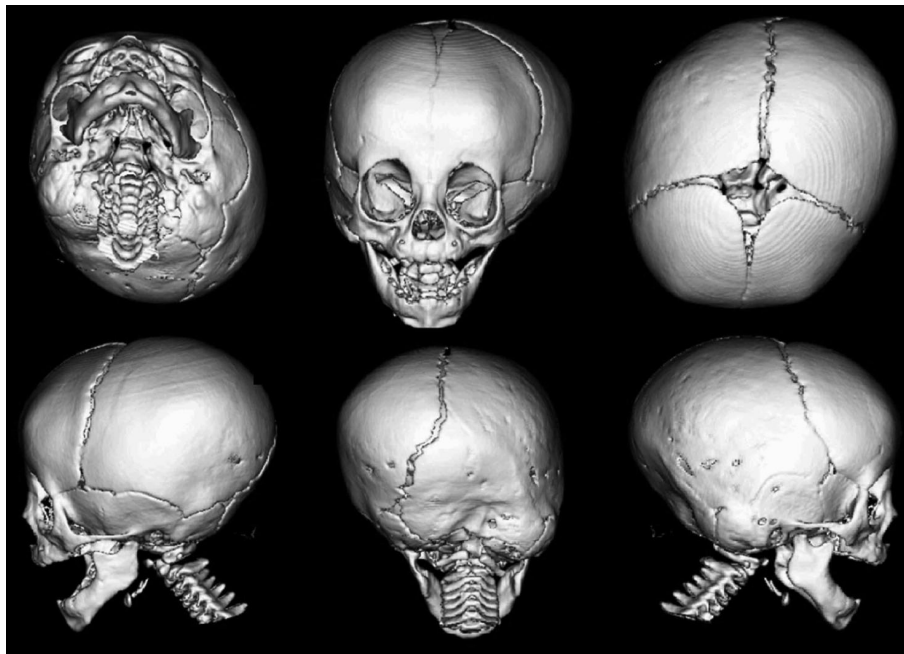


Fig. 1. Preoperative 3D CT scan of 9 months old patient with unilambdoid craniosynostosis. There is an apparent plagiocephaly with deviation of the skull axis towards the unaffected side.

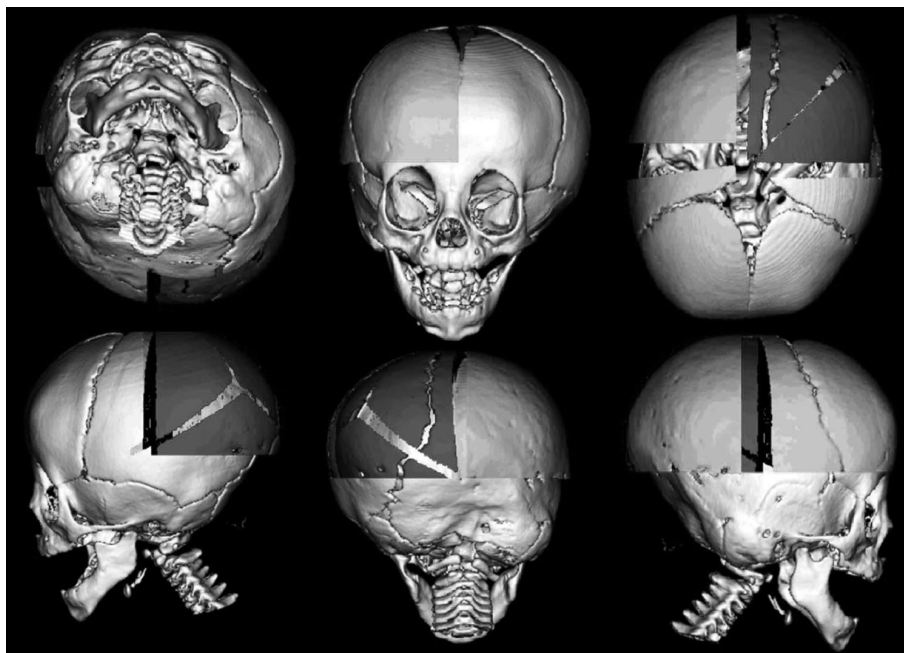


Fig. 2. 1st surgical plan of simulation for the Fig. 1 unilambdoid patient.

CT scan that can be easily utilized through the software. The Author had chosen the Analyze Direct AVW™ (Mayo Clinic, USA) software for the preparation of the simulation planning. All CT scans were adjusted to Frankfort horizontal plane (FHP) prior to segmentation process using the coordinate system as showing in Fig. 1 and 4. The segmentation process was done using the volume render module of the software. The simulation plan was based on standard brain volume as well as

the patient's cephalic index. The critical end point during the simulation plan is to achieve adequate cephalic index that able to allow improvement of the outcome.

For each patient, either two or three different simulation plans were made according to the quadrant based distraction osteogenesis procedures, as showing in Fig. 2, 3, 5 and 6. Virtual osteotomies were accomplished with creation of multiple bone segments that could be moved separately in the all three di-

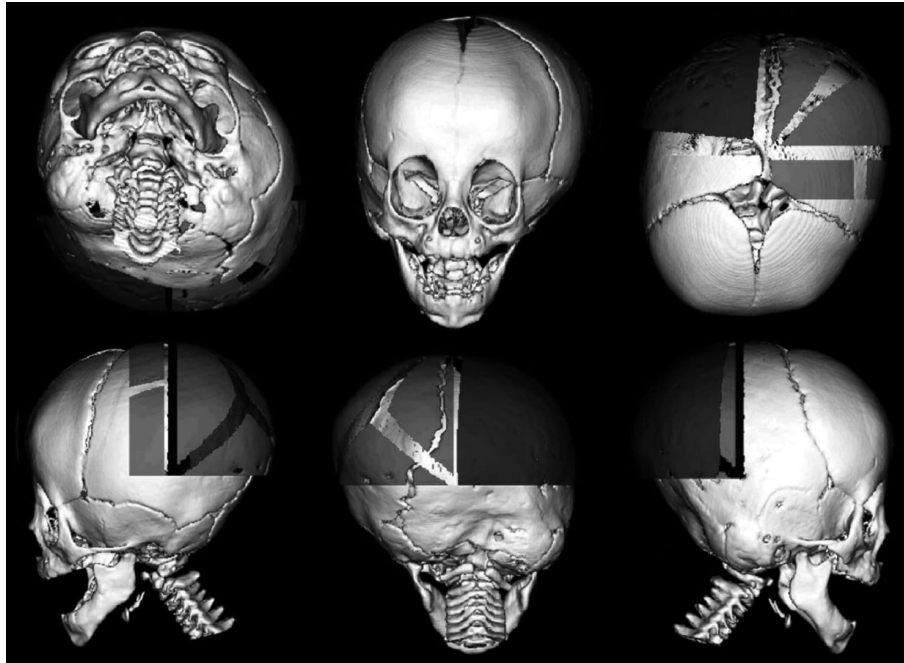


Fig. 3. 2nd surgical plan of simulation for the Fig. 1 unilambdoid patient.

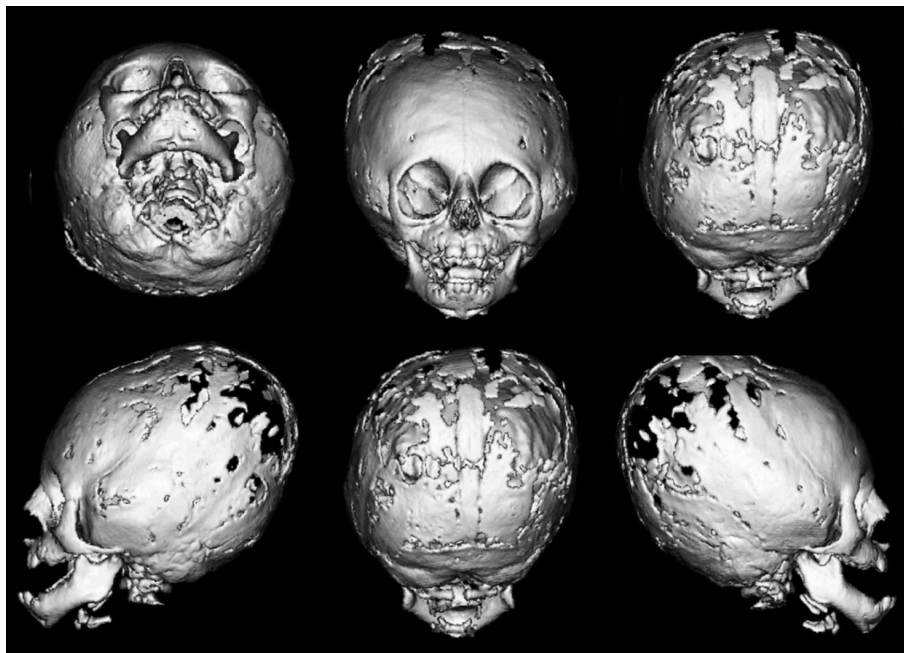


Fig. 4. Preoperative 3D CT scan of 11 months old patient with Crouzon syndrome.

mensions (X, Y and Z). For a better graphic quality, the individual bone segments are differentiated through the use of different colors. After determination of the optimal movement distance on the computer screen for each segment as well as the vector of distraction, the final cephalic index was calculated.

Generally, the aim of the simulation or even the surgery itself was to reach the ideal shape of the head. Choice of the most appropriate surgical plan was done by the surgeon according to

patient's skull shape, intraoperatively.

During the distraction process, multiple skull X-rays were obtained to follow up the distraction process as well as the distraction vector. And by the end of distraction, 3D CT scan was obtained for the patients and was compared to the initial simulation plan. Also the distance and the direction of distraction was compared to that of the simulation plan, respectively. As a results, the distance was almost matched to that of the simula-

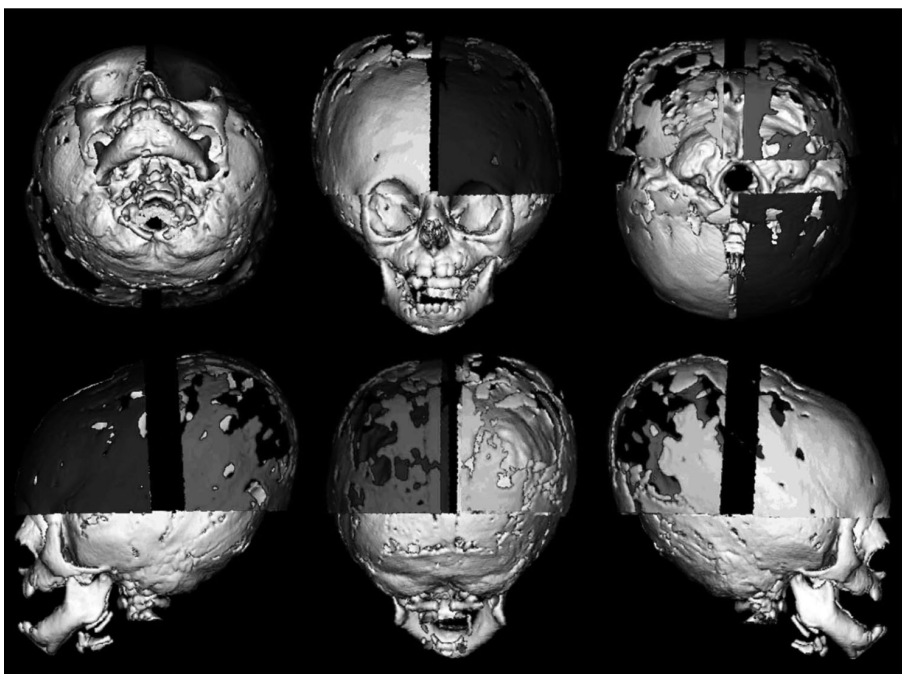


Fig. 5. 1st surgical plan of simulation for the Fig. 4 Crouzon's syndrome patient.

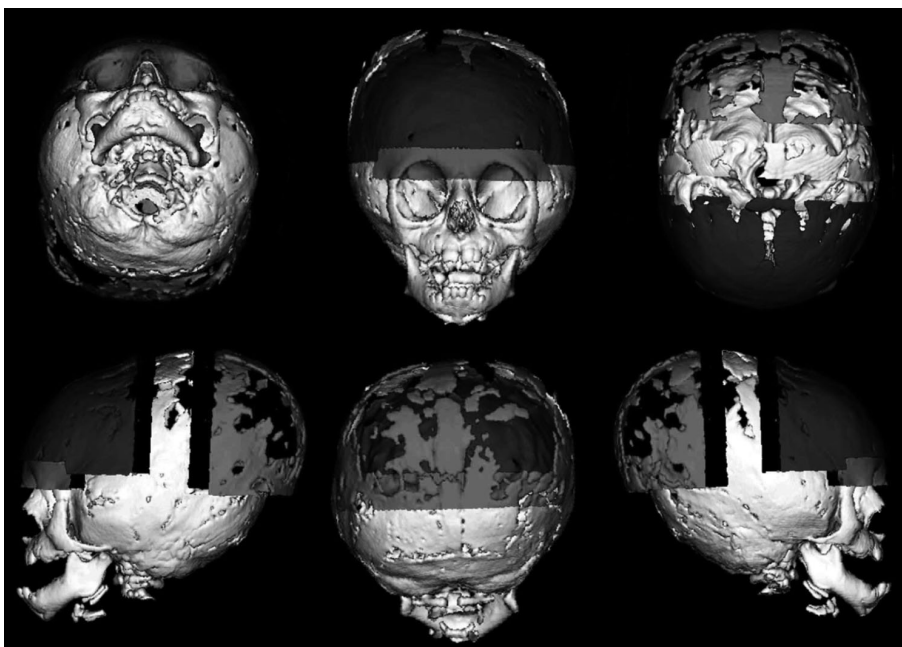


Fig. 6. 2nd surgical plan of simulation for the Fig. 4 Crouzon's syndrome patient.

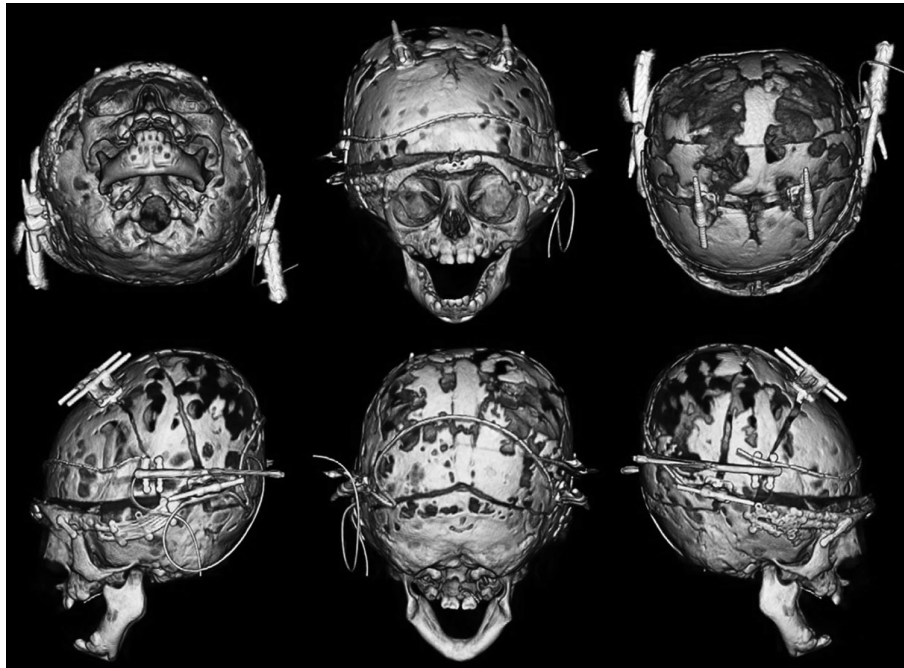


Fig. 7. Immediate post-operative 3D CT scan of the case of Crouzon syndrome after following the 2nd plan of simulation surgery.

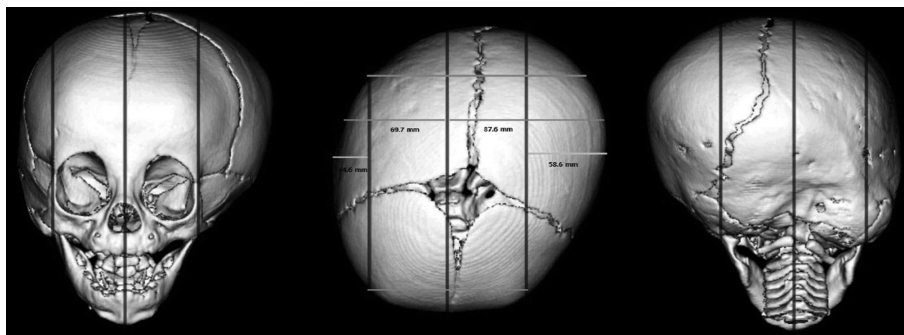


Fig. 8. Anterior, Top and posterior view of skull of 11 months old patient with unilambdoid synostoses demonstrating the mid line and two lateral lines extended parallel to the mid line and just lateral to the lateral orbital wall.

tion plan ,however the vectors were shown some differences.

Another important data that the simulation planning can provide the lateral distances from the mid line in severe plagiocephalic deformity, for the determination of the discrepancy between both sides.

Discussion

Craniosynostosis is defined as premature closure of the sutures of the skull, resulting in cranial deformity. In 1852, Virchow postulated that premature closure of a cranial suture decreased growth perpendicular to the suture and resulted in an increase in skull growth in the direction of the suture (12). Since then, we have learned much about premature suture clo-

sure, but there is still much that is unclear.

Craniosynostosis represents a great challenge for all craniofacial surgeons. The unique individual presentation makes every patient's plans of the management difficult even in the same type of synostosis.

Different surgical techniques had been described for surgical correction of craniosynostosis ranging from the simpler strip craniotomy; "sutusrectomy" (4, 8) to more extensive total cranial vault remodeling (9, 11).

The development of new software that are capable of doing the virtual cutting and shifting of bone parts nowadays allows a patient-specific simulation of complex bone movements either during distraction osteogenesis or even during vault remodeling, and anticipating the prior to real surgery (7, 11).

The advantage of a preoperative simulation planning for

craniosynostosis patients is especially apparent in cases where a comparison can be made during surgery, and this is much more apparent in plagiocephalic deformity (5).

The simulation of the surgical outcome, i.e. the three-dimensional graphic representation of the various osteotomies on the computer, can support the surgeon intra-operatively. The preoperative 3D-visualization of the skull on the computer facilitates the assessment of the outcome of surgery and permits discussions with colleagues about the benefits as well as the expected morbidities for each management plans, separately. It will support the surgeon to finalize the choice of operation plan that is optimal for each individual patient.

Despite the reliability of those plans, the main drawback of simulation planning is that those softwares does not consider soft tissue resistance during the real process of distraction osteogenesis, since both the soft tissues as well as the bone resist distraction. However, it is difficult to estimate both factors by the current technology. Another important factor is that the vector of distraction can be different from simulation in the real distraction process.

Automated operation planning as well as the simulation process, both can impact the real surgical results, and the realization of these technology will be come true in the near future. The goal of simulation surgery is to make the best result in real surgery, with involving the short operation, and less surgical morbidity. However, many trials and technologies are under development and expected that will be come true in near future.

Conclusion

Preoperative stimulation planning for craniosynostosis patient is very valuable tool in the surgical management of craniosynostosis patients.

Acknowledgements

Financial Disclosure and Products
Products that have been used in this article

- 1-Analyze AVW™,(Mayo clinic, Minnesota ,USA)
- 2-Siemens CT scanner (Siemens Medical Solutions, Erlangen, Germany).

Disclosure:

1. None of the authors have any conflicts of interest or financial interest in any of the products that had been used or mentioned in this article.
2. The 1st author is belonging to plastic and reconstructive surgery department, Cairo University, Cairo, Egypt, during preparation of this study.

References

1. Altobelli DE, K. R. M. J. e. a., 1993. Computer-assisted three-dimensional planning in craniofacial surgery.. *Plast Reconstr Surg*, Volume 92, p. 576-585.
2. Cutting C, B. F. G. B. e. a., 1986. Three dimensional computer-assisted design of craniofacial surgical procedures:optimization and interaction with cephalometric and CT-based models.. *Plast Reconstr Surg*, Volume 77, p. 877-887.
3. Englmeier KH, h. M. F. U. F. B., 1994. Image analysis and synthesis of multimodal images in medicine. *Comput Methods Programs Biomed*, Volume 43, p. 193-206.
4. Epstein N, E. F. N. G., 1982. Total vertex craniectomy for the treatment of scaphocephaly. *Childs Brain*, Volume 9, p. 309e16.
5. Girod S, K. E. G. B. e. a., 1995. Advances in interactive craniofacial surgery planning by 3D simulation and visualization.. *Int J Oral Maxillofac Surg*, Volume 24, p. 120-125.
6. Hill DL, H. D. G. M., 1994. Accurate frameless registration of MR and CT images of the head: applications in planning surgery and radiation therapy.. *Radiology*, Volume 191, p. 447-454.
7. Lambrecht JT, H. B. J. A. e. a., 1997. New trends in the 3D management of CT data in plastic and reconstructive surgery.. *Int Surg*, Volume 332-338, p. 82.
8. Lane LC, 1892. Pioneer craniectomy for relief of mental imbecility due to premature suture closure and microcephalus. *J Am Med Assoc*, Volume 18, p. 49e50.
9. Marsh JL, J. A. G. M. e. a., 1991. Surgical management of sagittal A quantitative evaluation of two techniques.. *Neurosurg Clin N Am*, Volume 2, p. 629e40.
10. Pelizzari CA, C. G. S. D. C. C., 1989. Accurate three-dimensional registration of CT, PET, and/or MR images of the brain.. *J Comput Assist Tomogr*, Volume 13, p. 20-26.
11. Posnick JC, L. K. C. P. e. a., 1993. Sagittal synostosis: quantitative assessment of presenting deformity and surgical results. *Plast Reconstr Surg*, Volume 92, p. 1015e24.
12. Virchow HR, 1852. Ueber den Cretinismus namentlich in Franken, und ueber pathologische Schaedelforamen.. *Verh Phys Med Ges Wuerzburg*, Volume 2, p. 230-271.