

Venous Anastomosis with Dorsal Veins Using Additional Incisions after Wound Closure in Metacarpophalangeal Joint Level Replantation

Sang Hyun Cho, Ahmed Suparno Bahar-Moni¹, Jong Ick Whang, Hyeung Gyo Seo, Hyun Sik Park, Ji Sup Kim, Hyun Chul Park*

Institute of Micro and Hand Surgery, Duson Hospital, Ansan, Korea,

¹*Department of Orthopedic Surgery, BIRDEM General Hospital, Dhaka, Bangladesh*

Received April 24, 2016

Revised May 1, 2016

Accepted May 2, 2016

*Correspondence to: Hyun Chul Park
Institute of Micro and Hand Surgery,
Duson Hospital, 114 Seonbugwangjang
1-ro, Danwon-gu, Ansan 15368, Korea
Tel: +82-31-402-0114
Fax: +82-31-414-1903
E-mail: haddal12345@naver.com

Financial support: None.
Conflict of interest: None.

In cases of replantation, accurate closure of all structures, including bone, tendons, arteries, nerves, and veins is essential. Among these, the vein is a weaker structure and is damaged severely in most amputation cases. After fixation of bone, repair of tendons, nerves, and arteries, surgeons often experience difficulty in performing venous anastomoses. We found that in such cases, venous anastomosis is easy to perform using an additional incision after closure of the original wound. In a 33-year-old male patient with amputation of all four fingers at the metacarpophalangeal joint level, venous anastomoses were performed with dorsal veins using additional incisions after completion of the fixation of bones and repair of all other structures and closure of the skin due to surgical site tension.

Key Words: Metacarpophalangeal joint, Amputation, Vein

The metacarpophalangeal joints (MCPJ) refer to the joints between the metacarpals and the proximal phalanges of the digits whose dorsal portion is composed of dorsal expansion of extensor tendons, skin and dorsal veins.¹ In case of digital replantation, typical sequences of repair are fixation of bone, repair of tendons, arterial anastomosis, nerve repair and venous anastomosis followed by skin closure.² In a 33-year-old male patient with all four fingers MCPJ level amputation, replantation was attempted accordingly. But while we tried to perform venous anastomosis, due to surgical site tension from crushing injury, it was impossible to perform adequate anastomosis without tension. So venous anastomoses were conducted through addition incisions on the dorsum of the hand with dorsal metacarpal and digital veins, after closure of the original wound and gained a relatively satisfactory result.

CASE REPORT

A 33-year-old male patient attended emergency department with complete amputation of all four fingers of left hand at MCPJ level following a work place injury (Fig. 1). There were no specific findings in respect to past medical history. He was thoroughly examined and on local examination it was found that there were complete amputations of all four fingers of the left hand with crushing injury mostly on dorsal side. On radiographic examination, the proximal phalanx of index, ring and small fingers showed severe comminution and the long finger was amputated at MCPJ level. Replantation of the fingers were implemented starting with fixation of fractured bone using K-wires, and then did extensor and flexor tendons repair, arterial anastomoses, and nerve repair subsequently. After dorsal expansion of extensor tendons repair, we attempted to perform venous anastomoses. But it was impossible to do a

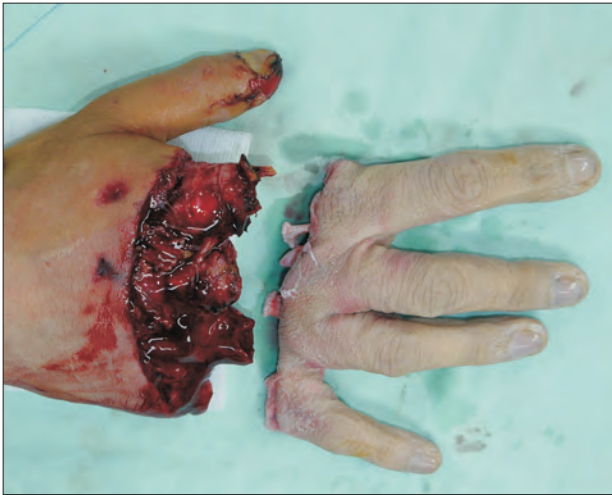

Fig. 1. A 33-year-old male with complete amputation of the all four fingers of left hand.

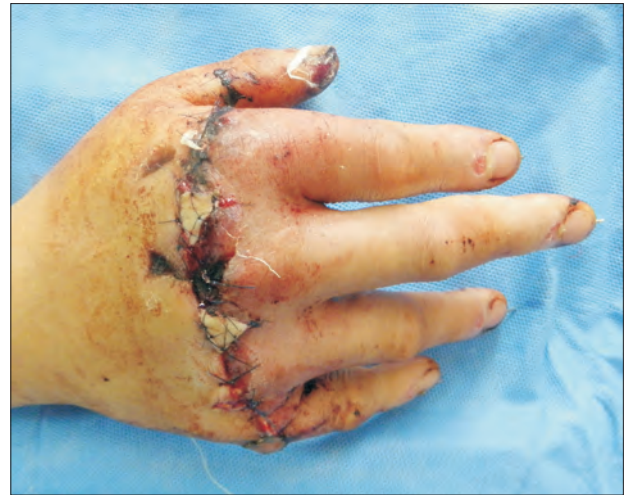

Fig. 3. At postoperative day 2, the full thickness skin graft was done on hand dorsum.

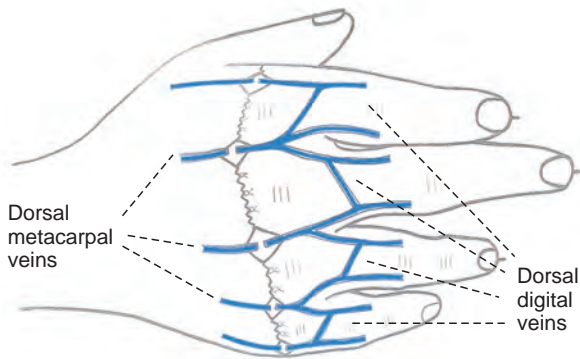


Fig. 2. Schematic view of the venous system of hand dorsum and full thickness skin grafting.

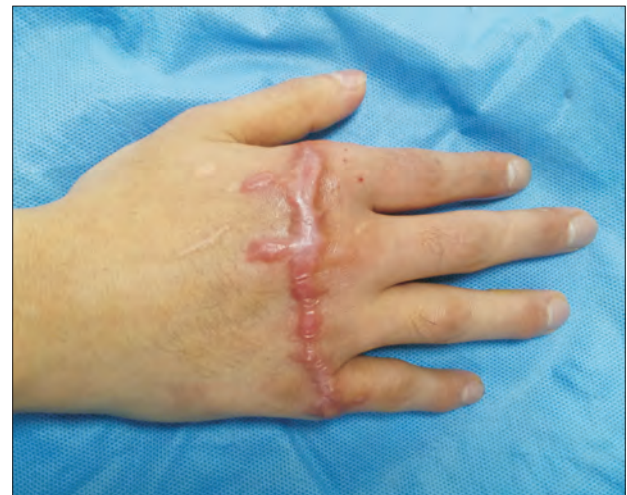

Fig. 4. Three months after replantation, the patient's hand shows complete viability.

tension free venous anastomoses. So we closed the wound first. After checking circulation of the hand, we made additional incisions on the web space where dorsal veins were expected to be present and performed the venous anastomoses using the dorsal metacarpal and digital veins. We mobilized the veins proximally before anastomoses to relieve tension over repair site and conducted anastomoses of total five veins. After completion of venous anastomoses, we attempted to suture the skin over venous anastomoses site. But due to surgical site tension, which was producing compression over the anastomosed veins, full thickness skin graft were applied over the five venous anastomoses sites harvested from the ipsilateral forearm (Fig.

2, 3). We observed scar hypertrophy over the area of skin grafting, and applied pressure garments and scar massage and considered intralesional steroid injection. Intralesional excision will be performed, if the scar persisted even after one year. After three months of replantation, the patient was followed-up to check the functional outcome. At that time range of movement was 0° to 10° at proximal and distal interphalangeal joints and 15° to 40° at MCPJ. Physiotherapy and occupational therapy were continued to improve the range of movements of the joints. If it will not improve within one year we will consider tenolysis to improve the joints movement. So at three months, in respect of survivability and functional point of view, result of

the replantation of our case is quite satisfactory (Fig. 4).

DISCUSSION

Dorsal digital veins run along the side of the digits and meet with the cross-branches in oblique line and meet each other at the side of the digits forming three dorsal metacarpal veins and a dorsal venous network at the middle of the metacarpals.^{1,3} The radial side of dorsal venous network meets the dorsal digital veins of the thumb and the index finger, and heading to the cephalic vein whereas the ulnar side is connected to the ulnar dorsal digital veins of the little finger, heading towards the basilic vein. Routine running of vein presents a tendency to run through the side of MCPJ.⁴

In this case, due to significant surgical site tension venous anastomoses was difficult to perform. So we closed the initial wound without performing the venous anastomoses. Then through additional incisions on both sides of the MCPJ, which are the expected sites of the dorsal veins, tried to find out good caliber, comparatively less injured veins. Then after adequate proximal mobilization venous anastomoses were done with five dorsal veins among them three were metacarpal veins and two were digital veins.

The sequence of procedures of replantation may differ depending on the site or shape of amputation. Typical sequences of digital replantation are starting with confirmation of locations of blood vessels and nerves, followed by debridement. Thereafter, surgery proceeds as bone fixation, repair of extensor and flexion tendons. Subsequently, arterial anastomosis and nerve repair are to be conducted. Then lastly venous anastomoses was done followed by skin closure.^{2,5,6} In this case, due to surgical site tension from crushing injury venous anastomosis could not be done before skin closure. So venous anastomoses were conducted with dorsal veins through additional incisions over the web spaces after original wound closure and gained a relatively satisfactory result. It has been known that if there is tension at surgical site, usually it requires vein graft.^{7,8} When distal veins are not available distal arteries

are also anastomosed with the proximal veins. However, as this case had the issue of multiple veins anastomoses as all four fingers were amputated, we made some additional incisions over expected sites of the metacarpal and digital veins, mobilized the veins adequately to gain enough lengths to minimize anastomoses sites tension and then performed the anastomoses. And we got satisfactory results in terms of outcome.

So it can be considered that venous anastomosis with the dorsal veins through additional skin incisions over expected sites of them, after performing original wound closure, can reduce the anastomosis site tension and can be a good option in cases where due to surgical site tension, venous anastomosis is difficult to perform, in MCPJ level digital replantation.

REFERENCES

1. Gray H. The veins. In: Clemente CD, editor. Gray's anatomy. 30th ed. Philadelphia: Lea & Febiger; 1985. p. 788-865.
2. Goldner RD, Urbaniak JR. Replantation. In: Green DP, Hotchkiss RN, Pederson WC, Wolfe SW, editors. Green's operative hand surgery. 5th ed. Philadelphia: Elsevier Churchill Livingstone; 2005. p. 1569-86.
3. Lee BI, Chung HY, Kim WK, Kim SW, Dhong ES. The effects of the number and ratio of repaired arteries and veins on the survival rate in digital replantation. *Ann Plast Surg* 2000;44:288-94.
4. Matsuda M, Chikamatsu E, Shimizu Y. Correlation between number of anastomosed vessels and survival rate in finger replantation. *J Reconstr Microsurg* 1993;9:1-4.
5. Urbaniak JR, Hayes MG, Bright DS. Management of bone in digital replantation: free vascularized and composite bone grafts. *Clin Orthop Relat Res* 1978;(133):184-94.
6. Whitney TM, Lineaweaver WC, Buncke HJ, Nugent K. Clinical results of bony fixation methods in digital replantation. *J Hand Surg Am* 1990;15:328-34.
7. Suzuki Y, Ishikawa K, Isshiki N, Takami S. Fingertip replantation with an efferent A-V anastomosis for venous drainage: clinical reports. *Br J Plast Surg* 1993;46:187-91.
8. Lima JQ Jr, Carli AD, Nakamoto HA, Bersani G, Crepaldi BE, de Rezende MR. Prognostic factors on survival rate of fingers replantation. *Acta Ortop Bras* 2015;23:16-8.