

Management of Premature Loss of Primary Molars with Flexible Denture

Kiun Song¹, Okhyung Nam², Misun Kim², Hyoseol Lee², Sungchul Choi²

¹*Department of Pediatric Dentistry, Graduate School, Kyung Hee University*

²*Department of Pediatric Dentistry, School of Dentistry, Kyung Hee University*

Abstract

Early loss of a primary second molar can cause mesial drift or tilting of the permanent first molar. We present a case of the early loss of the mandibular primary molars in a 5-year-old girl. The patient required extraction of the mandibular left primary first and second molars due to folliculitis on the successors. A flexible denture was used for eruption guidance of the permanent first molar and the recovery of masticatory function simultaneously.

Key words : Flexible denture, Space maintenance, Distal shoe

I . Introduction

Primary teeth play a crucial role in the growth and development of children¹⁾. Loss of the primary dentition may have physiological and psychosocial effects on a growing child. Dental caries is the main cause of primary tooth loss, followed by a traumatic dental injury or abscess¹⁾. Early loss of a primary second molar can affect arch length by allowing mesial drift or tilting of the permanent first molar, overbite, or altered eruption^{2,3)}. Therefore, the preservation of space for permanent tooth eruption should be emphasized.

A distal shoe can be used in these circumstances⁴⁾. However, a distal shoe appliance has certain disadvantages because it requires an invasive approach and use of the primary first molar as an abutment. Some alterations are needed in the case of patients with a hematologic disorder or with the loss of multiple primary

molars^{4,5)}.

Multiple loss of teeth can affect a child's growth and development in terms of esthetic problems as well as functional impairments in masticatory function, maxilla or mandibular growth, and the vertical dimension of the jaw⁶⁻⁸⁾. In these circumstances, a removable prosthodontic appliance may be recommended because the child is experiencing continuing growth of the jaws and dynamic changes in dentition. A removable appliance can maintain arch space, prevent speech impairment, and prevent masticatory dysfunction⁹⁾.

We present the case of a 5-year-old girl who was treated conservatively using a flexible denture to guide the eruption of a permanent first molar after the early loss of multiple primary molars. The flexible denture fulfilled the goal of space maintenance and avoided some of the disadvantages of a distal shoe appliance.

Corresponding author : Sungchul Choi

Department of Pediatric Dentistry, School of Dentistry, Kyung Hee University, 26, Kyungheedaero, Dongdaemun-gu, Seoul, 02447, Korea

Tel: +82-2-958-9371 / Fax: +82-2-965-7247 / E-mail: pedochoi@gmail.com

Received April 13, 2015 / Revised June 23, 2015 / Accepted June 19, 2015

II. Case report

A 5-year-old girl visited the Department of Pediatric Dentistry at the Kyung Hee University Dental hospital for the treatment of dental caries. And there was no special medical or familial history.

Clinical and radiographic examinations revealed multiple dental caries and periapical abscesses in the entire dentition. In particular, folliculitis was observed on the permanent maxillary right and left first premolars and on the permanent mandibular left first and second premolars as the cortical boundary of tooth follicles was thin or missing. And the border of the lesion was ill defined (Fig. 1). Fistula formation was observed on buccal mucosa around the mandibular left primary molars. And the patient mentioned spontaneous pain on mandibular left molar area.

It was necessary to extract the maxillary right and left primary first molars and mandibular left primary molars. And a flexible denture was considered to recover masticatory function and guide the proper path of the adjacent permanent molar for space preservation.

After the extraction of the mandibular left primary molars, another planned treatment was performed while waiting for adequate gingival healing. Impressions were taken with irreversible hydrocolloid material, and working casts were obtained. A flexible denture was fabricated on the casts in a laboratory.

After delivery of the denture, the patient and her parents were informed that the denture could cause temporary gingival irritation (Fig. 2). One week later, the patient did not complain of any discomfort, and there was no change in her facial profile. Three months later, the patient continued to be asymptomatic while using the denture, and the spontaneous eruption of the permanent mandibular first molar continued to be guided by the distal margin of the flexible denture.

Six months later, both permanent mandibular first molars were fully erupted (Fig. 3, Fig. 4). The denture fitted poorly after physiologic exfoliation of the mandibular primary incisors. Thus, a lingual arch with artificial teeth was used to recover masticatory function and preserve space for the successors (Fig. 5).

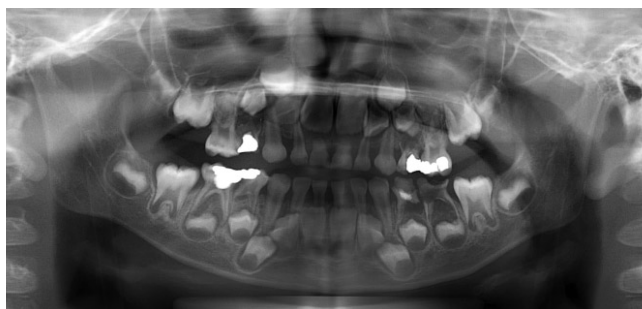

Fig. 1. Initial panoramic radiograph. Radiographic examination revealed dental caries, periapical abscesses, and folliculitis. Dental caries were on the maxillary right primary first and second molar, maxillary left primary first molar, mandibular right and left primary first and second molars. And folliculitis was observed on the permanent maxillary right and left first premolars and on the permanent mandibular left first and second premolars.

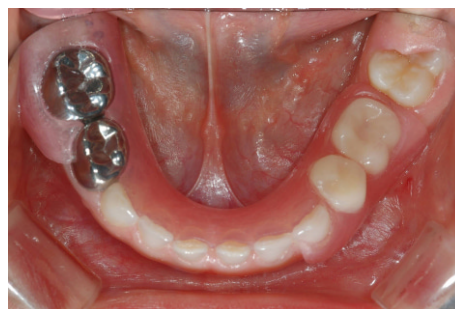

Fig. 2. Intraoral photograph after insertion of a flexible denture.

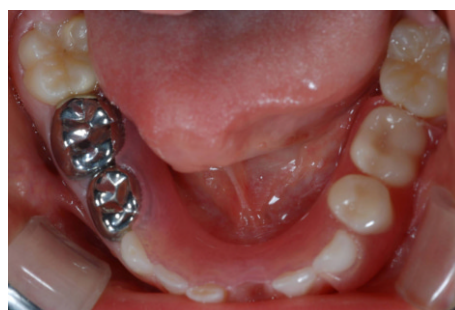

Fig. 3. Periodic intraoral photograph 6 months after insertion of the denture.

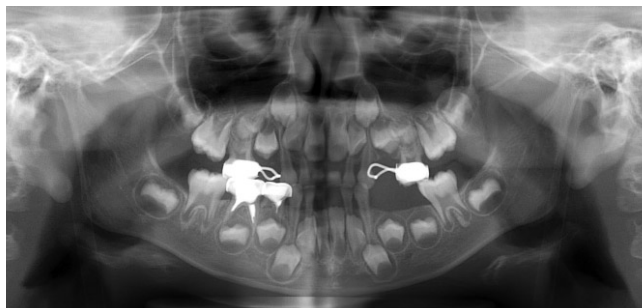


Fig. 4. Panoramic radiograph 6 months after insertion of the denture. Note that the both mandibular permanent first molars were fully erupted at the proper position.

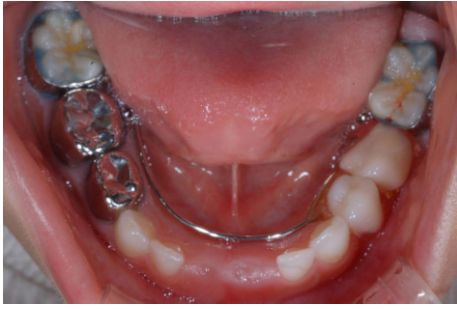

Fig. 5. Intraoral photograph after insertion of a lingual arch with artificial teeth.

III. Discussion

Traditional removable appliances using acrylic resin and wire extensions have some disadvantages. First, metallic appearance of the clasp may be unacceptable for esthetic reasons. Second, they are irritating to gingival tissue, resulting in denture-induced trauma. Further, acrylic resin is vulnerable to fracture.

A flexible denture made from a biocompatible thermoplastic resin can be designed without a metal clasp. It is semitransparent pink, and blends easily with the gingival tissue, giving it desirable esthetic properties¹⁰. Its excellent elasticity can be used in abutting teeth with large undercuts. It is also lighter in weight than acrylic resin dentures, enhancing a child's comfort¹¹⁻¹³. However, the deformation of a flexible denture can induce residual ridge resorption, gingival recession, or a change in occlusal position¹⁰. Therefore, flexible dentures are suitable only for short-term applications¹³. In the present case, several months of temporary application were planned, so the shortcomings were not a cause for concern.

Premature loss of primary molars without proper intervention results in space loss for successors. It has been reported that following extraction of the primary first molar, there is a space loss of 1.5 mm in the mandible and 1 mm in the maxilla¹⁴. Several reports have shown that the space lost is greater for the loss of a primary second molar compared to the loss of a primary first molar¹⁵. Without intervention, loss of space is inevitable in cases of premature primary molar loss.

Different treatment modalities for the early loss of primary molars have been reported, including space maintenance using a distal shoe or a pressure appliance, and

space regaining after eruption of the permanent first molar^{4,16}.

A distal shoe appliance consists of a guide plane soldered onto a band or crown on the primary first molar⁴. To guide the path of permanent molar eruption, the guide plane should extend under the gingival tissue. However, a distal shoe is technically difficult to install and requires excellent oral hygiene, surgical incision, and replacement after eruption of the permanent first molar⁴. A distal shoe could not be used in this case because of the loss of multiple mandibular primary molars as absence of primary first molar as an abutment for a distal shoe. Also clinically the mesial surface of permanent mandibular left first molar would be shown soon after extraction of primary tooth. Thus, a flexible denture was used to recover masticatory function and guide the proper path of the adjacent permanent molar. A flexible denture may also be used as a space maintainer before eruption of the permanent first molar without surgical intervention.

The distal margin of the denture acts as the guide plane just as a distal shoe would. With this guidance, the permanent mandibular first molar can erupt with minimizing the mesial drift. This technique may reduce the treatment duration than space regaining after permanent first molar eruption. Masticatory function can be recovered effectively using artificial acrylic resin teeth, and extrusion of the maxillary primary molar can be avoided.

There are some limitations of using a flexible denture. The effectiveness of the treatment as a space maintainer relies mainly on a patient's cooperation; thus, instructions or guidance for parents may be necessary. The patient was instructed to use her denture all day long, but she did not follow the instruction. As a result, some amount of mesial drift was observed. So the distal border of the denture was trimmed.

In the present case, the flexible denture served as a space maintainer and removable partial denture.

IV. Summary

Premature loss of both the mandibular primary first and second molars can be treated successfully using a flexible denture with recovery of masticatory function. And a flexible denture could minimize the mesial drift of permanent mandibular first molar without subgingival complications and space regaining.

References

1. Ngan P, Alkire RG, Fields H Jr : Management of space problems in the primary and mixed dentition. *J Am Dent Assoc*, 130:1330-1339, 1999.
2. Rock WP, British Society of Paediatric Dentistry : UK national clinical guidelines in paediatric dentistry. Extraction of primary teeth-balance and compensation. *Int J Paediatr Dent*, 12:151-153, 2002.
3. Alamoudi N : The prevalence of crowding, attrition, midline, discrepancies, and premature tooth loss in the primary dentition of children in Jeddah, Saudi Arabia. *J Clin Pediatr Dent*, 24:53-58, 1999
4. Laing E, Ashley P, Naini FB, Gill DS : Space maintenance. *Int J Paediatr Dent*, 19:155-162, 2009.
5. Bhat PK, K NH, Rai N, *et al.* : Modified distal shoe appliance for premature loss of multiple deciduous molars: a case report. *J Clin Diagn Res*, 8:43-45, 2014.
6. Yenisey M, Guler A, Unal U : Orthodontic and prosthodontic treatment of ectodermal dysplasia: a case report. *Br Dent J*, 196:677, 2004.
7. Silva MR : Radiographic assessment of congenitally missing teeth in orthodontic patients. *Int J Paediatr Dent*, 13:112-116, 2003.
8. Padma KB, Retnakumari N : Loss of space and changes in the dental arch after premature loss of the lower primary molar: A longitudinal study. *J Indian Soc Pedod Prev Dent*, 24:90-96, 2006.
9. American Academy of Pediatric Dentistry, Clinical Affairs Committee-Restorative Dentistry Subcommittee: Clinical guideline on pediatric restorative dentistry. *Pediatr Dent*, 26:106-114, 2004.
10. Fueki K, Ohkubo C, Yatani H, *et al.* : Clinical application of removable partial dentures using thermoplastic resin. Part II: Material properties and clinical features of non-metal clasp dentures. *J Prosthodont Res*, 58:71-84, 2014.
11. Chung YS, Lee NY, Lee SH : Removable flexible denture for child with loss of multiple teeth: A case report. *J Korean Acad Pediatr Dent*, 34:513-518, 2007.
12. Kim JY, Lee KH, Kim YH : Removable flexible denture for children with oligodontia: A case report. *J Korean Acad Pediatr Dent*, 36:150-156, 2009.
13. Schwass DR, Lyons KM, Purton DG : How long will it last? The expected longevity of prosthodontic and restorative treatment. *N Z Dent J*, 109:98-105, 2013.
14. Tunison W, Flores-Mir C, El-Bialy T, *et al.* : Dental arch space changes following premature loss of primary first molars: a systematic review. *Pediatr Dent*, 30:297-302, 2008.
15. Lin YT, Chang LC : Space changes after premature loss of the mandibular primary first molar: A longitudinal study. *J Clin Pediatr Dent*, 22:311-316, 1998.
16. Barbería E, Lucavechi T, Cárdenas D, Maroto M: Free-end space maintainers: design, utilization and advantages. *J Clin Pediatr Dent*, 31:5-8, 2006.

국문초록

탄성의치를 이용한 유구치 조기 상실의 치료

송기연¹ · 남옥형² · 김미선² · 이효설² · 최성철²

¹경희대학교 대학원 치의학과 소아치과학전공

²경희대학교 치의학전문대학원 소아치과학교실

제2유구치의 조기상실은 제1대구치의 근심이동이나 근심경사를 야기할 수 있다. 5세 여아에서 다수의 하악 유구치 조기상실 증례를 보고하는 바이다. 환아는 계승 영구치의 소포염으로 인해 하악 좌측 제1유구치와 제2유구치의 발거가 필요하였다. 탄성의치를 이용하여 저작 기능을 회복하는 동시에 제1대구치의 맹출을 유도하였다.

주요어: 탄성의치, 공간유지장치, distal shoe