

## Cytomegalovirus Myocarditis Required Extracorporeal Membrane Oxygenation Support Followed by Ganciclovir Treatment in Infant

Bong Jun Kim, M.D.<sup>1</sup>, Jo Won Jung, M.D.<sup>2</sup>, Yu Rim Shin, M.D.<sup>1</sup>, Han Ki Park, M.D.<sup>1</sup>,  
Young Hwan Park, M.D.<sup>1</sup>, Hong Ju Shin, M.D.<sup>1,3</sup>

A 7-month-old girl with no medical history was treated with mechanical circulatory support due to myocarditis. Her cardiac contractility did not improve despite more than one week of extracorporeal membrane oxygenation treatment. Thus, we planned a heart transplant. However, a high level of cytomegalovirus was found in blood laboratory results by quantitative polymerase chain reaction. The patient's heart contractility recovered to normal range four days after ganciclovir treatment. She was discharged with slightly decreased cardiac contractility with a left ventricular ejection fraction of 45%.

Key words: 1. Myocarditis  
2. Extracorporeal membrane oxygenation  
3. Extracorporeal circulation  
4. Infant

### CASE REPORT

A 7-month-old girl was referred to Severance Cardiovascular Hospital for suspected myocarditis. Her medical and familial history was unremarkable. However, fever and lethargic symptoms had developed five days before presentation. Her body weight was 7.6 kg. A chest X-ray showed cardiomegaly with a cardiothoracic ratio of 0.67 (Fig. 1) and electrocardiography revealed normal sinus rhythm with a heart rate of 158/min. Echocardiogram revealed decreased left ventricular (LV) ejection fraction (LVEF) of 10% and an enlarged left ventricle. An initial laboratory test revealed elevated levels of cardiac enzymes (creatine kinase-myocardial

band 10.4 ng/mL, troponin-T 0.289 ng/mL). Intravenous use of inotropics, including dopamine, milrinone, and epinephrine, were infused. However, metabolic acidosis developed and a follow-up echocardiogram showed additionally decreased LVEF of 3% to 5%. Therefore, we decided to apply extracorporeal membrane oxygenation (ECMO) support. Arterial cannulation was performed via the right carotid artery with a 10 French percutaneous arterial cannula (RMI; Edwards Lifesciences, Irvine, CA, USA) and a 14 French percutaneous venous cannula (RMI, Edwards Lifesciences) was placed in the right internal jugular vein (Fig. 2). Capiiox EBS-PMP (Terumo Ltd., Tokyo, Japan) was used to support circulatory function. ECMO flow was maintained between 700 and 800

<sup>1</sup>Division of Cardiovascular Surgery, Department of Thoracic and Cardiovascular Surgery and <sup>2</sup>Division of Pediatric Cardiology, Congenital Heart Disease Center, Severance Cardiovascular Hospital, Yonsei University College of Medicine, <sup>3</sup>Department of Thoracic and Cardiovascular Surgery, Chungbuk National University Hospital, Chungbuk National University College of Medicine

Received: July 28, 2015, Revised: November 1, 2015, Accepted: November 3, 2015, Published online: June 5, 2016

Corresponding author: Hong Ju Shin, Department of Thoracic and Cardiovascular Surgery, Chungbuk National University Hospital, Chungbuk National University College of Medicine, 776 1(il)sunhwan-ro, Heungdeok-gu, Cheongju 28644, Korea  
(Tel) 82-43-269-8440 (Fax) 82-43-269-6069 (E-mail) [babymedi@naver.com](mailto:babymedi@naver.com)

© The Korean Society for Thoracic and Cardiovascular Surgery. 2016. All right reserved.

© This is an open access article distributed under the terms of the Creative Commons Attribution Non-Commercial License (<http://creativecommons.org/licenses/by-nc/4.0>) which permits unrestricted non-commercial use, distribution, and reproduction in any medium, provided the original work is properly cited.

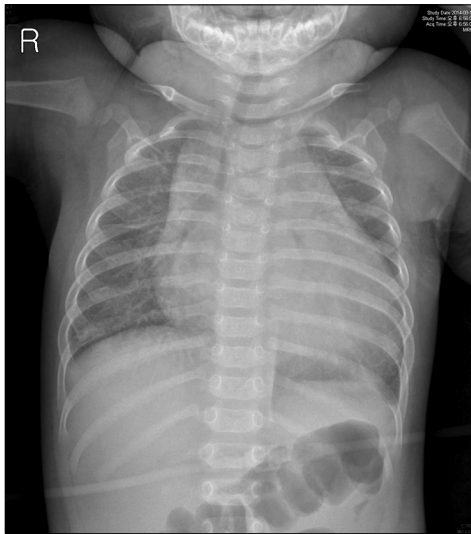


Fig. 1. Chest X-ray showed cardiomegaly.

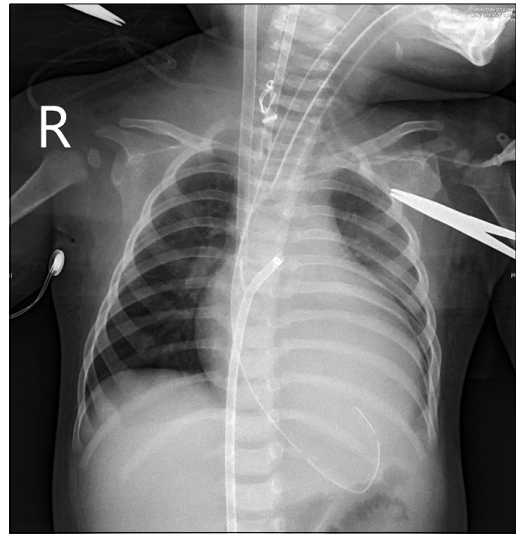


Fig. 3. Chest X-ray showed left atrial venting cannula insertion through right femoral vein.

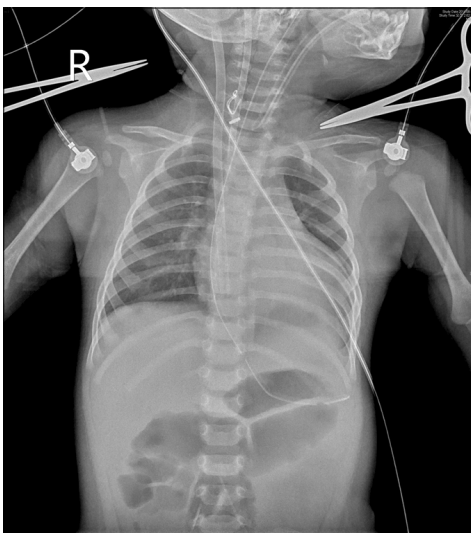


Fig. 2. Chest X-ray showed extracorporeal membrane oxygenation support via right neck vessel.

mL/min. The metabolic acidosis improved rapidly after ECMO; however, the sputum took on a pinkish and watery character the next day. Severe left atrial (LA) enlargement was observed in the echocardiogram; thus emergent atrial septostomy with a 8.5 Fr LA venting cannula (Mullins sheath; Cook Inc., Somerset, NJ, USA) insertion through the right femoral vein was performed percutaneously (Fig. 3). Decreased LA enlargement and LV size were observed on echocardiography with intact septostomy flow. Inotropic sup-

port was kept to maintain cardiac contraction and intravenous immunoglobulin (2 g/kg) was also infused as immunomodulatory therapy. Three days after ECMO insertion, however, LV contraction was not recovered with LVEF of 15%. Unlike the myocarditis course in other cases, recovery was slow despite more than one week of mechanical circulatory support. Because there was no improvement of LVEF despite a long period of mechanical circulatory support, heart transplantation was considered for a possible dilated cardiomyopathy. Microbiological results were reported, but common causes of myocarditis such as coxsackie B, adenovirus, and parvovirus were negative. Instead, high level of cytomegalovirus (CMV) via quantitative polymerase chain reaction (PCR) was reported in the blood (720 copies/mL, normal range <250 copies/mL). CMV antibody immunoglobulin G (IgG) titer was positive (66 AU/mL, normal range <4 AU/mL); however, CMV immunoglobulin M titer was equivocal (0.89 AU/mL, normal range <0.7 AU/mL). Preoperative examination for transplantation that included evaluation for congenital immunodeficiency and viral antibody was not remarkable. During the mechanical circulatory support of almost two weeks, there was little improvement of heart contractility. Because of deteriorating oxygenator function and worsening hyperbilirubinemia, we decide to stop ECMO with maximal inotropic support. The duration of ECMO support was 324

hours. During follow-up of whole blood laboratory results, CMV titer revealed a higher level than in a previous result (6,250 copies/mL). Because the CMV titer increased nine times within two weeks and there was no evidence of other disease, we decided to start intravenous ganciclovir at 2.5 mg/kg twice a day. Two days after ganciclovir treatment, LVEF improved to 35%. Heart contractility recovered to normal range four days after. Thus, we continued to use ganciclovir treatments for two weeks in total. After two weeks of treatment, CMV PCR titer decreased to normal range and LVEF recovered to 46%. However, one week after ganciclovir stopped, follow-up CMV PCR titer in the urine was still high (> 1,150 copies/mL), so another two weeks of ganciclovir treatment was applied and CMV PCR titer returned to normal. Even though the hospital course of the patient was continued over three months due to renal failure and ventilator-associated pneumonia, a low CMV titer and recovered heart function remained until discharge. The duration of hospital stay was 109 days. Follow-up echocardiography 14 months later showed recovered cardiac contractility with LVEF of 64% and decreased heart size in chest radiography.

## DISCUSSION

Myocarditis is defined as an inflammation of the heart muscle, and it can lead to myocardial dysfunction. Viral infections such as coxsackie B enterovirus, adenovirus, and parvovirus B19 are common causes of myocarditis. CMV infection is common among many people, regardless of age or race, but serious disease may occur in immunocompromised patients such as transplant recipients or congenitally infected newborns [1]. However, CMV myocarditis is rare even in immunocompromised patients [2,3], and there are just a few reports about CMV myocarditis in immunocompetent patients [1,4,5]. The patient had no remarkable illness before admission. Her physical and neurological development and the results of laboratory investigation for primary immunodeficiencies were normal. Symptomatic CMV infections rarely occur in immunocompetent patients like her. However, neglecting the potential of CMV myocarditis led to a misdiagnosis of dilated cardiomyopathy.

In this case, CMV myocarditis was proven by quantitative

PCR in blood and urine. CMV antibody IgG was also positive in this patient, but most of the general population in Korea has CMV antibody IgG. A positive result may reflect passive transmission of a maternal antibody [6]. The PCR results of other known causes of viral myocarditis were all negative and a bacterial culture study was also negative. Though we did not perform myocardium biopsy, the negative result from the other study was enough to diagnose CMV myocarditis. In contrast to other types of viral myocarditis, the use of an antiviral agent is a feasible treatment choice for CMV myocarditis.

If the opportunity to recover LVEF was lost due to a delay in ganciclovir treatment, the only treatment option for the patient would have been heart transplantation, and heart transplantation for this patient would have been an inappropriate treatment.

Mechanical circulatory support is necessary for both fulminant myocarditis and severe dilated cardiomyopathy [2]. Temporary mechanical circulatory support can buy time for myocardial recovery or bridge to transplantation [3]. In this case, initial cardiac function was impaired and insufficient for maintaining blood pressure; therefore, ECMO was applied. This enabled us to buy time for exact diagnosis and allowed for slight myocardial recovery.

Ganciclovir has a dramatic effect on CMV myocarditis [1,4,7]. Improvement of LVEF was achieved in two days, and it reached normal values within five days of therapy. Though there was no biopsy result, clinical and chronological links between administrations of ganciclovir and cardiac function recovery suggested the effectiveness of this medicine in CMV myocarditis. When we encounter patients with myocarditis, we should consider CMV as a possible cause, and tests for CMV infection should be performed. If the result suggests CMV myocarditis, an antiviral agent like ganciclovir should be tried for treatment of the underlying disease.

## CONFLICT OF INTEREST

No potential conflict of interest relevant to this article was reported.

## REFERENCES

1. Dehtiar N, Eherlichman M, Picard E, et al. *Cytomegalovirus myocarditis in a healthy infant: complete recovery after ganciclovir treatment*. *Pediatr Crit Care Med* 2001;2:271-3.
2. Sagar S, Liu PP, Cooper LT Jr. *Myocarditis*. *Lancet* 2012; 379:738-47.
3. Kindermann I, Barth C, Mahfoud F, et al. *Update on myocarditis*. *J Am Coll Cardiol* 2012;59:779-92.
4. Baumgratz JF, Vila JH, Silva JP, Fonseca Ld, Rodrigues EA, Knobel E. *Cardiogenic shock due to cytomegalovirus myocarditis: successful clinical treatment*. *Rev Bras Cir Cardiovasc* 2010;25:149-53.
5. Roubille C, Brunel AS, Gahide G, Vernhet Kovacsik H, Le Quellec A. *Cytomegalovirus (CMV) and acute myocarditis in an immunocompetent patient*. *Intern Med* 2010;49:131-3.
6. Sohn YM, Park KI, Lee C, Han DG, Lee WY. *Congenital cytomegalovirus infection in Korean population with very high prevalence of maternal immunity*. *J Korean Med Sci* 1992;7:47-51.
7. Stack WA, Mulcahy HE, Fenelon L, Hegarty JE. *Cytomegalovirus myocarditis following liver transplantation*. *Postgrad Med J* 1994;70:658-60.