

Forearm Replantation for a Patient Presented with Major Amputation Injury: A Case Report

Jihoon Jang, M.D., Kyoung Hoon Lim, M.D., Joon-Woo Kim, M.D.¹, Hyung-Kee Kim, M.D.

Department of Surgery, ¹Department of Orthopedic Surgery, Kyungpook National University Hospital, Daegu, Korea

With the development of safety measures for employees who work with dangerous machinery, the frequency of amputation injuries has been decreasing with resultant decrease in replantation procedures. However, in some patients with major amputation injury, replantation is still necessary for the preservation of limb and its function. The replantation of the upper extremity (UE) is a complex and technically demanding surgical procedure. For the successful replantation of UE, the type of injury, reconstruction sequence, ischemic time, and other combined injury of patient should be considered. We report a case of major amputation of UE by guillotine-type injury and discuss the treatment process of this patient. [J Trauma Inj 2016; 29: 187-190]

Key Words: Amputation, Replantation, Forearm

I. Introduction

Upper extremity (UE) amputation can cause significant morbidity and disability to an affected patient. In 1962, Malt and McKhann(1) reported the first successful limb replantation, performed on a patient with a complete amputation. Since then, successful replantation of digits, hands, feet, and limbs have been performed around the world. UE amputation injuries are divided into macro- and micro- injuries, depending on whether the amputated portion of the limb contains significant muscle bulk. Macroamputation of the UE is usually defined as an amputation injury at or proximal to the level of the wrist.(2) UE macroreplantation is a complex and technically demanding surgical procedure. Unlike digit replantation, ischemia of the main muscle mass of the amputated part can produce local and systemic complications, both during and after macroreplantation surgery. In order to

minimize ischemic time and to reduce bleeding risks, protocols for candidate selection and reconstruction sequence in patients with limb amputation injuries are important. We report a case of UE macroamputation by cutting injury and introduce the treatment process of our hospital.

II. Case Report

A 56-year-old female patient presented to the emergency department after amputation her left forearm with a cutting machine. When she arrived at the emergency department, a tourniquet has been applied to her left upper arm. There was no active bleeding on the cut surface. She stated that she was injured by the meat-cutting machine in a butcher's shop 30 minutes prior to consult and had no pertinent medical history. Her vital signs were stable. On physical examination, her left middle forearm was completely ampu-

* Address for Correspondence : **Hyung-Kee Kim, M.D.**

Department of Surgery, Kyungpook National University Hospital,
130 Dongdeok-ro, Jung-gu, Daegu 41944, Korea

Tel : 82-53-420-5605, Fax : 82-53-421-0510, E-mail : hkim6260@knu.ac.kr

Submitted : December 2, 2016 **Revised** : December 2, 2016 **Accepted** : December 30, 2016

tated, the cut surface of the amputated forearm was relatively clear, and structures could be identified. The laboratory findings were within normal range and the forearm plane film revealed wedge fractures of the proximal ulna and radius at the cut surface.

The ischemic time was relatively short, and the patient and family desired the replantation of amputated limb, therefore, we decided emergent replantation surgery. The interval between injury and operation was three hours. After her amputated forearm was draped, massive irrigation and debridement were done. Simultaneously, to reduce the warm ischemic time, the ulnar and radial arteries of her severed forearm were identified and flushed with cold heparinized Hartmann's solution until the venous return was clear (Fig. 1A). The reconstruction was done in the following sequence: bones, veins, arteries, nerves, and tendons. First, her proximal and distal parts of ulna and radius were exposed by dissecting the surrounding muscles and the fracture site at the proximal ulna was identified. Both proximal and distal bones were shortened by 2 cm for the purpose of easier approxima-

tion by end to end anastomosis for vessels and nerves, after which, internal fixation of both ulna and radius was carried out with plate fixation (Fig. 1B).

After bone fixation, vascular reconstructions were started. Vascular structures including the radial artery, ulnar artery, cephalic vein and basilic vein were identified and dissected for anastomosis. After dissection, the radial and ulnar artery was considered as possible for end to end anastomosis, however, the cephalic and basilic vein was not possible for end to end anastomosis due to significant loss of vein segment by injury. Therefore, we decided interposition graft with great saphenous vein for venous reconstruction. After harvest of her left great saphenous vein, venous reconstructions were performed first in order to reduce bleeding from cut surface of amputated part after arterial anastomosis. For the venous reconstruction, interpositions with harvested great saphenous vein were performed for cephalic vein and basilic vein. Next, end to end anastomosis of radial and ulnar artery was performed with tension-free manner achieved by bone shortening. All venous and

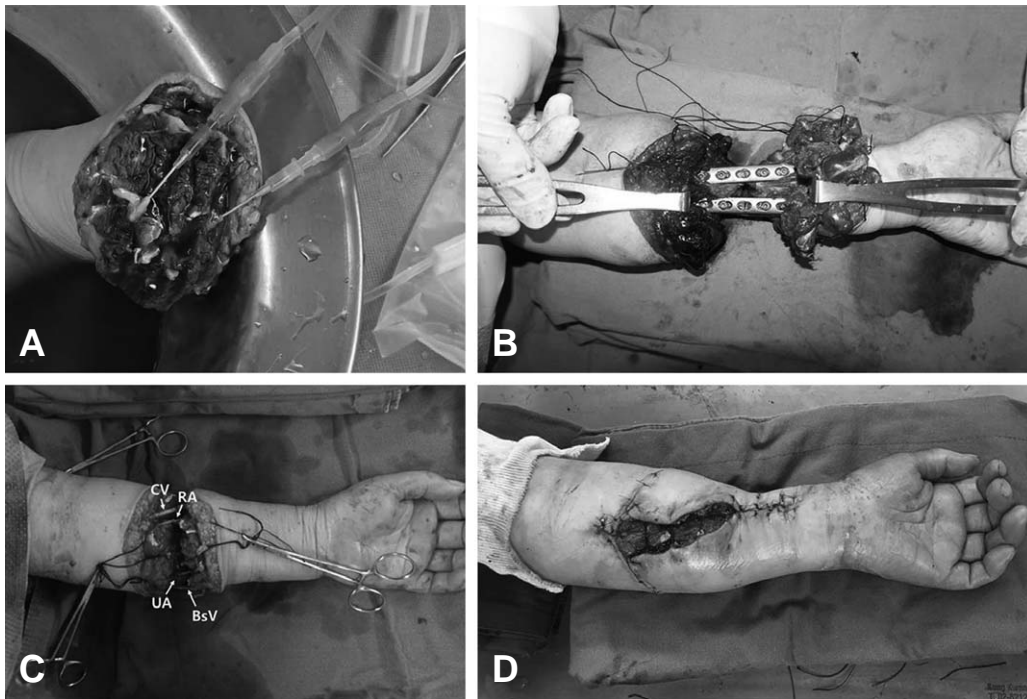


Fig. 1. (A) Flushing of severed forearm was performed through radial artery (RA), ulnar artery (UA) with cold heparinized Hartmann's solution; (B) The internal fixation of both ulna and radius was done by end to end with plate fixation; (C) Vascular reconstruction of RA and UA was performed by end to end anastomosis and vascular reconstruction of cephalic vein (CV) and basilic vein (BsV) was performed by interpositions with harvested greater saphenous vein; (D) The skin around cutting surface was closed with 4-0 nylon and the fasciotomy was done.

arterial reconstruction was performed with 7-0 non-absorbable monofilament surgical sutures (Fig. 1C). After the reconstructions of vessels were done, blood flows of each vessel were restored and pulsation of radial artery can be checked.

The ulnar nerve, median nerve, and radial nerve were reconstructed end to end using 8-0 & 9-0 non-absorbable monofilament surgical sutures. After the forearm muscles & tendons were reconstructed, the skin around the cut surface was closed with 4-0 nylon (Fig. 1D). To avoid compartment syndrome of the amputated forearm, fasciotomy was done. Total operation time was 630 minutes (warm ischemic time: 210 minutes, cold ischemic time: 390 minutes). The patient could be successfully discharged with salvaged limb on the postoperative day 40.

III. Discussion

In the early 1970s, it became clear that replantation surgery was destined to become an important addition to the armamentarium of reconstructive surgeons with the industrialization of nations. However, the frequency and nature of amputation injuries have changed; in industrialized countries, the number of UE replantation procedures has decreased.(3) This may be due to improvements in safety measures for employees who work with dangerous machinery.

The decision for primary amputation or replantation of macroamputation injury is a difficult matter. Currently, there is no absolute criterion to recommend either primary amputation or replantation after a severe UE traumatic injury. However, considerable factors for limb salvage differ significantly between the upper and lower extremities. One important consideration in UE injuries is the dramatic difference in the functional capability of a normal hand versus a prosthetic hand, despite modern advances in prosthetic design. Direct comparisons of limb function demonstrate that UE reconstructions are superior to prosthetics; interestingly, 30% of patients who receive UE prostheses eventually stop using them. In addition, anatomic and functional differences make the UE more amenable to limb salvage than the lower extremity (LE). Since the UE is not used for walking, there is less concern for limb-length equality; in

patients with unilateral UE amputation, decreased function can be overcome by the use of the contralateral limb.(4) Therefore, more aggressive approach for the salvage of amputated UE should be considered.

In general, the decision to perform replantation or primary amputation is determined by the features of the injury and by patient-specific factors. Injury factors include the level and mechanism of injury, the ischemic time, the wound condition, and whether or not there is bilateral involvement. Patient factors include age and medical history, associated injuries, the patient's occupation and hobbies, and the patient's preferred surgical repair. According to a previously published UE macroreplantation series, the limb salvage rate ranges from 57% to 95%; these results are from a group of patients with heterogeneous mechanisms and levels of UE injury.(2) Patients with extensive crush or avulsion injuries are typically poor candidates for replantation, whereas amputations resulting from guillotine-type injuries such as in our case are ideal for replantation because the extent of the injury is largely confined to the amputation site.(5)

Since a macroamputation injury involves muscle tissue, the ischemic time is particularly important. Traditionally, 6 hours of warm ischemia and up to 12 hours of cold ischemia have been used as cutoff points for limb replantation.(6) Muscle tissue has been known to begin to die after 4 hours of warm ischemia, with the extent of necrosis increasing exponentially as the ischemia time extends beyond 4 hours. Cold ischemia is better tolerated than warm ischemia; even low-grade hypothermia can make a significant difference in muscle viability. Leclere et al.(2) established the guidelines for the reconstruction sequence as follows: fixation of bone; repair of artery, vein, and nerve; and release of clamps. However, the sequence is different as in our complete amputated case. Our sequence for reconstruction can be enumerated as bone fixation, vein reconstruction, artery reconstruction, release of clamp, nerve repair, and muscle repair. The reason for this difference can be explained that the sequence of Leclere et al.(2) can prolong the cold ischemic time because reperfusion is carried out after time consuming nerve repair procedure. Therefore, we conducted vascular reconstruction and release of clamp prior to nerve repair for the reduction of cold

ischemic time. In addition, arterial reconstruction and reperfusion without venous reconstruction can induce troublesome bleeding and swelling of amputated part, therefore, we believe that venous reconstruction should be performed prior to arterial reconstruction after induction of cold ischemia. Nonetheless, surgical protocol for reconstruction in own hospital should be established and multidisciplinary approach is critical for successful replantation.

IV. Conclusion

More active approach should be considered in patient with guillotine-type UE amputation injury for limb salvage. The protocols for candidate selection and reconstruction sequence with multidisciplinary approach should be established for the successful replantation.

REFERENCES

- 1) Malt RA, McKhann C. Replantation of Seved Arms. *JAMA* 1964; 189: 716-22.
- 2) Leclere FM, Mathys L, Juon B, Franz T, Unglaub F, Vogelin E. Macroreplantations of the upper extremity: a series of 11 patients. *Arch Orthop Trauma Surg* 2012; 132: 1797-805.
- 3) Meyer VE. Upper extremity replantation: a review. *Eur Surg* 2003; 35: 167-73.
- 4) Kim HK, Cho J, Huh S, Oh CW, Chung HY, Roh YN, et al. Upper Extremity Replantation for Patients with Major Amputation Injury: Follow-up Results of 11 Patients. *Korean J Vasc Endovasc Surg* 2013; 20: 10-6.
- 5) Ipsen T, Lundkvist L, Barfred T, Pless J. Principles of evaluation and results in microsurgical treatment of major limb amputations. A follow-up study of 26 consecutive cases 1978-1987. *Scand J Plast Reconstr Surg Hand Surg* 1990; 24: 75-80.
- 6) Goldner RD, Nunley JA. Replantation proximal to the wrist. *Hand Clin* 1992; 8: 413-25.