

Intraoperative Diagnosis of a Pericardial Injury Associated with Multiple Diaphragmatic Ruptures in a Patient with Abdominal Blunt Trauma

Do Wan Kim, M.D., In Seok Jeong, M.D., Kook Joo Na, M.D.,
Sang Yun Song, M.D., Kyo Seon Lee, M.D., Seung Ku Kang, M.D.

Department of Thoracic and Cardiovascular Surgery, Chonnam National University Hospital, Gwangju, Korea

A diaphragmatic injury is uncommon, but occurs more frequently with injury to other organs. Particularly, a diaphragmatic accompanied by a pericardial injury is very rare. The authors report a case of incidentally detecting a pericardial injury during surgery for a diaphragmatic injury due to abdominal blunt trauma. [J Trauma Inj 2016; 29: 180-183]

Key Words: Wounds, Nonpenetrating, Diaphragm, Pericardium

I. Introduction

The diaphragm separates the thoracic and abdominal cavities and is the most important muscle involved in respiration. Diaphragmatic injury occurs in about 6% of all blunt trauma patients and is often accompanied by damage to other organs.(1,2) Among them, diaphragmatic injury accompanied by pericardial injury is often difficult to diagnose preoperatively.(3,4) The authors report a case of a pericardial injury incidentally found during surgery for a diaphragmatic injury.(3,4)

II. Case Report

A 79-year-old woman visited the emergency room after experiencing a blunt trauma injury from a car-to-car traffic accident. She was diagnosed with a liver injury and diaphragmatic rupture, at the first hospital visit without the opinion of a trauma sur-

geon, and was transferred to a level 1 trauma center for further evaluation and treatment. At the time of admission at the level 1 trauma center, her blood pressure was 110/70 mmHg, heart rate was 90 beats/min, and respiratory rate was 20 breaths/min. She was complaining of severe abdominal pain. A right eyebrow laceration and multiple body contusions mainly on the right side of the torso were also observed. Although the physical examination and a computed tomography (CT) scan had been at the first hospital, an additional examination was performed at the trauma center to evaluate the diaphragmatic rupture and other injuries (Fig. 1). A chest examination revealed decreasing breath sounds on the left side, as estimated by the focused Assessment with sonography for trauma criteria, but no fluid had collected in the chest or abdominal cavities. A facial CT scan revealed a fracture of the right inferior and medial orbital wall. The Injury Severity Score was 24 (according to the abbreviated injury

* Address for Correspondence : **Seung Ku Kang, M.D.**

Department of Thoracic and Cardiovascular Surgery, Chonnam National University Hospital,
42, Jebong-ro, Dong-gu, Gwangju 61469, Korea

Tel : 82-62-220-6546, Fax : 82-62-227-1636, E-mail : defron@hanmail.net

Submitted : November 22, 2016 **Revised** : December 1, 2016 **Accepted** : January 31, 2017

scale: chest, 4; abdomen, 2; face, 2). The patient was transferred to the operating room to correct the diaphragmatic injury.

The patient was placed in the right lateral decubitus position while under general anesthesia, and double-lumen intubation for single-lung ventilation was performed. Since the patient was elderly, we decided to attempt a minimally invasive therapeutic procedure. Diagnostic thoracoscopy revealed a large 15-cm diaphragmatic injury in which the stomach had

herniated into the thoracic cavity with the omentum. The procedure was converted to open surgery at the seventh intercostal space using a posterolateral thoracotomy. After the stomach was returned to the abdominal cavity, a pericardial rupture and a right ventricular surface injury were detected. Both the diaphragmatic and multiple injury pericardial sites were identified, and a pericardio-diaphragmatic injury was confirmed (Fig. 2).

The diaphragmatic injury was repaired using non-

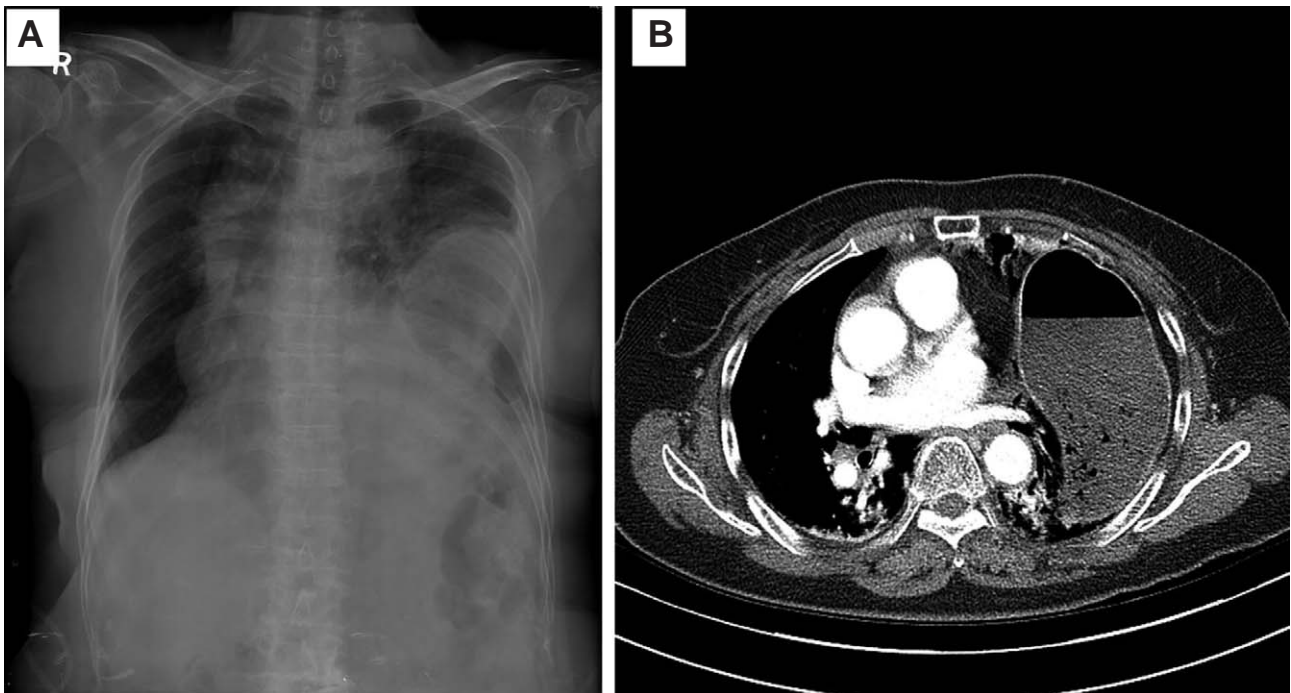


Fig. 1. Left diaphragm injury at admission. (A) Simple Chest PA (B) Chest Computed Tomography.

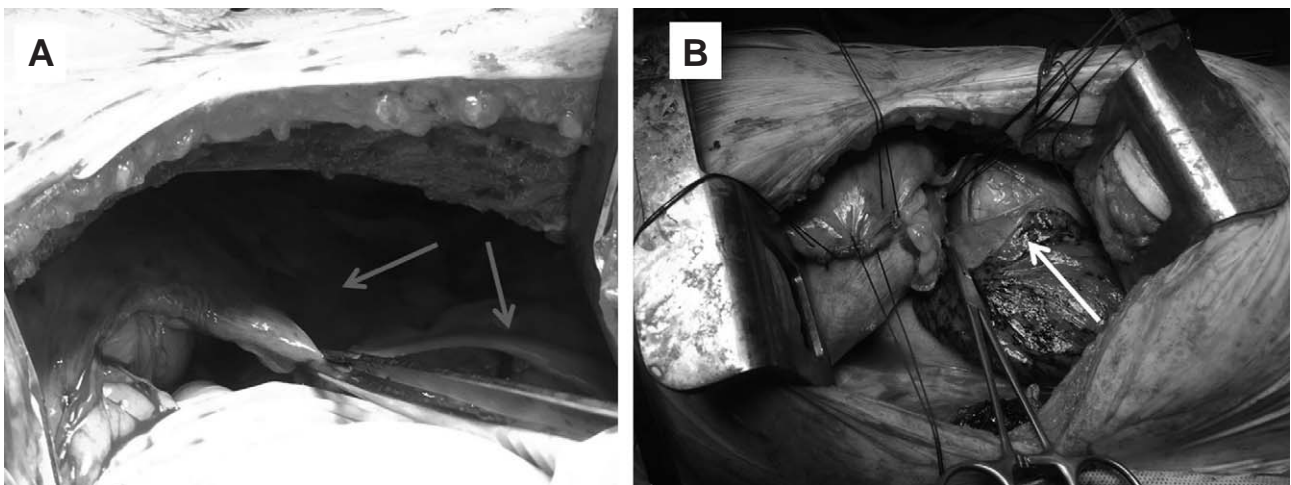


Fig. 2. An intraoperative image. (A) Red arrow demonstrating a rupture of the diaphragm: 15 cm in its longest dimension, with sharp lacerations in the margin. (B) White arrow demonstrating a rupture of the pericardium: with sharp lacerations in the margin.

absorbable heavy silk with full-thickness interrupted horizontal sutures, and the right ventricular injury was compressed to achieve local hemostasis. The pericardial defect was repaired using 3-0 continuous prolene sutures. A chest tube was inserted from a separate incision, and the surgical wound was closed in a standard fashion.

The patient was extubated 2 days after arrival in the surgical intensive care unit. She had an uneventful hospital course and was discharged 13 days after the surgery with no serious complications. The patient has returned to home life, with no problem for the past 5 months.

III. Discussion

The surgical technique to repair a diaphragmatic injury is relatively simple, but diagnosis is difficult in many cases. Particularly, a right diaphragmatic rupture is often asymptomatic, which delays the diagnosis. The accuracy of preoperatively identifying and diagnosing diaphragmatic discontinuity on a chest CT scan has been improved, but only 31-43.5% of diaphragmatic ruptures are diagnosed preoperatively.⁽⁵⁾ Traumatic diaphragmatic injuries are commonly associated with injuries to other internal organs, such as the spleen, ribs, or vascular system, so a diagnosis of a diaphragmatic injury may be an indicator of other serious injuries.⁽⁶⁾

The diaphragm is composed of a central tendon connected to the pericardium, and muscle attached peripherally to the sternum, ribs, and lumbar spine. Due to these anatomic features, if high abdominal pressure injures the central tendon, the injury can extend to the pericardium, which is connected to the diaphragm, although it is uncommon.^(3,4) A surgical approach through a laparotomy is recommended in some cases during the immediate postoperative period, and only a drain tube should be inserted for an isolated pericardial injury, but the characteristics of the particular case should determine the treatment course.⁽⁷⁾

There is usually only 1 case per year of diaphragmatic and pericardial injuries, and a preoperative diagnosis is difficult in many cases.^(3,4,7,8) Blunt pericardial rupture is very rare with an incidence of 0.08% (16/20,000 patients) reported by Fulda et al.

(9) Delayed diagnosis can prolong hospital stay length and increase morbidity.⁽¹⁰⁾ Therefore, early diagnosis and treatment are particularly important for diaphragmatic injuries accompanying injuries to other organs. But, pericardial-diaphragm injury had not been certainty on preoperative evaluation in many cases. These injuries are unusual in blunt trauma and are often associated with other abdominal injuries. Because CT could not accurately determine the traumatic pericardial injury, the intraoperative elaborate exploration was crucial in confirming the damage. In the present case, the patient had few cardiogenic complaints that would normally indicate right ventricle injury. As a result, incidental pericardial damage was detected only while repairing the diaphragmatic injury, and therefore, concurrent surgery was performed.

We recommend caution and further investigation if a patient exhibits behavior indicative of chest and abdomen injuries without cardiopulmonary symptoms and with normal findings on chest CT. Pericardial injury may have occurred and there is a significant risk of mortality.

Based on our review of previous studies, no other case in South Korea has been reported. This report does have genuinely some useful roles in medical research and evidence-based medicine in South Korea. In particular, this report has facilitated recognition of new diseases and adverse effects of treatments. This case also has a relevant role in medical education, providing a structure for case based learning.

REFERENCES

- 1) Scharff JR, Naunheim KS. Traumatic diaphragmatic injuries. *Thorac Surg Clin* 2007; 17: 81-5.
- 2) Hanna WC, Ferri LE. Acute traumatic diaphragmatic injury. *Thorac Surg Clin* 2009; 19: 485-9.
- 3) Sharma OP. Pericardio-diaphragmatic rupture: five new cases and literature review. *J Emerg Med* 1999; 17: 963-8.
- 4) Witkowski Z, Lasek J, Wujtewicz M, Stasiak M, Marks W, Kawecka A. Pericardiodiaphragmatic rupture and cardiac herniation after multiple blunt trauma: diagnostic and therapeutic difficulties. *J Thorac Cardiovasc Surg* 2005; 130: e1-2.
- 5) Thoongsuwan N, Kanne JP, Stern EJ. Spectrum of blunt chest injuries. *J Thorac Imaging* 2005; 20: 89-97.
- 6) Meyers BF, McCabe CJ. Traumatic diaphragmatic hernia. Occult marker of serious injury. *Ann Surg* 1993; 218: 783-90.
- 7) Turhan K, Makay O, Cakan A, Samancilar O, Firat O, Icoz G,

- Cagirici U. Traumatic diaphragmatic rupture: look to see. *Eur J Cardiothorac Surg* 2008; 33: 1082-5.
- 8) van Loenhout RM, Schiphorst TJ, Wittens CH, Pinckaers JA. Traumatic intrapericardial diaphragmatic hernia. *J Trauma* 1986; 26: 271-5.
- 9) Fulda G, Brathwaite CE, Rodriguez A, Turney SZ, Dunham CM, Cowley RA. Blunt traumatic rupture of the heart and pericardium: a ten-year experience (1979-1989). *J Trauma* 1991; 31: 167-72.
- 10) Gunn JM, Savola J, Isotalo K. Left-sided diaphragmatic and pericardial ruptures with subluxation of the heart after blunt trauma. *Ann Thorac Surg* 2012; 93: 317-9.