

Original Article

A Diagnostic Imaging Case of Cervical Spinal Subluxation for Chuna Manual Therapy: Cervical Malposition with OPLL

Hyun-Jong Na¹, Seok-Gon Chang²

¹The 3rd Korean Medicine Hospital, South Korea

²Tong Korean Medicine Hospital, South Korea

Objectives: A diagnostic imaging in a fifty five year-old woman diagnosed orthopedically as ossification of posterior longitudinal ligament (OPLL) at C5 and C6 levels was reinterpreted for Chuna manual therapy. The cervical spinal lesion in simple X-ray and CT scan images was discussed by spinal listing systems and disc block subluxation theory. The primary adjustive target was C4 disc block subluxation, which had been affected by kyphosis. Chuna manual therapy based on diagnostic images could be helpful for adjusting spinal subluxation, correcting its adaptation curvature, and preventing its latent pathology efficiently.

Key Words : Chuna, OPLL, Spinal subluxation.

Preface

The Korean Society of Chuna Manual Medicine for Spine & Nerves has announced spinal listing systems based on vertebral body motion and kinesiological terms^{1,2}. Lee et al. introduced simple X-ray figures of lumbar spinal malpositions². They are classified and listed into both non-neutral (type II) mechanical coupling, extension, rotation and side-bending (ERS) type or flexion, rotation and side-bending (FRS) type, and neutral (type I) mechanical coupling, which occurs in the thoracic and lumbar spine^{2,3}.

Type II mechanics takes place when there is alteration in the anteroposterior curve into forward or backward bending which places bending forces onto and allows the facets to control motion³. When a

disc block subluxation becomes chronic, adaptation to its malposition produces curvature⁴.

Then, comparing simple X-ray and CT scan images in a fifty five year old woman diagnosed orthopedically as ossification of posterior longitudinal ligament (OPLL) with stable vital signs and normal laboratory findings, we listed and diagnosed the condition for Chuna manual therapy.

Case and discussion

Type II mechanics results when side bending and rotation of vertebrae occur to the same side^{1,2,3}. C4 malposition immediately above both C5 and C6 with OPLL at their bodies is illustrated as type II mechanical function disorder (Fig. 1.). The facets do control type II motion³. Kyphotic cervical spine

• Received : 7 July 2016 • Revised : 19 December 2016 • Accepted : 19 December 2016

• Correspondence to : Hyun-Jong Na

The 3rd Korean Medicine Hospital, 596 Dongcheon-dong Seo-gu, Kwangju

Tel : +82-62-229-3333, Fax : +82-62-229-3331, E-mail : kodna@naver.com

places the weight bearing burden of the skull inordinately upon the discs, then the weight factor is removed from the facets, and thus the vertebrae are more easily involved in rotatory and repositioning subluxations⁴). Though gravity at C4 looks loaded rather anterior on plumb line (Fig. 1.-B), the posterior portion of C4-5 disc space is wider than anterior and cervical kyphosis is shown with C4-rotary malposition (Fig. 1.-B').

If the vertebral body immediately above a disc wedge is rotated away from the open side of the disc wedge in relation to the vertebra immediately below, then the nucleus has shifted toward the open side of the disc wedge, and the resulting inferiority allows

for a body rotation to the opposite side and a separation of the inferior facet⁴). The body of C4 rotates toward the opposite side of the disc bulge in relation to C5, and it forms a typical disc block subluxation (Fig. 1.-A & -A'). It was inspected visually that head looked tipped to the right more apparently than Fig. 1.-A.

The pain of the subluxation results from the stretch upon the ligamentous structures of the vertebral joints due to the malposition, and this stretch reflex pain are involved especially in the capsular ligaments of the facets and the joints of Luschka⁴). In addition, this case could be developed chronically into leftward C4-5 protruded disc

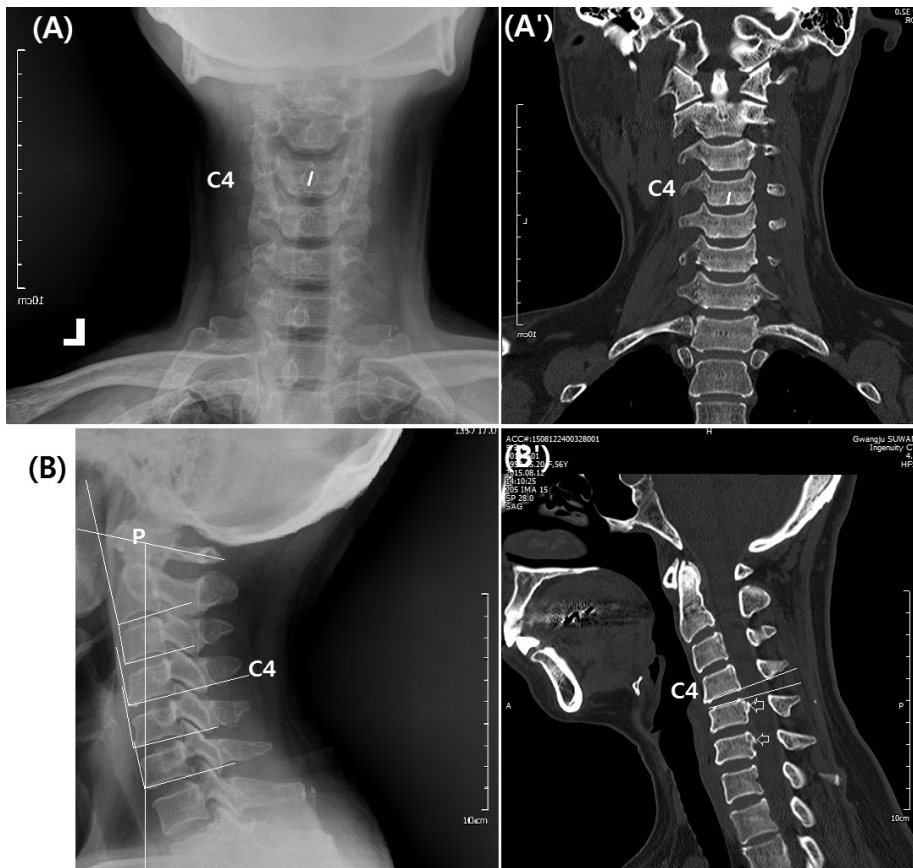


Fig. 1. Cervical spinal malposition with OPLL at C5 and C6 body levels.

disorder in that objective symptoms indicate the side of disc wedge. The therapeutic target for Chuna manual therapy in this case is not OPLL but C4 subluxation. The more cervical range of motion restricted due to OPLL at C5 and C6 levels is forced to move but their fixation is not solved, the more the condition is developed into

C4-5 disc disorder with radiculopathy. Six months later after C4 adjustment QW for 2weeks, her less cervical radiculopathic complain is proved somewhat morphologically, in that C4 in <Fig. 2> is less malpositioned than that of <Fig. 1>.

In that the posterior portion of C4-5 disc space is wider than anterior (B'), though gravity at C4 is loaded rather anterior on plumb line (B), nucleus pulposus at the level is supposed to be shifted posterior than others. The condition of C4 is listed Posterior left Superior spinous C4 by Palmer-Gonstead listing systems, Right rotational malposition/Right lateral flexion malposition by Medicare (A & A'), or Type II (C4-Extension, Right rotation/Right lateral flexion malposition; ERSR) by modified listing systems. OPLL is abbreviation of ossification of posterior longitudinal ligament, and the lesion is shown as arrows at C5 and C6 levels (B'). P is

abbreviation of plumb line (B).

Summary

A type II mechanics, which is controlled by the facet, immediately above OPLL at C5 & C6 levels and its adaptation response are mediated by kyphosis. Applied high velocity-low amplitude adjustive therapy in Chuna manipulation techniques and adjusted C4 subluxation, it could be efficient for controlling its related stretch reflex pain, for correcting reversible adaptation curvature superior to C4, and for preventing C4-5 disc disorder. In that 32 cases in Pubmed show that adverse effect related to cervical rotation and high velocity-low amplitude thrust manipulation, It is by licensed medical practitioners that Chuna manual therapy should be taken⁵⁾, and image diagnostic spinal listing analysis preceded.

References

1. Shin BC, Cho HW, Hwang EH, Seol JW, Shin MS, Nam HW. An Literatual Study of Listing

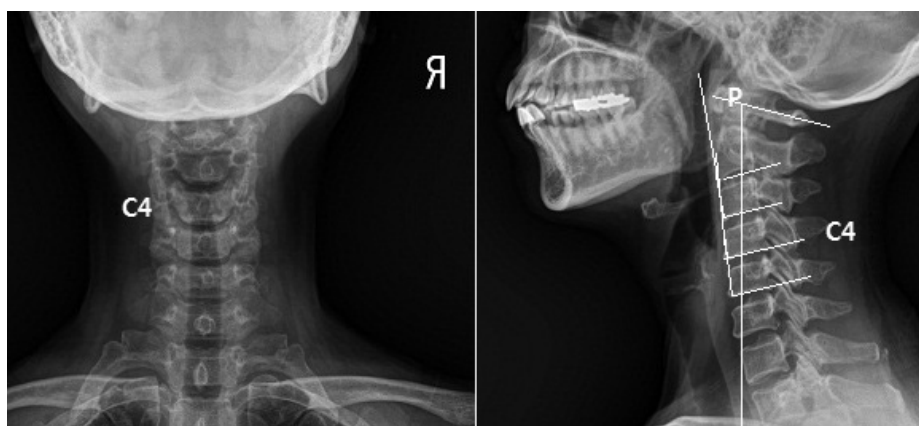


Fig. 2. Change of C4 position with OPLL at C5 and C6 body levels after 6 months.

- System of Spinal Subluxation. JKCMSN. 2011; 6(1):141-148.
2. Lee JH, Kim CG, Cho DC, Moon SJ, Park TY, Ko YS, et al. Diagnostic X-ray from the Perspective of Chuna Manual Medicine, Based on the Listing System of Spinal and Pelvic Subluxation. JKCMSN. 2014;9(1):1-14.
 3. DeStefano LA. Greenman's Principles for Manual Medicine. 4th ed. Wolters Kluwer: Lippincott Williams & Wilkins. 2011:57-58, 68-76, 301-302.
 4. Barge FH. Torticollis. Barge Chiropractic Clinic S. C. 1979: 13, 18, 19, 35, 47, 116.
 5. Jeong SY, Lee CR. Research about Adverse Effect of Spinal Manipulation Therapy: Systemic Review of Literature in Korea and Pubmed. JKCMSN. 2015;10(1):15-33.