



Phelan-McDermid syndrome presenting with developmental delays and facial dysmorphisms

Yoon-Myung Kim, MD^{1*}, In-Hee Choi^{2*}, Jun Suk Kim, MD¹, Ja Hye Kim, MD¹, Ja Hyang Cho, MD¹, Beom Hee Lee, MD¹, Gu-Hwan Kim, PhD², Jin-Ho Choi, MD¹, Eul-Ju Seo, MD², Han-Wook Yoo, MD, PhD^{1,2}

¹Department of Pediatrics, ²Medical Genetics Center, Asan Medical Center Children's Hospital, University of Ulsan College of Medicine, Seoul, Korea

Phelan-McDermid syndrome is a rare genetic disorder caused by the terminal or interstitial deletion of the chromosome 22q13.3. Patients with this syndrome usually have global developmental delay, hypotonia, and speech delays. Several putative genes such as the *SHANK3*, *RAB*, *RABL2B*, and *IB2* are responsible for the neurological features. This study describes the clinical features and outcomes of Korean patients with Phelan-McDermid syndrome. Two patients showing global developmental delay, hypotonia, and speech delay were diagnosed with Phelan-McDermid syndrome via chromosome analysis, fluorescent in situ hybridization, and multiplex ligation-dependent probe amplification analysis. Brain magnetic resonance imaging of Patients 1 and 2 showed delayed myelination and severe communicating hydrocephalus, respectively. Electroencephalography in patient 2 showed high amplitude spike discharges from the left frontotemporoparietal area, but neither patient developed seizures. Kidney ultrasonography of both the patients revealed multicystic kidney disease and pelviectasis, respectively. Patient 2 experienced recurrent respiratory infections, and chest computed tomography findings demonstrated laryngotracheomalacia and bronchial narrowing. He subsequently died because of heart failure after a ventriculoperitoneal shunt operation at 5 months of age. Patient 1, who is currently 20 months old, has been undergoing rehabilitation therapy. However, global developmental delay was noted, as determined using the Korean Infant and Child Development test, the Denver developmental test, and the Bayley developmental test. This report describes the clinical features, outcomes, and molecular genetic characteristics of two Korean patients with Phelan-McDermid syndrome.

Key words: Phelan-McDermid syndrome, Chromosome 22q13.3 deletion syndrome, SHANK3

Introduction

Phelan-McDermid syndrome (PMS) is a rare genetic disorder caused by the deletion of chromosome 22q13.3¹⁾. Infants or children with this syndrome manifest diverse clinical features, such as seizures, hypotonia, absent or severely delayed speech, global developmental delay, hearing and visual impairment, strabismus, autism-like behavior, cyclic vomiting, normal or advanced growth, and precocious puberty^{1,2)}. Patients with PMS also present minor dysmorphic facial features, such as deep-set eyes, poorly formed ears, and a bulbous nose¹⁾. The neurological features of this syndrome are nonspecific, and it can be underrecognized along with other genetic diseases that show developmental delays. The mental retardation and developmental delays of these patients are mainly caused by deletions of the SH3 and multiple ankyrin repeat domains 3 (*SHANK3*) genes¹⁾. The *SHANK3* gene encodes a structural protein located in the post-synaptic membrane and plays an important role in signal transduction³⁾.

Corresponding author: Han-Wook Yoo, MD, PhD
Department of Pediatrics, Asan Medical Center
Children's Hospital, University of Ulsan College of
Medicine, 88 Olympic-ro 43-gil, Songpa-gu, Seoul
05505, Korea
Tel: +82-2-3010-3374
Fax: +82-2-473-3725
E-mail: hwyoo@amc.seoul.kr

*These authors contributed equally to this study and should be considered co-first authors.

Received: 4 August, 2014
Revised: 11 October, 2014
Accepted: 20 October, 2014

Copyright © 2016 by The Korean Pediatric Society

This is an open-access article distributed under the terms of the Creative Commons Attribution Non-Commercial License (<http://creativecommons.org/licenses/by-nc/4.0/>) which permits unrestricted non-commercial use, distribution, and reproduction in any medium, provided the original work is properly cited.

Chromosome analysis is required for evaluation of congenital anomalies and developmental delay. However, it is not suitable for detecting microdeletion. Therefore, fluorescence in situ hybridization (FISH) or multiplex ligation-dependent probe amplification (MLPA) analysis is commonly utilized to identify the microdeletion of the chromosome 22q13.3 region^{1,2,4}. In addition, array comparative genomic hybridization is a useful method for discovering unbalanced translocations⁵.

To date, over 600 cases of PMS have been reported worldwide¹; however, only 1 case has been reported in Korea⁶. This report describes the clinical features, outcomes, and molecular data of two patients with PMS in Korea.

Case report

1. Case 1

A 4-month-old female, who was born after 39 weeks of gestation with a birth weight of 3,220 g, was referred to our outpatient clinic. An abdominal mass was found during the prenatal

ultrasonography, and postnatal ultrasonography determined that it was a multicystic dysplastic kidney although renal function was normal. The patient underwent ligation surgery for patent ductus arteriosus at age 3 weeks. At age 4 months, her eyes could not follow objects, and she displayed hypotonia. Her weight, height, and head circumference were 7.4 kg (50th–75th percentile), 72.4 cm (>97th percentile), and 40 cm (25th–50th percentile), respectively. She had low-set ears, deep-set eyes, wide eyebrows, and a bulbous nose. Brain magnetic resonance imaging (MRI) revealed delayed myelination (Fig. 1A). High amplitude spike discharges from the left frontotemporoparietal area were seen on electroencephalography, but the patient did not present with seizures. Global developmental delay was noted on the Korean infant and child development test performed at age 4 months: her gross motor development level was 1 month, fine motor 3 months, personal-social 2 months, language 2 months, and cognitive-adaptive 3 months.

Chromosome analysis showed 46,XX,del(22)(q13.3) (Fig. 1B). FISH using an *HIRA* (22q11.2) and *ARSA* (22q13) probes (Vysis, Abbott Laboratories, Abbott Park, IL, USA) identified the deletion

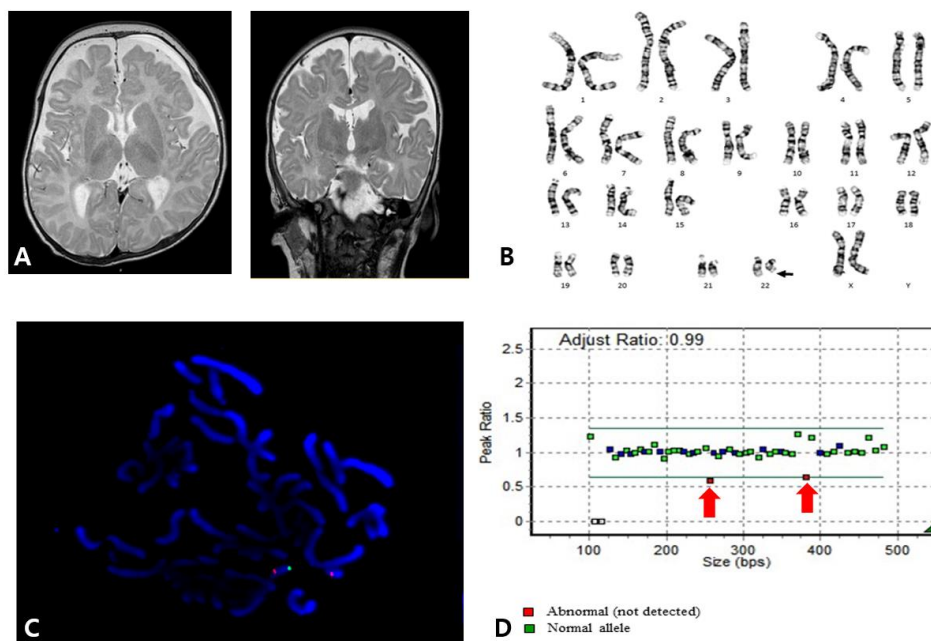


Fig. 1. (A) Brain magnetic resonance imaging (MRI) of patient 1 showing diffuse high-signal intensities in the T2-weighted image of the supratentorial white matter (bilateral subcortical, deep, periventricular white matter, and the anterior and posterior limbs of the internal capsule), indicating delayed myelination. (B) Karyotype of patient 1 revealing 46,XX,del(22)(q13.3). (C) Fluorescent in situ hybridization of patient 1 using *HIRA* (DiGeorge region) probe on 22q11.2 (orange) and *ARSA* probe on 22q13 (green) (Vysis, Abbott Laboratories, Abbott Park, IL, USA) showing heterozygous deletion of the 22q13 region. Otherwise, 22q11.2 (*HIRA*) was not deleted. (D) Multiplex ligation-dependent probe amplification (MLPA) analysis of patient 1 was performed using the SALSA MLPA P064-C1 Reference Kit (MRC Holland, Amsterdam, The Netherlands), according to the manufacturer's instructions. Amplified products were separated using the ABI3130xl Genetic Analyzer (Applied Biosystems, Foster City, CA, USA) and were analyzed using GeneMarker v.1.70 Software (Softgenetics LLC, State College, PA, USA). Two red spots representing the *SHANK* gene showed heterozygous deletion on the 22q13 region.

of the *ARSA* gene (Fig. 1C). In addition, MLPA analysis using the SALSA MLPA P064-C1 kit (MRC Holland, Amsterdam, The Netherlands) revealed the deletion of the *SHANK3* gene located on 22q13.3 (Fig. 1D). Neither parent had a chromosome analysis.

At age 8 months, the patient could neither hold her head up nor crawl, but she could roll over by herself and babble. Reaching for and grasping an object was not possible. Global developmental delay was observed in the Denver developmental test: her personal-social development level was 3 months, fine motor-adaptive 3 months, language 6 months, and gross motor 4 months.

Currently, she is 17 months old and still not able to hold her head up. Sitting is possible only when her hands are supported. She is not able to respond to her name. The Bayley developmental test demonstrated a cognitive development level of three months, language 4 months, social 4 months, gross motor 5 months, and fine motor 4 months.

2. Case 2

A 4-month-old male was referred to the outpatient clinic for an evaluation of developmental delays. He was born at 38 weeks of gestation with a birth weight of 3,480 g without perinatal problems. There was no family history of congenital anomalies or consanguinity. His prenatal evaluation was unremarkable. Congenital hypothyroidism was diagnosed at age 2 weeks. He was admitted to a local hospital due to recurrent respiratory infections at age 1 month. At 4 months of age, he was not able to control his head or make eye contact with others. His weight, height, and head circumference were 8.7 kg (50th–75th percentile), 67 cm (75th–90th percentile), and 47 cm (>97th percentile), respectively. He showed facial hypotonia, sunset eyes, long eyelashes, dolicocephaly, and relative macrocephaly. Chest computed tomography was performed due to recurrent respiratory infections, and focal narrowing of the mid trachea and left main bronchus between the aorta and pulmonary artery were found. In addition, flexible bronchoscopy showed tracheomalacia and

laryngomalacia. There were no cardiac anomalies on echocardiography. Kidney ultrasonography showed right renal pelvicaliectasis. Communicating hydrocephalus with interstitial edema of periventricular white matter was observed on a brain MRI, and this required a ventriculoperitoneal shunt at age 5 months (Fig. 2A). One day after the procedure, heart failure and cardiac arrest occurred, and the patient subsequently died of multiple organ failure. His karyotype was 46,XY,r(22)(p13q13) while both parents had normal karyotypes (Fig. 2B). Deletion of chromosome 22q13.3 was identified by FISH.

Discussion

PMS is a rare disease, and its incidence remains elusive^{1,2}. Facial dysmorphisms, such as long eyelashes, deep-set eyes, ptosis, prominent dysplastic ears, a bulbous nose, and a wide nasal bridge, may indicate this disease^{2,4}. Relatively large fleshy hands, and hypoplastic or dysplastic toenails of the extremities are also present². Growth velocity is usually normal or accelerated⁷. Renal abnormalities or cardiac defects are observed in approximately 25% of cases^{1,2}. Gastrointestinal symptoms, such as feeding difficulties, cyclic vomiting, and gastroesophageal reflux, can be associated with PMS^{1,2}. Neurological manifestations include seizures or aggressive behavior^{1,2}.

Although patients with PMS have nonspecific clinical features and diverse clinical courses, it is helpful to perform chromosome analysis to evaluate patients with congenital anomalies and developmental delays. The size of the deleted region in PMS varies widely, ranging from a very small deletion of 100 kb to a very large one of over 9 Mb⁸. However, the deletion size is not accurately correlated with the severity of the disease. Several genes located in the 22q13.3 region, such as the *SHANK3*, *RAB*, *RABL2B*, and *IB2* genes, are thought to be related to neurological features. The *SHANK3* gene is located on the distal region to *ARSA* which is known to cause metachromic leukodystrophy.

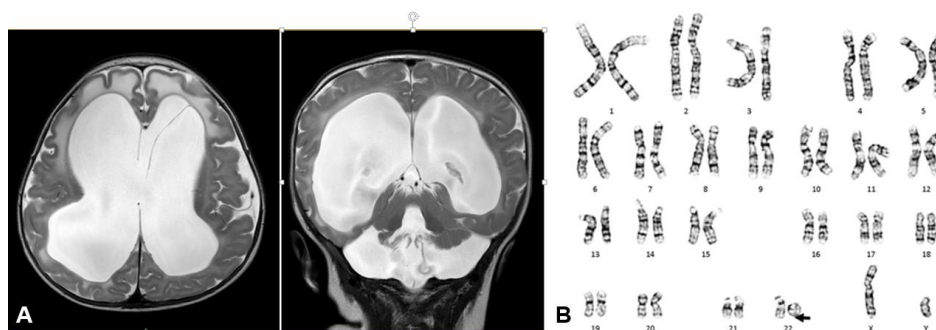


Fig. 2. (A) Brain magnetic resonance imaging of patient 2 showing severe communicating hydrocephalus with interstitial edema of the periventricular white matter. (B) Patient 2 was of 46,XY,r(22)(p13q13) karyotype.

Table 1. Clinical and cytogenetic characteristics of Korean patients with Phelan-McDermid syndrome

No. of cases	Karyotype	Parent's karyotype	Clinical features
1	46,XX,del(22)(q13.3)	Unknown	Global developmental delay, hypotonia, delayed speech, low set ears, deep set eyes, wide eyebrows, bulbous nose, delayed myelination, multicystic kidney disease
2	46,XY,r(22)(p13q13)	Normal	Global developmental delay, hypotonia, delayed speech, facial hypotonia, sunset eyes, long eyelashes, dolicocephaly, macrocephaly, hydrocephalus, hypothyroidism, pelviectasis, laryngotracheomalacia, bronchus narrowing
Previous report ⁶⁾	46,XX,del(22)(q13.3)	Normal	Global developmental delay, hypotonia, delayed speech, long eyelashes, puffy cheeks, bulbous nose, pointed chin, thin corpus callosum

The SHANK3 protein plays a major role in interlinking between proteins of the postsynaptic membrane and the actin cytoskeleton of the dendritic spine, and it is related to synaptic spine maturation³⁾. Mutations in the *SHANK3* gene is also known to be related to neuropsychiatric conditions such as autism spectrum disorder⁹⁾. Deletions of the *ARSA* and *SHANK3* genes were identified using FISH and MLPA analysis in the present study.

Only one case of PMS has been reported in Korea⁶⁾. An 18-month-old female with hypotonia and developmental delays was diagnosed by chromosome analysis and FISH using an *ARSA* probe. The patient's karyotype was 46,XX,del(22)(q13.3), and both parents had normal karyotypes. Brain MRI showed a thin corpus callosum and a decreased white matter volume. This patient underwent rehabilitation therapy, but she was still not able to uphold her head or make eye contact at 3 years (Table 1)⁶⁾. Global developmental delay, hypotonia, and delayed speech were the main clinical features both found in the previous⁶⁾ and the present study. Patient 2 who had terminal deletion of 22q13.3 resulting from ring chromosome, showed worse prognosis compared to those who had microdeletion of 22q13.3 region.

Most patients usually have no life-threatening organ dysfunction or events⁴⁾. However, patient 2 in the present study had severe hydrocephalus urgently necessitating immediate intervention in contrast to patient 1. This patient also had an airway anomaly, which has not been reported in other cases of PMS.

Rehabilitation therapy was applied to increase muscle tone and improve developmental delays. Although progress was slow, obvious enhancement of muscle tone and development was observed.

In summary, this report described the clinical features, outcomes, and molecular genetic data in 2 cases of PMS in Korea. In the event that hypotonia, severe speech delays, mildly dysmorphic facial features, and multiple congenital anomalies involving the kidneys, heart, or toenails are present, PMS should be considered among the possible diagnoses, and molecular cytogenetic testing

should be undertaken for confirmation.

Conflict of interest

No potential conflict of interest relevant to this article was reported.

References

- Phelan K, McDermid HE. The 22q13.3 Deletion Syndrome (Phelan-McDermid Syndrome). *Mol Syndromol* 2012;2:186-201.
- Phelan MC. Deletion 22q13.3 syndrome. *Orphanet J Rare Dis* 2008;3:14.
- Guilmatre A, Huguet G, Delorme R, Bourgeron T. The emerging role of SHANK genes in neuropsychiatric disorders. *Dev Neurobiol* 2014;74:113-22.
- Sarasua SM, Boccuto L, Sharp JL, Dwivedi A, Chen CF, Rollins JD, et al. Clinical and genomic evaluation of 201 patients with Phelan-McDermid syndrome. *Hum Genet* 2014;133:847-59.
- Jacquemont ML, Sanlaville D, Redon R, Raoul O, Cormier-Daire V, Lyonnet S, et al. Array-based comparative genomic hybridisation identifies high frequency of cryptic chromosomal rearrangements in patients with syndromic autism spectrum disorders. *J Med Genet* 2006;43:843-9.
- Na SR, Im BC, You JH, Cho HM, You EJ, Kim SJ, et al. A case of 22q13 deletion syndrome. *J Korean Child Neurol Soc* 2010;18:338-44.
- Rollins JD, Sarasua SM, Phelan K, DuPont BR, Rogers RC, Collins JS. Growth in Phelan-McDermid syndrome. *Am J Med Genet A* 2011;155A:2324-6.
- Wilson HL, Wong AC, Shaw SR, Tse WY, Stapleton GA, Phelan MC, et al. Molecular characterisation of the 22q13 deletion syndrome supports the role of haploinsufficiency of SHANK3/PROSAP2 in the major neurological symptoms. *J Med Genet* 2003;40:575-84.
- Boccuto L, Lauri M, Sarasua SM, Skinner CD, Buccella D, Dwivedi A, et al. Prevalence of SHANK3 variants in patients with different subtypes of autism spectrum disorders. *Eur J Hum Genet* 2013;21:310-6.