



# Does the maxillary anterior ratio in Korean adults follow the Golden Proportion?

Ming-Xu Jin<sup>1</sup>, Min-Ho Hong<sup>2</sup>, Kee-Joon Lee<sup>3</sup>, Kyu-Bok Lee<sup>1\*</sup>

<sup>1</sup>Department of Prosthodontics, College of Dentistry and Advanced Dental Device Development Institute, Kyungpook National University, Daegu, Republic of Korea

<sup>2</sup>Department of Bio-medical Research Institute, Kyungpook National University Hospital, Daegu, Republic of Korea

<sup>3</sup>Department of Orthodontics, Yonsei University College of Dentistry, Oral Science Research Center, Institute of Craniofacial Deformity, Yonsei University College of Dentistry, Seoul, Republic of Korea

**PURPOSE.** The purpose of this study was to determine the effect of changes in the horizontal plane angle on the mesiodistal width ratios of the maxillary anterior teeth during the acquisition of frontal view photographs, derive these ratios for Korean adults on the basis of the data obtained, and analyze them using the Golden Proportion as a reference. **MATERIALS AND METHODS.** In experiment I, 30 plaster casts were mounted on an articulator and positioned on the angle-measuring device with a center setting of 0°. The device was rotated to 10° in 1° increments in a counterclockwise direction. At each angle, photographs were obtained and analyzed. Experiment II was based on 60 patients who visited the Department of Prosthodontics at Kyungpook National University Dental Hospital from February 2012 to February 2015. The patients were divided into three groups [Male (M), Female (F), Total (M + F)]. Frontal views were obtained for all groups and analyzed. **RESULTS.** From 1° to 10°, the relative mesiodistal width ratios for the maxillary anterior teeth showed no significant differences from those at 0°. In all three groups, the relative width ratio of the maxillary central incisor was smaller than that specified in the Golden Proportion; the opposite was true for the canine. **CONCLUSION.** Our results suggest that the mesiodistal width ratios of the maxillary anterior teeth do not follow the Golden Proportion in Korean adults, and that a change in the horizontal plane angle from 1° to 10° during frontal photography does not affect these ratios. [J Adv Prosthodont 2016;8:125-30]

**KEY WORDS:** Korean adults; Maxillary anterior mesiodistal width ratio; Golden Proportion

## INTRODUCTION

There has been an increasing number of patients visiting dental clinics for the improvement of anterior esthetics.<sup>1</sup> However, there is no absolute standard for esthetic beauty,

and ideals vary depending on the time, environment, race, and individual features. Since the human desire to be viewed as beautiful is common and universal, a study of the esthetic facial profile is important.<sup>2</sup>

Esthetics in the facial profile is considerably influenced by the shape and alignment of the anterior teeth and the facial skeletal structure. The shape of the anterior teeth is considered one of the most important factor for the evaluation of facial esthetics.<sup>3,4</sup> The determinants of anterior teeth esthetics can be classified as gingival and tooth-related,<sup>5</sup> and these can be divided further by the shape and color of each tooth, width ratio relative to the adjacent tooth, and other factors. The maxillary anterior mesiodistal width ratios play an important role in the formation of a balanced dentition. Throughout history, the Golden Proportion has been a broadly applied concept in various fields, including mathematics and architecture. In 1973, Lombardi<sup>6</sup> first

Corresponding author:

Kyu-Bok Lee  
Department of Prosthodontics, College of Dentistry and Advanced Dental Device Development Institute, Kyungpook National University, 2177 Dalgubuldaero, Jung-gu, Daegu 41940, Republic of Korea  
Tel. 82 536007674; e-mail, kblee@knu.ac.kr  
Received August 7, 2015 / Last Revision November 30, 2015 / Accepted December 14, 2015

© 2016 The Korean Academy of Prosthodontics  
This is an Open Access article distributed under the terms of the Creative Commons Attribution Non-Commercial License (<http://creativecommons.org/licenses/by-nc/3.0>) which permits unrestricted non-commercial use, distribution, and reproduction in any medium, provided the original work is properly cited.

introduced the concept of the Golden Proportion to the field of dentistry in order to achieve a balance between a patient's facial profile and dentition. Lombardi also mentioned<sup>6</sup> that denture teeth, when observed from the frontal view, would be more esthetic if the ratios of the mesiodistal widths of the central and lateral incisors, lateral incisors and canines, and canines and first premolars remain constant. In the 1970s, Levin<sup>7</sup> improved upon the concept of the Golden Proportion in dentistry by the application of visual and perceptual principles. According to the Golden Proportion proposed by Snow,<sup>8</sup> the ratios for the central incisor (mesiodistal width of the central incisor:mesiodistal width of the lateral incisor), lateral incisor (mesiodistal width of the lateral incisor:mesiodistal width of the canine), and canine (mesiodistal width of the canine:mesiodistal width of the first premolar) are 1.618, 1, and 0.618, respectively, from the frontal view. In other words, Snow asserted that the central incisor should be approximately 60% larger than the lateral incisor, which, in turn, should be 60% larger than the canine. Richer<sup>9</sup> emphasized that the Golden Proportion is the guideline for planning esthetic anterior restorations.

However, according to the study by Preston<sup>10</sup> in 1993, the ratio of the mesiodistal widths of the central and lateral incisors followed the Golden Proportion in only 17% of all cases. In addition, the ratios for the lateral incisors and canines did not follow the Golden Proportion in any clinical case. A recent study by Forster *et al.*<sup>11</sup> revealed that the mesiodistal width ratios for the maxillary central incisor, lateral incisor, and canine did not follow the Golden Proportion in a Hungarian population. Moreover, data on the relative mesiodistal width ratios of the maxillary anterior teeth in the Korean adult population are insufficient, and some clinicians are still believed to follow the Golden Proportion while restoring the anterior teeth in this population. A textbook commonly used in Korean universities also mentions that the Golden Proportion must be considered during esthetic restorations.<sup>12</sup> Further studies on this topic are therefore necessary.

Although several studies have focused solely on the width/length ratio of the anterior teeth,<sup>13-15</sup> there are fewer systematic studies on the relative maxillary anterior mesiodistal width ratio, with even fewer studies on this ratio in Korean adults. In a previous study<sup>11</sup> that analyzed the maxillary anterior mesiodistal width ratio, researchers analyzed frontal view images of patients on the basis of their experience. However, these images cannot be considered absolute because of the potential for influence by variations in the angle during image acquisition.

From the above perspectives, we conducted this study to determine the influence of a change in the horizontal plane angle on the mesiodistal width ratios of the maxillary anterior teeth during the acquisition of frontal view photographs, derive these ratios in Korean adults on the basis of the data obtained, and analyze them using the Golden Proportion as a reference.

## MATERIALS AND METHODS

During frontal photography of a patient, it is difficult to obtain an absolute frontal view. To determine the influence of a change in the horizontal plane angle on the intermaxillary width ratios in the anterior region, we mounted 30 plaster casts of patients on an articulator and conducted Experiment I as follows.

To manufacture the angle-measuring device, an assembly diagram was designed using the 3D modeling program CATIA V6 (Dassault Systems, Paris, France). The device was manufactured upon request at Kyungpook National University, College of Engineering (Fig. 1). The base disk can be rotated by using the central axis of the base plate as a pivot. Using the axis on the higher part as a base, the articulator was installed, with 0° set as the standard. The articulator was designed such that it could be rotated by 10° to the left and right.

A plaster cast was mounted on the articulator and positioned at the center of the rotation base disk of the angle-measuring device. The camera lens (Canon EF 100 mm f/2.8 Macro USM; Canon Inc., Tokyo, Japan) was connected to the digital camera (Canon 600D), and the distance between the anterior part of the cast and lens was set to 40 cm. Using the camera's tripod, the camera was fixed to the same height as the plaster cast. A photograph was obtained after setting the marked line of the rotation disk to 0° on the base plate. Then, the base disk was rotated in a counterclockwise direction in increments of 1°, and photographs were obtained at each angle from 1° to 10°.

Experiment II was based on 60 patients who visited the Department of Prosthodontics at Kyungpook National University Dental Hospital from February 2012 to February 2015. Thirty men and 30 women with an average age of 30 years (Men, 28.6 ± 3.8 years; women, 30.7 ± 4.3 years) were included to eliminate the influence of age. The patients were divided into three groups (Table 1): male (M), female (F), and total (M + F).




Fig. 1. Angle-measuring device.

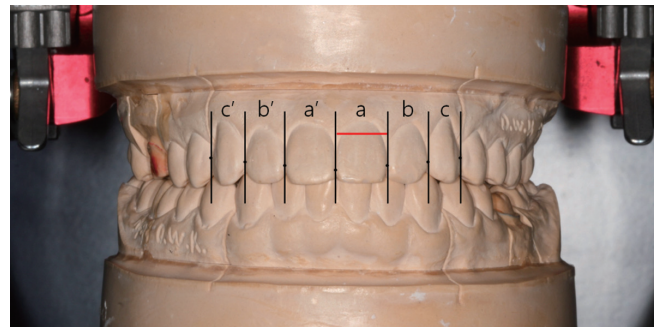
**Table 1.** Composition of each group

Group	Composition	N
Male (M)	Male patients	30
Female (F)	Female patients	30
Total (M + F)	Male and female patients (combined)	60

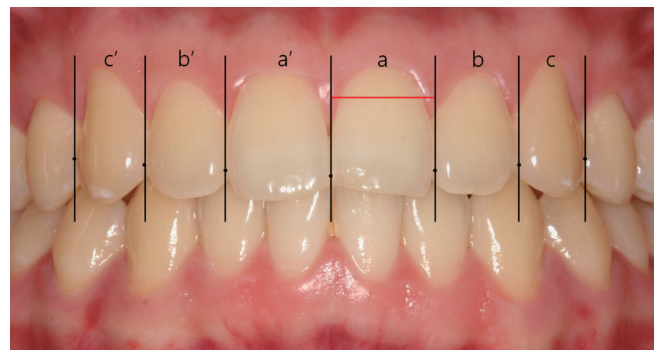
Patients with peculiar manifestations in the anterior dentition, such as microdontia, anomalies, crowding, rotation, diastema, severe malpositioning, and restorations, were excluded. However, patients with mild crowding ( $\leq 2$  mm) in this region were included on the basis of a survey of the golden ratio of general Korean not receiving orthodontic treatment. The study protocol was approved by the IRB of Kyungpook National University Hospital (KNUH-2015-02-030).

Each patient was seated in an upright position on a dental chair, with the head leaning against the headrest. With the teeth in occlusion, the head position was adjusted such that the occlusal plane was parallel and the midsagittal plane was perpendicular to the floor; consequently, both ears were at the same level (i.e., absence of tilting). Using the same technique used in experiment I, a frontal photograph of the anterior teeth was obtained by a digital camera set up at a distance of approximately 40 cm from the anterior teeth. To obtain a standardized frontal view, the photograph of the anterior teeth was corrected to a retracted frontal view with the standard magnification of 1:2 by referring to the accreditation photography guide<sup>16</sup> of the American Academy of Cosmetic Dentistry (AACD).

Experiments I and II were performed to measure and analyze the frontal photographs of patients in the same manner. Each obtained photograph was imported into the image design software (Illustrator CC; Adobe Systems Inc., San Jose, CA, USA), and a point was marked on the mesiodistal height of the contour of each maxillary anterior tooth. Then, a line was drawn vertical to the line passing through the points on the heights of the contours. The distance between each vertical line was recorded as the width of each tooth (Fig. 2, Fig. 3). The Golden Proportion, theoretically, is achieved when the central incisor is 1.618 times broader than the lateral incisor and the canine is 0.618 times narrower than the lateral incisor. Therefore, the central incisor, lateral incisor, and canine can be expressed as (a), (b), and (c), respectively, in the formula for the maxillary anterior mesiodistal width ratios, which were measured in this study by simultaneously considering the right and left sides (Fig. 4). To minimize errors during the measurement of mesiodistal widths in this program, each photograph was standardized to the same size and measured and analyzed by the same researcher.



**Fig. 2.** Marking the heights of the contours of the maxillary anterior teeth with an Illustrator CC. The mesiodistal width (red line) is the horizontal line connecting each vertical line (black lines).



**Fig. 3.** Measurement of mesiodistal widths from the frontal view. Measurements in experiments I and II were obtained in the same manner.

$$\text{Maxillary anterior ratio} = \frac{\left(\frac{a}{b} + \frac{a'}{b'}\right)}{2} : 1 : \frac{\left(\frac{c}{b} + \frac{c'}{b'}\right)}{2}$$

**Fig. 4.** The formula for the maxillary anterior mesiodistal width ratios measured on frontal photographs. Here, “a” represents the mesiodistal width of the left maxillary central incisor, “b” represents that of the lateral incisor, and “c” represents that of the canine \*indicates the other side of the same tooth.

For each result, the mean and standard deviation (SD) was determined using SPSS 20.0 (IBM Inc., Chicago, IL, USA). In Experiment I, differences in the ratios between each horizontal plane angle were tested using one-way analysis of variance (ANOVA), with Tukey’s honestly significant differences test for post hoc analysis. To verify the difference between the Golden Proportion and the anterior mesiodistal width ratios in Korean adults, one-sample t-tests were used with a significance level set at 0.05 (Experiment II).

**RESULTS**

In experiment I, one-way ANOVA and post-hoc analysis revealed no significant differences in the relative mesiodistal width ratios of the maxillary anterior teeth between the angles from 1° to 10° and 0° ( $P > .05$ ; Table 2).

The results of frontal view measurements in experiment II, including patient-specific details, means and SDs, and the mesiodistal width ratios of the maxillary anterior teeth

in relation to the Golden Proportion, are shown in Table 3.

Statistical analysis using one-sample t-tests revealed that the relative mesiodistal width ratio of the central incisor in the M ( $1.365 \pm 0.115$ ), F ( $1.414 \pm 0.108$ ), and M + F ( $1.389 \pm 0.113$ ) groups was significantly smaller than that specified in the Golden Proportion ( $P < .001$ ), while that for the canine was significantly larger (M group:  $0.840 \pm 0.094$ , F group:  $0.827 \pm 0.091$ , M + F group:  $0.833 \pm 0.092$ ;  $P < .001$ ) than that specified in the Golden Proportion (Fig. 5).

**Table 2.** Effects of changes in the horizontal plane angle during frontal photography on the mesiodistal width ratios of the maxillary anterior teeth

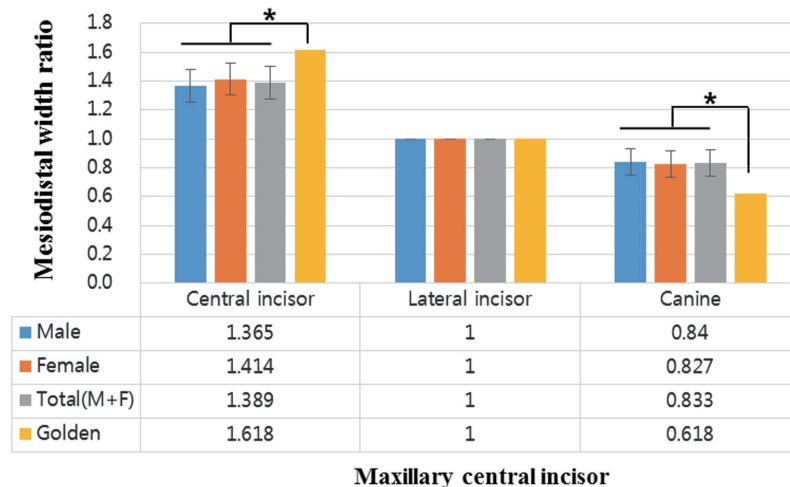
Angle	Central incisor Mean ± SD	Lateral incisor	Canine Mean ± SD
0°	1.444 ± 0.050	1	0.775 ± 0.043
1°	1.444 ± 0.050	1	0.775 ± 0.044
2°	1.444 ± 0.050	1	0.775 ± 0.044
3°	1.445 ± 0.050	1	0.774 ± 0.044
4°	1.446 ± 0.050	1	0.773 ± 0.045
5°	1.448 ± 0.050	1	0.773 ± 0.045
6°	1.446 ± 0.049	1	0.771 ± 0.045
7°	1.451 ± 0.049	1	0.765 ± 0.045
8°	1.444 ± 0.049	1	0.777 ± 0.046
9°	1.432 ± 0.048	1	0.789 ± 0.047
10°	1.434 ± 0.048	1	0.795 ± 0.048

SD: standard deviation.

**Table 3.** Descriptive statistics for the mesiodistal width ratios of the maxillary anterior teeth in the male, female, and total groups

	Central incisor Mean ± SD	Lateral incisor	Canine Mean ± SD
Male (M)	1.365 ± 0.115	1	0.840 ± 0.094
Female (F)	1.414 ± 0.108	1	0.827 ± 0.091
Total (M + F)	1.389 ± 0.113	1	0.833 ± 0.092
Golden Proportion	1.618	1	0.618

SD: standard deviation.



**Fig. 5.** Mesiodistal width ratios of the maxillary anterior teeth in relation to the Golden Proportion in the male, female, and total (male + female) groups. The lateral incisor width is always 1.0. \* indicates a significant difference as per the one-sample t-test.



## DISCUSSION

The purpose of this study was to observe the mesiodistal width ratios of the maxillary anterior teeth in Korean adults using frontal photographs and compare these ratios with those specified in the Golden Proportion. Until now, most studies on the maxillary anterior mesiodistal width ratios included western populations,<sup>8,11</sup> and data based on the Korean population is scarce. Therefore, we decided to select Koreans as our study subjects.

Proportion analysis for teeth is an important part of the analyses of dentofacial esthetics, and various techniques such as direct measurements with calipers,<sup>10</sup> photographic analysis,<sup>7</sup> cephalometry, and analysis of photograph files using computers<sup>11</sup> can be used for this purpose. In the present study, frontal photographs obtained by a digital camera were directly analyzed using a computer program. This method had several advantages, including less burdensome in terms of direct measurements of the body and the feasibility of repeated measurements. In addition, the photographs could be magnified using the computer program. These advantages collectively increased the accuracy of measurements.

We found that a horizontal plane angle within 10° did not significantly affect the anterior mesiodistal width ratios when the teeth on both sides were simultaneously considered. Levin<sup>7</sup> described the principles of visual aspects and perception. In other words, if the distance from an object increases, the object would seem to decrease in size when observed at a specific position. In the current study, the center setting was 0°, and the base disk was rotated in a counterclockwise direction in 1° increments; photographs were obtained at each angle from 0° to 10°. In this manner, the maxillary left anterior teeth rotated in the distal direction, which progressively increased the distance from the frontal position and consequently decreased the size of the object as the rotation continued toward the right side. This was probably the reason why changes in the horizontal plane angle during photography did not affect the mesiodistal width ratios. Moreover, to minimize the effect of the horizontal plane angle, the frontal photographs were obtained with the patient in the standard position used for dental panoramic radiography.

Overall, the relative mesiodistal width ratio of the central incisors in the M, F, and M + F groups was smaller than that specified in the Golden Proportion; the opposite was true for the canines in all three groups. These results are consistent with those reported previously in a study by Forster *et al.*<sup>11</sup> and can be associated with the arch form. A V-shaped arch accompanies a radical curvature. Thus, when observed from the frontal view, the widths of the lateral incisor and canine would appear smaller. Therefore, the influence of the central incisor on anterior esthetics is significant.<sup>17</sup> On the other hand, because a square arch form shows a gradual curvature toward the distal aspect, the lateral incisor and canine widths would appear larger. In such cases, the influence of the central incisor would be smaller

than that in cases of a V-shaped arch. Asians more commonly exhibit square arches compared with western populations.<sup>18</sup> Therefore, the shape of the lateral incisors and canines is relatively more important, as also suggested by the results of the present study. Furthermore, our study revealed that the Golden Proportion (1.618:1:0.618) did not apply to the anterior teeth in any of the three groups. This result is similar to those obtained by Ali *et al.*<sup>19</sup> and Hasanreisoglu *et al.*<sup>20</sup> Collectively, our results suggest that the generalized application of the Golden Proportion (1.618:1:0.618) during anterior prosthetic restorations in Korean adults can yield unaesthetic results. In other words, if the Golden Proportion is applied while restoring the anterior teeth in this population, the square arch form will become severely constricted. Therefore, the maxillary anterior teeth of Korean adults should be restored using unique and reasonable proportions based on individual characteristics.

The small sample size, limited to 60 patients, was a limitation of the present study. This was because of the difficulty in selecting patients with a normal dentition and those who were not receiving orthodontic treatment. Further studies including patients of various ages are necessary to establish an appropriate anatomical database for the Korean population.

## CONCLUSION

In conclusion, our findings revealed that a change in the horizontal plane angle from 1° to 10° during frontal photography does not affect the mesiodistal width ratios of the maxillary anterior teeth. Furthermore, we found that the mesiodistal width ratios of the maxillary anterior teeth did not follow the Golden Proportion in Korean adults, with the relative ratios for the central incisor and canines being smaller and larger, respectively, than those specified in the Golden Proportion.

## ACKNOWLEDGEMENTS

The authors thank the Prosthodontic Department Alumni Association, Kyungpook National University, for the research grant in 2015.

## ORCID

Ming-Xu Jin <http://orcid.org/0000-0002-0744-2210>  
 Min-Ho Hong <http://orcid.org/0000-0002-6456-2200>  
 Kee-Joon Lee <http://orcid.org/0000-0002-0782-3128>  
 Kyu-Bok Lee <http://orcid.org/0000-0002-1838-7229>

## REFERENCES

1. Peumans M, Van Meerbeek B, Lambrechts P, Vanherle G. Porcelain veneers: a review of the literature. *J Dent* 2000;28:163-77.
2. Peck H, Peck S. A concept of facial esthetics. *Angle Orthod* 1970;40:284-318.

3. Ahila SC, Vaishnavi P, Muthu Kumar B. Comparative evaluation of maxillary and mandibular anterior teeth width with the length of index and little finger. *J Indian Prosthodont Soc* 2014;14:215-8.
4. Owens EG, Goodacre CJ, Loh PL, Hanke G, Okamura M, Jo KH, Muñoz CA, Naylor WP. A multicenter interracial study of facial appearance. Part 2: A comparison of intraoral parameters. *Int J Prosthodont* 2002;15:283-8.
5. Jones AR, Martin W. Comparing pink and white esthetic scores to layperson perception in the single-tooth implant patient. *Int J Oral Maxillofac Implants* 2014;29:1348-53.
6. Lombardi RE. The principles of visual perception and their clinical application to denture esthetics. *J Prosthet Dent* 1973;29:358-82.
7. Levin EI. Dental esthetics and the golden proportion. *J Prosthet Dent* 1978;40:244-52.
8. Snow SR. Esthetic smile analysis of maxillary anterior tooth width: the golden percentage. *J Esthet Dent* 1999;11:177-84.
9. Richer P. *Artistic Anatomy*. New York: Watson-Guption, 1971.
10. Preston JD. The golden proportion revisited. *J Esthet Dent* 1993;5:247-51.
11. Forster A, Velez R, Antal M, Nagy K. Width ratios in the anterior maxillary region in a Hungarian population: addition to the golden proportion debate. *J Prosthet Dent* 2013;110:211-5.
12. Kang DW, Kim DG, Kim MJ, Kim SH, Kim HS, Dong JG, Bae AR, Seu JM, Song BK, Sim JS, An SK, Yang HS, Yeo IS, Oh SC, Woo YH, Yoon GD, Yoon MJ, Lee KB, Lee KW, Lee JB, Lee JH, Lee JH, Jeong YC, Jo KH, Han JS. The principle and clinical fixed prosthodontics. DaehanNarae Publishing; Seoul; Korea, 2012. p. 32-3.
13. Zlatarić DK, Kristek E, Celebić A. Analysis of width/length ratios of normal clinical crowns of the maxillary anterior dentition: correlation between dental proportions and facial measurements. *Int J Prosthodont* 2007;20:313-5.
14. Duarte S Jr, Schnider P, Lorezon AP. The importance of width/length ratios of maxillary anterior permanent teeth in esthetic rehabilitation. *Eur J Esthet Dent* 2008;3:224-34.
15. Tsukiyama T, Marcushamer E, Griffin TJ, Arguello E, Magne P, Gallucci GO. Comparison of the anatomic crown width/length ratios of unworn and worn maxillary teeth in Asian and white subjects. *J Prosthet Dent* 2012;107:11-6.
16. Boyd JG. AACD accreditation process. *Tex Dent J* 2005;122:976-9.
17. Lee SL, Kim HJ, Son MK, Chung CH. Anthropometric analysis of maxillary anterior buccal bone of Korean adults using cone-beam CT. *J Adv Prosthodont* 2010;2:92-6.
18. Aoki H, Fukuyama T, Mita I, Ukiya M. Morphological study and comparison of the dental arch form of Japanese and American adults: a preliminary report. *Bull Tokyo Dent Coll* 1970;11:201-10.
19. Ali Fayyad M, Jamani KD, Agrabawi J. Geometric and mathematical proportions and their relations to maxillary anterior teeth. *J Contemp Dent Pract* 2006;7:62-70.
20. Hasanreisoglu U, Berksun S, Aras K, Arslan I. An analysis of maxillary anterior teeth: facial and dental proportions. *J Prosthet Dent* 2005;94:530-8.